

JOINT MEETING
of the Pathological Society of Great Britain & Ireland
and the Dutch Pathological Society (NVvP)

*Hosted by The Department of Pathology
Free University (Vrije Universiteit) Medical Centre*

Amsterdam, The Netherlands
6 – 9 July 2004



**The 186th Meeting of the Pathological Society of Great Britain & Ireland
and Joint Meeting with the Dutch Pathological Society (NVVP)**

will be held at
The Free University (Vrije Universiteit)
Main Building, De Boelelaan 1105,
1081 HV Amsterdam, The Netherlands

***There will also be a companion meeting with
the Association of Clinical Electron Microscopists***

CONTENTS

Featured Topics	3
Key Facts	4
CPD	5
General Arrangements	5
Social Activities	7
Maps	8
Future Meetings	10
Summary Programmes	11
Detailed Programmes	
Tuesday 6 July	15
Wednesday 7 July	17
Thursday 8 July	20
Friday 9 July	23
Supporting Companies	24
Abstracts	25

PROGRAMME ACKNOWLEDGEMENTS

Published jointly by
The Pathological Society of Great Britain and Ireland
and the Dutch Pathological Society (NVVP)
© 2004

COVER PHOTOGRAPH

The cover photograph is reproduced with permission

Programme is typeset in Times and ITC Stone Sans

This programme was designed, produced and printed in England by
Byte & Type Limited · Birmingham · ☎ 0121 772 3828 · ✉ info@bytetype.co.uk

FEATURED TOPICS

TUESDAY 6 JULY

Symposium: *“The expanding field of Pathology”*

Opening Ceremony

Keynote Lecture: *“HPV: implications for men, women and pathologists”*

Poster Presentations

Workshop: *“Applied Imaging International: Image analysis in modern pathology”*

Oral Communications

WEDNESDAY 7 JULY

Oral Communications

Poster Presentations

CL Oakley Lecture: *“Intestinal tumourigenesis: navigating through the β -catenin cascade”*

Pathological Society: *“Academic Pathology Forum”*

THURSDAY 8 JULY

Companion Meeting with the Association of Clinical Electron Microscopists

Mini-Symposium: *“Melanomas”*

Oral Communications

Poster Presentations

Keynote Lecture: *“Cancer as an Epigenetic Disease: Alterations in DNA Methylation and Chromatin”*

Pathological Society Annual Business Meeting

Plenary Oral Session

I Doniach Lecture: *“Stem Cells and Regenerative Medicine”*

FRIDAY 9 JULY

Mini-Symposia: (1) *“Salivary gland pathology”*

(2) *“Bone marrow pathology”*

Slide Seminar Discussion

KEY FACTS

ORAL COMMUNICATIONS

Oral communication sessions will be held as follows:

Tuesday 6 July: 15.30 – 17.30 hrs, Aula Lecture Theatre and The Auditorium

Wednesday 7 July: 09.30 – 11.45 hrs, Aula Lecture Theatre and The Auditorium
15.00 – 17.00 hrs, Aula Lecture Theatre and The Auditorium

Thursday 8 July: 09.00 – 11.30 hrs, Aula Lecture Theatre

Speakers are reminded that no communication may exceed the time allocated on the programme without the consent of the meeting, obtained through the Chairman.

PLENARY ORAL SESSION

The plenary oral session, in which the six highest-ranked submitted oral abstracts will be presented, will be held:

Thursday 8 July: 15.00 – 17.00 hrs, Aula Lecture Theatre

A prize for the best presentation, donated by the *International Journal of Experimental Pathology*, will be presented at the Society Dinner.

POSTERS/VIEWING (Corridors surrounding Aula Lecture Theatre)

Posters will be displayed throughout the Meeting. Dedicated poster sessions will be held during the following times:

Tuesday 6 July: 13.00 – 15.30 hrs

Wednesday 7 July: 13.00 – 15.00 hrs

Thursday 8 July: 13.00 – 15.00 hrs

Ideally, posters should be in place by **12 noon** on **Tuesday 6 July** and removed by **13.00 hrs** on **Friday 9 July**, i.e. posters should be on view for the whole Meeting. At least one of the contributors must be in attendance during the viewing periods, as indicated in the programme synopsis.

The Sir Alastair Currie Prize and second and third poster prizes will be presented at the Society Dinner.

SYMPOSIA

Four Symposia will be held:

Tuesday 6 July: 09.00 – 12.00 hrs, Aula Lecture Theatre

Thursday 8 July: 09.00 – 12.00 hrs, The Auditorium

Friday 9 July: 09.00 – 10.30 hrs, Aula Lecture Theatre
11.00 – 13.00 hrs, Aula Lecture Theatre

Details of topics and are listed in the programme along with chairmen (correct as at time of going to press).

COMPANION MEETING

A companion meetings with the Association of Clinical Electron Microscopists will be held:

Thursday 8 July: 09.30 – 17.00 hrs, Agora 2

SLIDE SEMINAR COMPETITION (Bone Marrow Pathology, Room 1A08)

There will be a slide competition using digital slide images, which will be available for viewing from **12.00 hrs on Tuesday 6 July until 13.00 hrs on Thursday 8 July**.

GUEST LECTURES

Tuesday 6 July: 12.15 – 13.00 hrs, Aula Lecture Theatre

A Keynote Lecture entitled: “*HPV: implications for men, women and pathologists*” will be given by Professor CJLM Meijer, Vrije Universiteit Medical Centre, Amsterdam.

Wednesday 7 July: 12.00 – 12.55 hrs, Aula Lecture Theatre

The Pathological Society of Great Britain and Ireland’s 25th CL Oakley Lecture entitled: “*Intestinal tumourigenesis: navigating through the β -catenin cascade*” will be given by Dr M Ilyas, Leeds General Infirmary.

GUEST LECTURES *continued*

Thursday 8 July: 12.00 – 12.55 hrs, Aula Lecture Theatre

A Keynote Lecture entitled: “*Cancer as an Epigenetic Disease: Alterations in DNA Methylation and Chromatin*” will be given by Professor M Esteller, Spanish National Cancer Centre, Madrid, Spain.

Thursday 8 July: 17.15 – 18.00 hrs, Aula Lecture Theatre

The Pathological Society of Great Britain & Ireland 2nd I Doniach Lecture entitled: “*Stem cells and regenerative medicine*” will be given by Professor Dame Julia Polak, Chelsea & Westminster Hospital, London.

WORKSHOP

Tuesday 6 July: 13.30 – 15.00 hrs, The Auditorium

A workshop run by Applied Imaging International, entitled: “*Image analysis in modern pathology*”.

TRADE EXHIBITION (*The Foyer*)

Delegates are encouraged to visit the Trade Exhibition and to support the companies represented there.

CONTINUING PROFESSIONAL DEVELOPMENT (CPD)

This Meeting has been approved by the Royal College of Pathologists for the purposes of Continuing Professional Development. Credits can be accrued as follows:

For each full day: 7 points

For each half day: 3 points.

Delegates who are eligible for CPD points should collect their certificates at the Registration Desk before leaving the Meeting.

This Meeting has also been approved by the **Institute of Biomedical Science** for CPD accreditation (**Code: CP030N04**).

General Arrangements

REGISTRATION

On-line registration is available via our website at: www.pathsoc.org.uk

or— the enclosed Registration Form should be completed and returned as soon as possible and in any case **before 25 June 2004**.

FEES *including all refreshments and lunch*

Before 9 June 2004

£200 for the whole meeting, or £80 per day, or part thereof.

After 9 June 2004

£300 for the whole meeting, or £100 per day or part thereof.

PhD Students, Technicians, Residents and Trainees

To qualify for this reduced fee, delegates must submit an identification document signed by the Head of Training, including National Training Numbers where applicable. If registration is submitted on-line, please send your identification document by post or via email to: julie@pathsoc.org.uk

£100 for the whole meeting, or £40 per day or part thereof.

Undergraduates, Honorary and Senior Members

£15 per day, or part thereof.

Society Dinner

£50.

FEES (continued)

A separate form should be completed for each person registering for the scientific programme. Accompanying persons or guests not registering for the scientific programme must also complete a registration form. The form may be photocopied.

Sterling cheques or international money orders for registration fees, etc. should be made payable to “*Pathological Society Meetings*”. Payment by **credit card** will also be accepted. Bookings will be acknowledged and tickets issued on arrival at the Registration Desk. **Please indicate on the registration form the names of delegates covered by the cheque / money order / credit card.**

REGISTRATION DESK (Main Building Foyer)

Registration will take place from **08.00 hrs** on **Tuesday 6 July** in the Foyer of the Vrije Universiteit, Main Building, Amsterdam.

ENQUIRIES

Enquiries before the Meeting regarding administration should be directed to:

Mrs R A Pitts

Pathological Society of Great Britain & Ireland

2 Carlton House Terrace, London, SW1Y 5AF

Tel: +44 (0)20 7976 1260

Fax: +44 (0)20 7976 1267

Email: admin@pathsoc.org.uk

or

Mr B Schot

EuroCongres Conference Management

Jan van Goyenkade 11, 1075 HP Amsterdam, The Netherlands

Tel: +31 (0)20 679 3411

Fax: +31 (0)20 673 7306

Email: schot@eurocongres.com

PRESENTATION CHECKING AND PREVIEW

This will be available in the Reception (Congresbalie).

ORAL PRESENTATIONS/LECTURES

Presenters are requested to upload their presentation at their nominated lecture theatre **at least 30 minutes before the start of the session. Please note that Apple Mac presentations are not acceptable.**

SLIDE SEMINAR

PCs for Slide Seminar Viewing will be located in Room 1A08.

MESSAGES

During the Meeting, messages for delegates may be left at the University Reception Desk on the following telephone number: +31 (0)20 444 5793. There will also be a message board located beside the Registration Desk.

REFRESHMENTS

Coffee, tea and lunch will be served in The Foyer and Restaurant.

BADGES

Delegates are requested to wear their badges at all times.

TRAVEL

By Air

From Amsterdam Schipol Airport take the train to Station Zuid/WTC (see Tram information below for onward travel to University).

TRAVEL *(continued)*

By Tram

Tram tickets will be issued to all delegates on arrival in Amsterdam. If not required delegates are requested to return their ticket to the Registration Desk.

From Central Station, Amsterdam

Express Tram No. 51 (16 minutes), Tram No. 5 (25 minutes) or Tram No. 16 (25 minutes).

From Station Zuid/WTC:

Express Tram No. 51 (1 minute, direction Poortwachter), Tram No. 5 (1 minute, direction Poortwachter)

— or a 10 minute walk from Station Zuid/WTC.

Car

The A-10 Amsterdam ring road can be reached from all directions. Follow the A-10 to the Zuid/Amstelveen exit S 108. Turn left at the end of the slip road onto Amstelveenseweg; after about 300 yards (at the VU Hospital Building) turn left again onto De Boelelaan. The University can be reached via city routes S 108 and S 109.

Parking

There is limited parking space around the University itself in De Boelelaan, which has parking bays, and also in Karel Lotsyiaan. There is paid parking on the University parking lot to the right of the Hospital Outpatient Clinic. There is also parking space on the east side of Buitenveldertselaan at the junction with Willem van Weldammelaan, within 5 minutes walking distance of the University. There are a number of reserved spaces for the disabled in front of the University Main Building and within its grounds.

ACCOMMODATION

The RAI Hotel Service is the official booking agent for the Joint Meeting of the Pathological Society of Great Britain & Ireland and the Dutch Pathological Society. There are a selection of hotels in Amsterdam from which you may obtain the best available rates. Demand for accommodation in Amsterdam is great during conferences – please make your reservation as early as possible in order to be sure of having the best possible choice from among the various hotels. For further information:

- Website/on-line booking: www.rai.nl/hotelservice
- Email to request booking form: hotelservice@rai.nl
- Fax: +31 (0)20 549 1946
- Post: RAI Hotel Service, P.O. Box 77777, 1070 MS Amsterdam

SMOKING

Smoking is prohibited at all meetings and social events except in the designated areas.

DISCLAIMER

The Pathological Society of Great Britain & Ireland and the Dutch Pathological Society cannot be held responsible for any injury or loss sustained during the Meeting.

SOCIAL ACTIVITIES

Tuesday 6 July

Welcome Reception, The Royal Tropical Institute, Amsterdam.

Hosted by the Department of Pathology, Vrije Universiteit Medical Centre, Amsterdam. Please reserve your free ticket on the Registration form.

Thursday 8 July

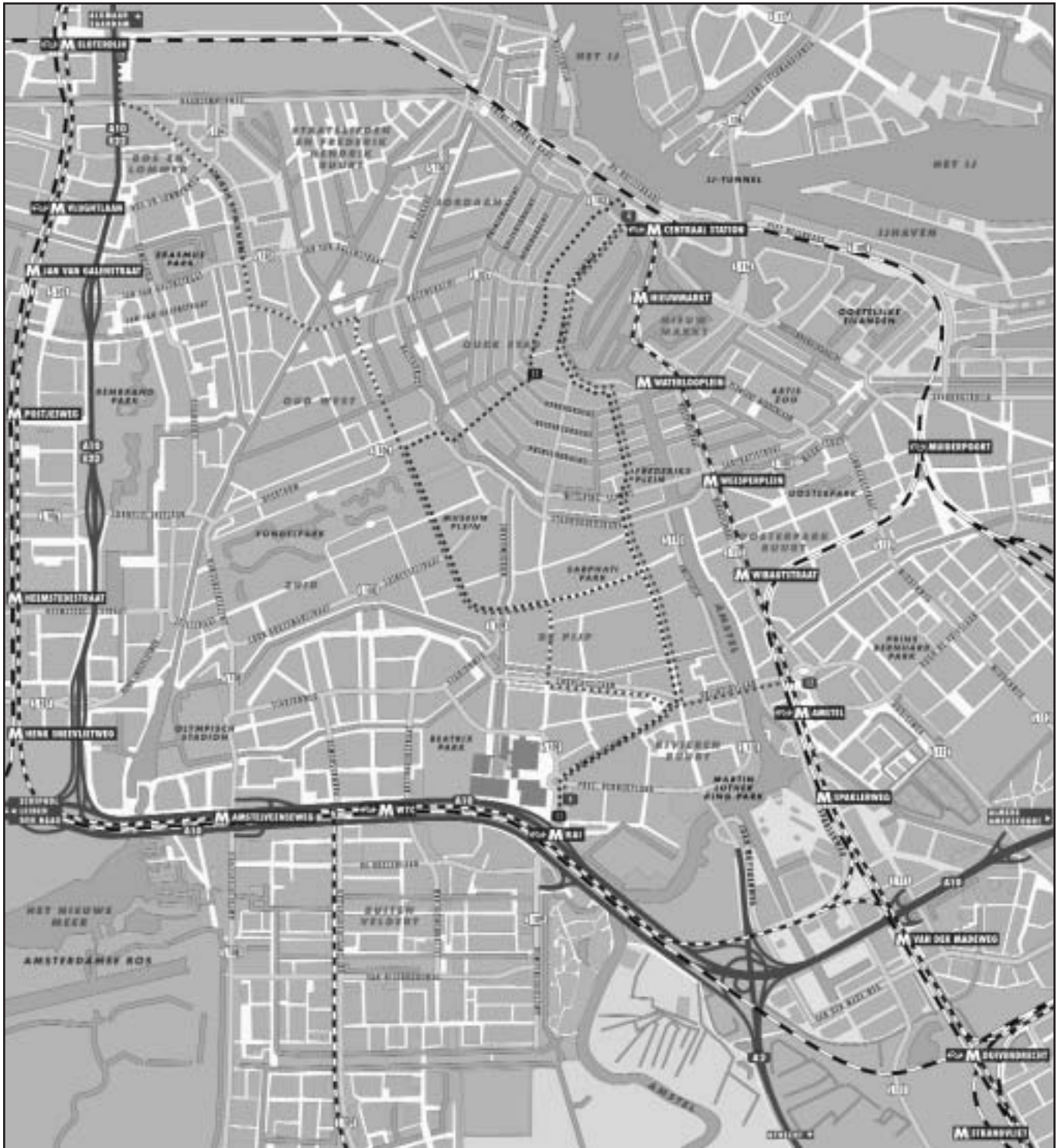Society Dinner, The Winter Garden, Krasnapolsky Hotel, Dam Square, Amsterdam.

Please reserve your ticket on the Registration Form.

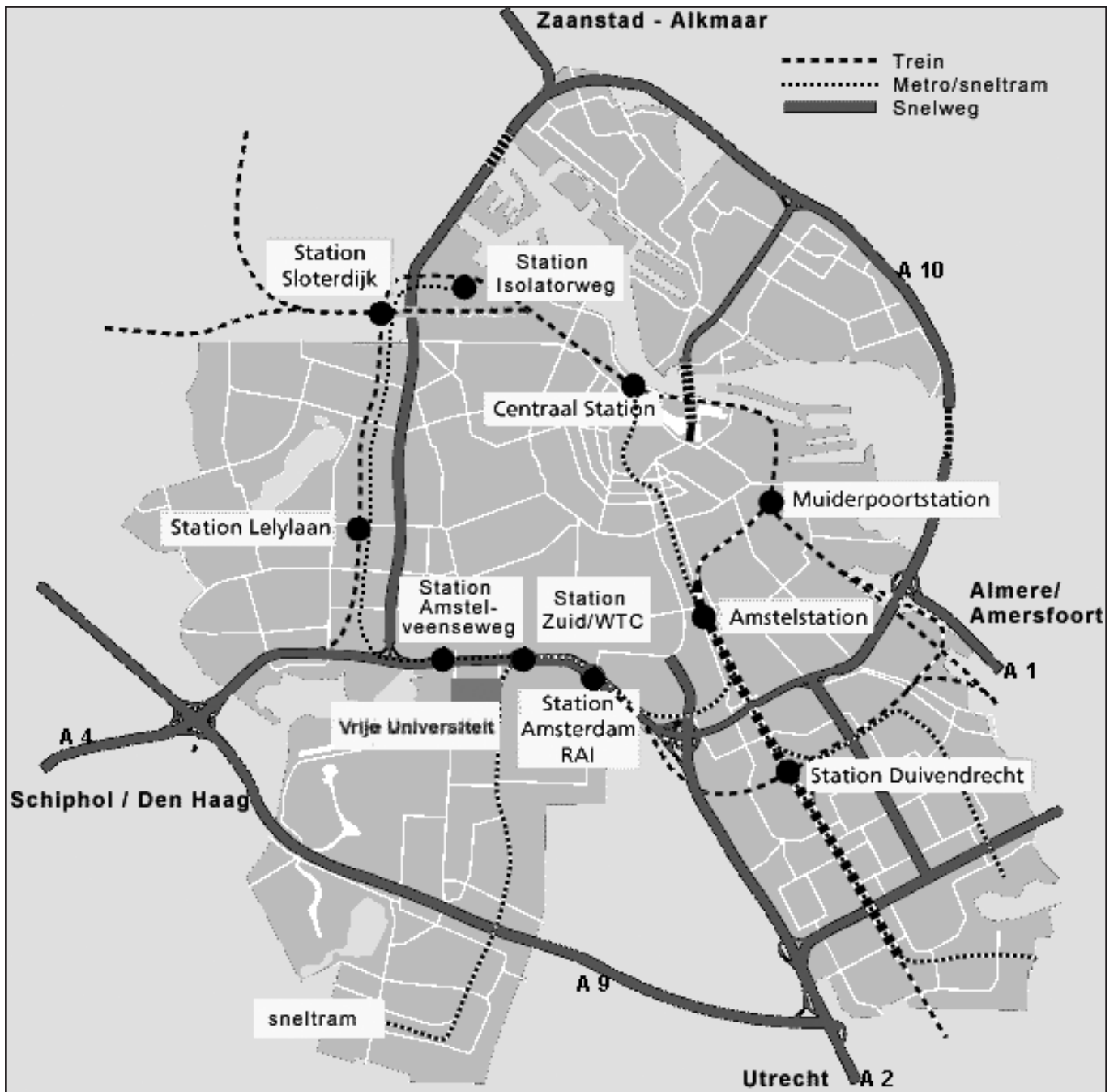
Accompanying Persons' Sightseeing Information

Please see our website for links to local places of interest.

AMSTERDAM CENTRAL AREA MAP



AMSTERDAM PUBLIC TRANSPORT MAP



Future Meetings

2005 (5 – 8 July)

Newcastle Pathology 2005 (3rd Joint Meeting of the Pathological Society of Great Britain & Ireland and the British Division of the IAP), Newcastle-upon-Tyne.

2006 (4 – 7 July)

2006 Centenary Meeting, Manchester.

2007 (3 – 6 July)

Glasgow Pathology 2007 (4th Joint Meeting of the Pathological Society of Great Britain & Ireland and the British Division of the IAP), Glasgow.

2008 (1 – 4 July)

Belfast.

Notice to Members

PROGRAMME

Members of the Pathological Society
and the Dutch Pathological Society (NVVP)
attending the Meeting
must bring this programme with them
as a limited number will be available at the Meeting.

Summary Programme – Tuesday 6 July 2004

<p>09.00 Aula Lecture Theatre SYMPOSIUM: “<i>The Expanding Field of Pathology</i>”</p>	
<p>10.15 The Foyer COFFEE</p>	
<p>12.00 Aula Lecture Theatre OPENING CEREMONY Professor E van Veen, Dean, Medical Faculty, Vrije University, Amsterdam Professor NA Wright, President, Pathological Society of Great Britian & Ireland Professor P van der Valk, President, Dutch Pathological Society (NVVP)</p>	
<p>12.15 Aula Lecture Theatre KEYNOTE LECTURE “<i>HPV: implications for men, women and pathologists</i>” Professor CJLM Meijer, Vrije Universiteit Medical Centre, Amsterdam</p>	
<p>13.00 The Restaurant / Surrounding Corridors of Aula Lecture Theatre LUNCH AND POSTER VIEWING [Abstracts 55–90]</p>	
<p>13.30 The Auditorium WORKSHOP: “<i>Image analysis in modern pathology</i>” Applied Imaging International</p>	
<p>15.30 Aula Lecture Theatre ORAL COMMUNICATIONS Gynaecological [Abstracts 1–3]</p>	<p>15.30 The Auditorium ORAL COMMUNICATIONS Breast [Abstracts 7–9]</p>
<p>16.15 The Foyer TEA</p>	
<p>16.45 Aula Lecture Theatre ORAL COMMUNICATIONS Skin [Abstracts 4–6]</p>	<p>16.45 The Auditorium ORAL COMMUNICATIONS Breast [Abstracts 10–12]</p>
<p>19.00 The Royal Tropical Institute, Amsterdam WELCOME RECEPTION</p>	

Summary Programme – Wednesday 7 July 2004

<p>09.30 Aula Lecture Theatre ORAL COMMUNICATIONS Gastrointestinal [Abstracts 13–15]</p>	<p>09.30 The Auditorium ORAL COMMUNICATIONS Genitourinary/Renal [Abstracts 20–21] Osteoarticular/Soft Tissue [Abstract 22]</p>
<p>10.15 The Foyer COFFEE</p>	
<p>10.45 Aula Lecture Theatre ORAL COMMUNICATIONS Gastrointestinal [Abstracts 16–19]</p>	<p>10.45 The Auditorium ORAL COMMUNICATIONS Autopsy and Forensic [Abstract 23] Neonatal/Paediatric [Abstract 24] Cardiovascular/Pulmonary [Abstracts 25–26]</p>
<p>12.00 Aula Lecture Theatre The Pathological Society of Great Britain & Ireland's 25TH CL OAKLEY LECTURE <i>“Intestinal Tumourigenesis: Navigating Through the β-Catenin Cascade”</i> Dr M Ilyas [Abstract 53]</p>	
<p>13.00 The Restaurant and surrounding corridors of Aula Lecture Theatre LUNCH AND POSTER VIEWING [Abstracts 91–182]</p>	
<p>13.30 The Auditorium ACADEMIC PATHOLOGY FORUM</p>	
<p>15.00 Aula Lecture Theatre ORAL COMMUNICATIONS Education and Audit [Abstracts 27–29]</p>	<p>15.00 The Auditorium ORAL COMMUNICATIONS Lymphoreticular [Abstracts 33–35]</p>
<p>15.45 The Foyer TEA</p>	
<p>16.15 Aula Lecture Theatre ORAL COMMUNICATIONS Endocrine [Abstract 30] Hepatobiliary/Pancreas [Abstracts 31–32]</p>	<p>16.15 The Auditorium ORAL COMMUNICATIONS Lymphoreticular [Abstract 36] Head and Neck [Abstracts 37–38]</p>

Summary Programme – Thursday 8 July 2004

<p>09.00 Aula Lecture Theatre ORAL COMMUNICATIONS Cellular/Molecular [Abstracts 39–43]</p>	<p>09.00 The Auditorium MINI-SYMPOSIUM Melanomas</p>
<p>09.30 Agora 2 COMPANION MEETING with the Association of Clinical Electron Microscopists</p>	
<p>10.15 The Foyer COFFEE</p>	
<p>10.45 Aula Lecture Theatre ORAL COMMUNICATIONS Experimental Tumour [Abstracts 44–45] Technical Advances [Abstract 46]</p>	<p>10.45 The Auditorium MINI-SYMPOSIUM Melanomas</p>
<p>12.00 Aula Lecture Theatre KEYNOTE LECTURE <i>“Cancer as an Epigenetic Disease: Alterations in DNA Methylation and Chromatin”</i> Professor M Esteller, National Cancer Centre, Madrid, Spain [Abstract 222]</p>	
<p>13.00 The Restaurant and surrounding corridors of Aula Lecture Theatre LUNCH AND POSTER VIEWING [Abstracts 183–211]</p>	
<p>14.00 Aula Lecture Theatre ANNUAL BUSINESS MEETING The Pathological Society of Great Britain & Ireland</p>	
<p>15.00 Aula Lecture Theatre PLENARY ORAL SESSION [Abstracts 47–49]</p>	
<p>15.45 The Foyer TEA</p>	
<p>16.15 Aula Lecture Theatre PLENARY ORAL SESSION [Abstracts 50–52]</p>	
<p>17.15 Aula Lecture Theatre The Pathological Society of Great Britain & Ireland’s 2ND I DONIACH LECTURE <i>“Stem cells and regenerative medicine”</i> Professor Dame Julia Polak [Abstract 54]</p>	
<p>19.30 The Winter Garden, Krasnopsolky Hotel, Dam Square, Amsterdam SOCIETY DINNER</p>	

Summary Programme – Friday 9 July 2004

<p>09.00 The Auditorium MINI-SYMPOSIUM Salivary Gland Pathology</p>
<p>10.30 The Foyer COFFEE</p>
<p>11.00 The Auditorium MINI-SYMPOSIUM Bone Marrow Pathology</p> <p>SLIDE SEMINAR DISCUSSION</p>
<p>13.00 The Foyer LUNCH</p>

Detailed Programme – Tuesday 6 July 2004

Presenter = © Abstract numbers are shown in bold type and in square brackets eg [259]

- 09.00 – 12.00 **Aula Lecture Theatre**
SYMPOSIUM: THE EXPANDING FIELD OF PATHOLOGY
 Chairmen: Professor PA Hall, Queen's University Belfast
 and Dr P van Diest, University Medical Centre, Utrecht
- 09.00 **Introduction**
- 09.05 **[212] Microarray for Dummies**
 Dr B Ylstra, Vrije Universiteit Medical Centre, Amsterdam.
- 09.40 **Expression Arrays**
 Professor P Quirke, University of Leeds
- 10.15 **COFFEE** (*The Foyer*)
- 10.45 **[213] Microarray based comparative genomic hybridization for genomic profiling in Pathology**
 Dr GA Meijer, Vrije Universiteit Medical Centre, Amsterdam
- 11.20 **Proteomics in Pathology**
 Professor G Smit, Vrije Universiteit Medical Centre, Amsterdam
- 12.00 – 12.15 **Aula Lecture Theatre**
OPENING CEREMONY
 Professor E van Veen, Dean, Medical Faculty, Vrije University, Amsterdam
 Professor NA Wright, President, Pathological Society of Great Britain & Ireland
 Professor P van der Valk, President, Dutch Pathological Society (NVVP)
- 12.15 – 13.00 **Aula Lecture Theatre**
KEYNOTE LECTURE
"HPV: implications for men, women and pathologists"
 Professor CJLM Meijer, Free Universiteit Medical Centre, Amsterdam
- 13.00 – 15.30 **The Restaurant and surrounding areas of Aula Lecture Theatre**
LUNCH AND POSTER VIEWING
 CATEGORY
 Breast **[55–72]**
 Gynaecological **[73–83]**
 Skin **[84–90]**
- 13.30 – 15.00 **The Auditorium**
WORKSHOP (*Programme and speakers to be announced*)
APPLIED IMAGING INTERNATIONAL: "Image analysis in modern pathology"
- 15.30 – 16.15 **Aula Lecture Theatre**
ORAL COMMUNICATIONS
 Gynaecological
 Chairman: Professor CS Herrington, University of St. Andrews, Scotland
- 15.30 **[1] Validation of Tissue Microarray Technology using Cervical Adenocarcinoma and its Precursors as a Model System**
 © MMT EL-Mansi , DJ Harrison , ARW Williams
- 15.45 **[2] BMD in hrHPV Positive Women is Age Dependent and is probably a Cytopathological Effect of a Primary HrHPV Infection**
 © NWJ Bulkman, L Rozendaal, PJF Snijders, FJ Voorhorst, AJP Boeke, GRJ Zandwijken, FJ van Kemenade, RHM Verheijen, K van Groningen, ME Boon, HJF Keuning, M van Ballegooijen, AJC van den Brule, CJLM Meijer
- 16.00 **[3] Cervical Cancer in The Netherlands 1989–1998: Decrease of Squamous Cell Carcinoma in Older Women, Increase of Adenocarcinoma in Younger Women**
 © S Bulk, O Visser, L Rozendaal, RHM Verheijen, CJLM Meijer

Detailed Programme – Tuesday 6 July 2004

Presenter = © Abstract numbers are shown in bold type and in square brackets eg [259]

- 15.30 – 16.15 **The Auditorium**
ORAL COMMUNICATIONS
 Breast
 Chairman: Dr JJ Going, Glasgow Royal Infirmary, Scotland
- 15.30 **[7] Early Dysregulation of Apoptosis- Regulating Proteins in Usual Ductal Hyperplasia with Poor Outcome**
 © AM Shaaban, C Jarvis, CS Foster
- 15.45 **[8] In Lymph Nodes Draining Human Breast Cancer, Plasmacytoid Dendritic Cells (PDC) Express TLR-9 and are a Potential Target for Immune Modulation**
 © H El-Hassi, K Cox, NM Aqel, S Islam, H Singhal, S Renton, M Burke, SC Knight
- 16.00 **[9] Stromal Contribution to Breast Cancer Cell Invasion: Intrinsic Genetic Differences Relate to Invasion Promoting Ability**
 © DL Holliday, JA Shaw, RA Walker, JL Jones
- 16.15 – 16.45 **The Foyer**
TEA
- 16.45 – 17.30 **Aula Lecture Theatre**
ORAL COMMUNICATIONS
 Skin
 Chairman: Dr EH Jaspars, Vrije Universiteit Medical Centre, Amsterdam
- 16.45 **[4] Spitz Tumours Show a Distinctive VEGF-c and Microvessel Profiles by Topographic Compartments**
 E Husain, A Blanes, L Pozo, © SJ Diaz-Cano
- 17.00 **[5] Melanoma suppressor responses induced in melanocytes by oncogenic B-FA^{E600}**
 C. Michaloglou, D.S. Peeper, © W.J. Mooi
- 17.15 **[6] Angiogenesis and Prognosis in Human Melanoma: VEGF and Microvessel Density**
 W D Thompson, © I Depasquale
- 16.45 – 17.30 **The Auditorium**
ORAL COMMUNICATIONS
 Breast
 Chairman: Dr P van Diest, University Medical Centre, Utrecht
- 16.45 **[10] Promoter Methylation in Five Members of the 3-OST Gene Family in Breast Cancer**
 © CCP Dick , JJ Going, GJR Brock
- 17.00 **[11] Analysis of the Functional Significance of Altered Tenascin Isoform Expression in Breast Cancer**
 © R A Alcock, M Adams, J H Pringle, J A Shaw, R A Walker, J L Jones
- 17.15 **[12] Molecular classification of breast carcinoma based on the protein expression immunoprofiles**
 © DM Abd El-Rehim, G Ball, S Pinder, IO Ellis
- 19.00 **The Royal Tropical Institute**
WELCOME RECEPTION

Detailed Programme – Wednesday 7 July 2004

Presenter = © Abstract numbers are shown in bold type and in square brackets eg [259]

- 09.30 – 10.15 **Aula Lecture Theatre**
ORAL COMMUNICATIONS
 Gastrointestinal
 Chairman: Professor P Quirke, University of Leeds
- 09.30 **[13] Expression of MHC Class I and II in Gastric Carcinomas N.O.S. in relation to T-Cell Infiltrate: Differences between Epstein Barr Virus Positive and Negative Tumours**
 © E. Bloemena, J. van Beek, A. Snel, W. Vos, C.J.H. van de Velde, E. Klein Kranenbarg, C.J.L. Meijer
- 09.45 **[14] Bone Marrow Cells contribute to Vascular Lineages in Colitis**
 © M Brittan, V Chance, T Hunt, RE Jeffery, G Elia, R Poulson, MR Alison, TT MacDonald, NA Wright
- 10.00 **[15] Array-CGH Demonstrates Chromosome Aberrations in both Near-Diploid and Microsatellite Unstable Colorectal Cancers**
 © G Poulgiannis, K Ichimura, NG Miller, IM Frayling, RG Morris, DJ Harrison, VP Collins, A Ibrahim, AH Wyllie, MJ Arends
- 09.30 – 10.15 **The Auditorium**
ORAL COMMUNICATIONS
 Genitourinary/Renal; Osteoarticular/Soft Tissue
 Chairman: Professor AJ Freemont, University of Manchester
- 09.30 **[20] Solid Muscle-Invasive Transitional Cell Carcinomas of the Bladder Reveal Microsatellite Instability and Somatic Down-regulation of Mismatch Repair**
 J Rubio, A Blanes, © SJ Diaz-Cano
- 09.45 **[21] Immunohistochemical Subtyping of Renal Cortical Tumours**
 © B Morgan, E Havranek, H Pandha, C Anderson, C Corbishley
- 10.00 **[22] Human Bone Marrow Stromal Cells as a Source of cells for Engineering Human Intervertebral Disc**
 S Richardson, C Le Maitre, C Kielty, © AJ Freemont, JA Hoyland
- 10.15 – 10.45 **The Foyer**
COFFEE
- 10.45 – 11.45 **Aula Lecture Theatre**
ORAL COMMUNICATIONS
 Gastrointestinal
 Chairman: Dr GA Meijer, Vrije Universiteit Medical Centre, Amsterdam
- 10.45 **[16] Abdominoperineal Resection for Rectal Carcinoma; the Pathologists' View**
 © I.D. Nagtegaal, C.J.H. van de Velde, C.A.M. Marijnen, J.H.J. van Krieken, P. Quirke
- 11.00 **[17] Expression of Epidermal Growth Factor Receptor and c-erb-B2 in Colonic Neoplasms of Familial Adenomatous Polyposis Patients – are they Therapeutic Targets?**
 © M. El-Bahrawy, D. Horncastle, N. El-Masry, I. Talbot, I. Tomlinson, R. Poulson, M. Alison
- 11.15 **[18] Tumour Suppressor Gene Methylation Status in Colorectal Adenomas: Relation to Point Gene Mutation and Chromosomal Abnormality**
 H Judson, A Stewart, A Leslie, NR Pratt, DU Baty, RJC Steele, © FA Carey
- 11.30 **[19] A Characteristic Pattern of Chromosomal Changes in Flat Adenomas and Carcinomas of the Large Intestine resembles that of a subgroup of Polypoid Colorectal Tumours**
 © C. Postma, M.A.JA Hermsen, J. Coffa, J.P.A. Baak, J.D. Mueller, E. Mueller, B. Bethke, J.P. Schouten, M. Stolte, G.A. Meijer

Detailed Programme – Wednesday 7 July 2004

Presenter = © Abstract numbers are shown in bold type and in square brackets eg [259]

- 10.45 – 11.45 **The Auditorium**
ORAL COMMUNICATIONS
 Autopsy and Forensic; Neonatal/Paediatric; Cardiovascular/Pulmonary
 Chairman: Dr J Niessen, Vrije Universiteit Medical Centre, Amsterdam
- 10.45 [23] **The value of post mortem examinations after surgery**
 © R J Delaney, P J Gallagher
- 11.00 [24] **DNA content heterogeneity in neuroblastoma by image cytometry and fluorescent in situ hybridisation and its potential significance**
 © Z Melegh, E Tóth, E Csernák, Z Szentirmay
- 11.15 [25] **Upregulation of nox2 expression in both acute and chronic hypoxia**
 © C. Meischl, P.A.J. Krijnen, S.A.G. Cillessen, R. Musters, W.S. Simonides, C.E. Hack, D. Roos, H.W.M. Niessen
- 11.30 [26] **Human Pulmonary Microvessels express Abundant Myoendothelial Gap Junctions Composed of Connexin 40**
 © M Koslowski, WR Roche, K Stuart-Smith
- 12.00 – 12.55 **Aula Lecture Theatre**
PATHOLOGICAL SOCIETY OF GREAT BRITAIN & IRELAND'S
25TH CL OAKLEY LECTURE
 [53] **Intestinal tumourigenesis; navigating through the β -catenin cascade**
 Dr M Ilyas, Leeds General Infirmary
- 13.00 – 15.00 **The Restaurant and surrounding areas of Aula Lecture Theatre**
LUNCH AND POSTER VIEWING
CATEGORY
 Autopsy and Forensic [91–94]
 Cardiovascular/Pulmonary [95–100]
 Education and Audit [101–110]
 Endocrine [111–115]
 Gastrointestinal [116–133]
 Genitourinary/Renal [134–147]
 Head and Neck [148–150]
 Hepatobiliary/Pancreas [151–157]
 Lymphoreticular [158–160]
 Neonatal/Paediatric [161–180]
 Neuropathology/Ophthalmic [181]
 Osteoarticular/Soft Tissue [182]
- 13.30 – 15.00 **The Auditorium**
ACADEMIC PATHOLOGY FORUM
 Chairman: Professor NA Wright, President, Pathological Society
 of Great Britain & Ireland
- 15.00 – 15.45 **Aula Lecture Theatre**
ORAL COMMUNICATIONS
 Education and Audit
 Chairman: Dr F van Kemenade, Vrije Universiteit Medical Centre, Amsterdam
- 15.00 [27] **Tissue Consenting for surgically removed tissue. Has performance improved one year on?**
 © J M Wheeler, M Agarwal, J Sugden, M Bladon, P Quirke
- 15.15 [28] **The Standing of UK Histopathology Research 1997–2002**
 G Lewison, K Wilcox-Jay, © NA Wright

Detailed Programme – Wednesday 7 July 2004

Presenter = © Abstract numbers are shown in bold type and in square brackets eg [259]

- 15.30 [29] **Regional Quality Control by pathologists may improve efficacy of population-based cervical screening**
© FJ van Kemenade
- 15.00 – 15.45 **The Auditorium**
ORAL COMMUNICATIONS
Lymphoreticular
Chairman: Dr J Oudejans, Vrije Universiteit Medical Centre, Amsterdam
- 15.00 [33] **The Role of Lymph Node Trucut Biopsies in Primary Diagnosis of Lymphoma: All Wales Lymphoma Panel (AWLP) Experience**
© J.L. Denson, S.D. Dojcinov, R.L. Attanoos
- 15.15 [34] **Campylobacter Jejuni is a Strong Candidate for Involvement in the Development of Immunoproliferative Small Intestinal Disease**
© TC Diss, L Baginsky, H Ye, M Du, B Wren, A Dogan, PG Isaacson
- 15.30 [35] **Evidence-Driven Microarray Data Analysis – Loss Of CD48 In Hodgkin’s Lymphoma**
© CE Hook, RNM Stitson
- 15.45 – 16.15 **The Foyer**
TEA
- 16.15 – 17.00 **Aula Lecture Theatre**
ORAL COMMUNICATIONS
Endocrine; Hepatobiliary/Pancreas
Chairman: Professor AD Burt, University of Newcastle-upon-Tyne
- 16.15 [30] **Somatic Down-regulation of Mismatch Repair Proteins Correlates with Accumulation of Microsatellite Abnormalities in Pheochromocytomas**
A Blanes, © SJ Diaz-Cano
- 16.30 [31] **The Contribution of Bone Marrow to Liver Regeneration depends upon Indigenous Hepatocyte Replication Potential**
© P Vig, F Russo, MR Alison, H Thomas, NA Wright, SJ Forbes
- 16.45 [32] **Expansion of hepatic stellate cell populations occurs in response to primary and metastatic liver tumours**
© L Zhao, AD Burt
- 16.15 – 17.00 **The Auditorium**
ORAL COMMUNICATIONS
Lymphoreticular; Head and Neck
Chairman: Dr N Rooney, Southmead Hospital, Bristol
- 16.15 [36] **Disruption of Etoposide Induced Apoptosis is Common in B-Cell Lymphomas but May Be Overcome by TRAIL/Apo2L**
SAGM Cillessen, CJLM Meijer, K Castricum, P Niesten, JJF Muris, GJ Ossenkoppele, W Vos, M Flens, © JJ Oudejans
- 16.30 [37] **Nuclear Morphometry, Immortalization, and Apoptosis in Laryngeal Cancer**
© Laila Seada, Ahmed Khafagy
- 16.45 [38] **Analysis of Head and Neck Squamous Cell Carcinoma in young patients using Microarray Comparative Genomic Hybridisation**
© EM O’Regan, P Smyth, SP Finn, S Cahill, R Flavin, C Timon, M Toner, JJ O’Leary, OM Sheils

Detailed Programme – Thursday 8 July 2004

Presenter = © Abstract numbers are shown in bold type and in square brackets eg [259]

- 09.30 – 17.00 **Room: Agora 2**
COMPANION MEETING:
THE ASSOCIATION OF CLINICAL ELECTRON MICROSCOPISTS
- 09.30 **Digital photography in diagnostic electron microscopy**
 –10.15 Mr I Clatworthy, Royal Free Medical School, London
 Chairman: Mr P Rowley, Royal Free Medical School, London
- 10.15 **COFFEE** (*The Foyer*)
 –10.45
- 11.00 **The role of electron microscopy in the diagnosis of neuromuscular disorders**
 –11.45 Professor C Sewry, Hammersmith Hospital, London
 and Orthopaedic Hospital, Oswestry
 Chairman: Dr J Moss, Charing Cross Hospital, London
- 12.00 **Short case presentations**
 –13.00 (*Various speakers and topics*)
- 13.00 **LUNCH** (*The Restaurant*)
 –14.00
- 14.05 **Tissue engineering and the myofibroblast**
 –14.50 Dr C Sarraf, University of Westminster, London
 Chaired by: Dr T Ryder, Charing Cross Hospital, London
- 15.00 **EM of a recent Norovirus epidemic in the Republic of Ireland**
 –15.45 Mr P Costigan, National Virus Reference Laboratory, University College, Dublin
 Chaired by: Dr A Curry, Manchester Royal Infirmary
- 15.45 **TEA** (*The Foyer*)
 –16.15
- 16.15 **AGM**
 –17.00 (*Open to ACEM members and non-members*)
 Chaired by: Dr T Ryder, Charing Cross Hospital, London
- 09.00 – 10.15 **Aula Lecture Theatre**
ORAL COMMUNICATIONS
 Cellular/Molecular
 Chairman: Professor CJLM Meijer, Vrije Universiteit Medical Centre, Amsterdam
- 09.00 **[39] Telomerase Transduced, Life Span Extended Human T Cells Acquire Chromosomal Aberrations and a Premalignant Genotype**
 © MWJ Schreurs, RI Klein Geltink, EWM Kueter, AATP Brink, B Carvalho, CJLM Meijer, MAJA Hermsen, GA Meijer, E Hooijberg
- 09.15 **[40] Dysregulated Expression of Sonic Hedgehog Pathway Genes in Colonic Neoplasia**
 © A. Oniscu, R.M. James, R.G. Morris, S. Bader, R.D.G. Malcomson, D.J. Harrison
- 09.30 **[41] Septin 9 interacts with cytoskeletal factors leading to altered cell migration and resistance to microtubule-disrupting drugs**
 © P A Hall, A D Chacko, S Chanduloy, S W Church, R D Kennedy, S E H Russell
- 09.45 **[42] Blottin: A Novel TFF2-Binding Protein of Foveolar Cells**
 © MD Evans, WR Otto, K Patel, I McKinnell, C-Y Lee, D Frith, S Hanrahan, N Blin, T Kayademir, R Poulsom, R Jeffery, T Hunt, NA Wright, F McGregor, K Oien

Detailed Programme – Thursday 8 July 2004

Presenter = © Abstract numbers are shown in bold type and in square brackets eg [259]

- 10.00 [43] **S100A11 Protein is Overexpressed in Common Human Cancers With Spatial Translocation From the Nucleus to Cytoplasm**
© SS Cross, FC Hamdy, JC Deloulme, I Rehman
- 10.15 – 10.45 **The Foyer**
COFFEE
- 10.45 – 11.30 **Aula Lecture Theatre**
ORAL COMMUNICATIONS
Experimental Tumour Pathology; Technical Advances
Chairman: Dr MJ Arends, Addenbrooke's Hospital, Cambridge
- 10.45 [44] **Bone Marrow contributes to Tumour Stroma**
© NC Direkze, K Hodiwala-Dilke, R Jeffery, T Hunt, D Oukrif, SL Preston, MR Alison, NA Wright
- 11.00 [45] **Dietary Fibre Accelerates Polyp Development and Proliferation in the Min Mouse**
© N Mandir, RA Goodlad
- 11.15 [46] **High Resolution Microarray-CGH Analysis Using Spotted Oligonucleotides**
© B. Carvalho, E. Ouwerkerk, G.A. Meijer, B. Ylstra
- 09.00 – 12.00 **The Auditorium**
MINI-SYMPIOSIUM: MELANOMAS
Chairman: Professor W Mooi, Vrije Universiteit Medical Centre, Amsterdam
- 09.00 [214] **Tumour-Stroma Interactions in Melanoma**
Dr L van Kempen, University Medical Centre, Nijmegen, The Netherlands
- 09.35 [215] **Evidence based dataset reporting for Melanoma**
Dr A Evans, Ninewells Hospital & Medical School, Dundee
- 10.15 **COFFEE** (*The Foyer*)
- 10.45 [216] **P16 and cell senescence: a barrier to melanoma initiation?**
Professor D Bennett, St George's Hospital & Medical School, London
- 11.20 [217] **N or M? How to handle diagnostic uncertainties**
Professor W Mooi, Vrije Universiteit Medical Centre, Amsterdam
- 12.00 – 12.55 **Aula Lecture Theatre**
KEYNOTE LECTURE
[222] **Cancer as an Epigenetic Disease: Alterations in DNA Methylation and Chromatin**
Professor M Esteller, National Cancer Centre, Madrid, Spain
- 13.00 – 15.00 **The Restaurant and surrounding areas of Aula Lecture Theatre**
LUNCH AND POSTER VIEWING
CATEGORY
Cellular/Molecular [183–207]
Technical Advances [208–211]
- 14.00 – 15.00 **The Auditorium**
ANNUAL BUSINESS MEETING
OF THE PATHOLOGICAL SOCIETY OF GREAT BRITAIN & IRELAND
(*Agenda and General Secretary's Notices despatched as separate document to Members*)

Detailed Programme – Thursday 8 July 2004

Presenter = © Abstract numbers are shown in bold type and in square brackets eg [259]

- 15.00 – 17.00 **Aula Lecture Theatre**
PLENARY ORAL SESSION
Chairmen: Professor M Pignatelli, Bristol Royal Infirmary
Professor P van der Valk, Vrije Universiteit Medical Centre, Amsterdam
- 15.00 **[47] Modes of Growth of Colorectal Adenomas (Flat and Polypoid): Evidence Against ‘Top-Down’ as a Major Method of Expansion**
© SL Preston, D Oukrif, A Kyriakides, G Elia, M Novelli, N Direkze, IC Talbot, IP Tomlinson, L Lipton, NA Wright
- 15.15 **[48] Tubular Regeneration after Folic Acid-Induced Acute Renal Failure involves proliferation of Bone Marrow-Derived Epithelium**
T-C Fang, © R Poulsom, HT Cook, MR Alison, NA Wright
- 15.30 **[49] Risk for \geq CIN3 After Five Years in HrHPV Positive and HrHPV Negative Women with Normal Cytology**
© NWJ Bulkman, L Rozendaal, PJF Snijders, CJLM Meijer
- 15.45 **TEA** (*The Foyer*)
- 16.15 **[50] Profiling of Caspase Signaling Pathways Predicts Clinical Response to Chemotherapy in Diffuse Large B-Cell Lymphomas**
JJF Muris, SAGM Cillessen, I van Houdt, W Vos, J van Krieken, NM Jiwa, GJ Ossenkoppele, PM Jansen, © CJLM Meijer, JJ Oudejans
- 16.30 **[51] Ex vivo IL-1Ra gene therapy for disc degeneration**
CL Le Maitre, NJ Rothwell, © AJ Freemont, JA Hoyland
- 16.45 **[52] Genotypic and Phenotypic Characteristics of Human Breast Carcinoma**
© E.A Rakha, J.A.L Armour, S.E Pinder, C.E Paish, I.O Ellis
- 17.15 – 18.00 **Aula Lecture Theatre**
THE PATHOLOGICAL SOCIETY OF GREAT BRITAIN & IRELAND’S
2ND I DONIACH LECTURE
[54] Stem cells and regenerative medicine
Professor Dame Julia Polak, Chelsea & Westminster Hospital, London
- 19.30 **The Winter Garden, Krasnopolsky Hotel, Dam Square, Amsterdam**
SOCIETY DINNER

Detailed Programme – Friday 9 July 2004

Presenter = © Abstract numbers are shown in bold type and in square brackets eg [259]

- 09.00 – 10.30 **The Auditorium**
MINI-SYMPOSIUM: SALIVARY GLAND PATHOLOGY
Chairman: Professor I Van der Waal, Vrije Universiteit Medical Centre, Amsterdam
- 09.00 **[218] Clinical aspects of salivary gland tumours**
Professor I Van der Waal, Vrije Universiteit Medical Centre, Amsterdam
- 09.30 **[219] The new WHO classification of salivary gland tumours**
Dr J Eveson, Bristol Dental Hospital & School
- 10.00 **[220] Fine needle aspiration of salivary gland lesions**
Professor E Bloemena, Vrije Universiteit Medical Centre, Amsterdam
- 10.30 – 11.00 **The Foyer**
COFFEE
- 11.00 – 13.00 **The Auditorium**
MINI-SYMPOSIUM: BONE MARROW PATHOLOGY
Chairman: Professor J van den Tweel, University Medical Centre, Utrecht
- 11.00 **[221] Immunohistochemistry on bone marrow biopsies. How often and what?**
Professor P van der Valk, Vrije Universiteit Medical Centre, Amsterdam
- 11.25 **[222] Secondary myelodysplasia**
Professor K Henry, Imperial College School of Medicine, London
- 11.50 **Therapy-related bone marrow pathology**
Dr J Oudejans/Dr A van de Loosdrecht: Vrije Universiteit Medical Centre, Amsterdam
- 12.15 **SLIDE SEMINAR DISCUSSION**
- 13.00 – 14.00 **The Foyer**
LUNCH

**The Pathological Society of Great Britain and Ireland
and the Dutch Pathological Society
wish to acknowledge the support of the following companies**

PARTICIPATING IN THE TRADE EXHIBITION

ADVANCED EXPERT SYSTEMS LTD

B/R INSTRUMENT CORPORATION

CYTYC UK LTD

DAKOCYTOMATION BENELUX

INFORMATIONSLOGIK AB

KLINIPATH BV

MEDICAL SOLUTIONS PLC

PAES NEDERLAND BV

VENTANA MEDICAL SYSTEMS (BELGIUM)

JOHN WILEY & SONS LTD

WISEPRESS ON-LINE BOOKSHOP

AS SPONSORS

APPLIED IMAGING INTERNATIONAL

LEICA MICROSYSTEMS BV

WESTBURG BV

(as at the time of going to press)

Abstracts

1**Validation of Tissue Microarray Technology using Cervical Adenocarcinoma and its Precursors as a Model System**© MMT EL-Mansi, DJ Harrison, ARW Williams
Edinburgh Medical school, Edinburgh, United Kingdom

The recent development of tissue microarray (TMA) technology has potentiated large-scale retrospective cohort studies using archival formalin-fixed, paraffin-embedded tissues. One obstacle to broad acceptance of TMAs is that they reduce the amount of tissue analyzed from a whole tissue section to a disk of 0.6mm diameter. In this study, we used a large series of cervical adenocarcinomas to investigate TMA technology in assessment of immunohistochemical staining. A TMA was constructed using 273 archival paraffin blocks from a series of 139 patients with 119 invasive and 20 preinvasive cervical adenocarcinomas, and 16 normal controls. Two cores were obtained from specific regions of donor blocks selected at histological review, and subsequently were arrayed into a recipient block. The novel array blocks and some whole donor blocks were sectioned and used for immunohistochemical analysis for CEA, CK7 and CK20. We compared staining in the microarray disks with the whole tissue sections. The TMA was found to yield good immunohistochemical staining which was concordant with that of the whole section from which it originated. Two TMA cores achieved representation of the whole section in immunohistochemical studies in over 95% of cases. Our results suggest that TMAs can be successfully used for immunohistochemical studies of cervical adenocarcinomas. The TMA technique is a rapid, cost effective, and tissue-saving method for high-throughput immunohistochemical studies. The areas sampled from donor blocks must be selected by careful review of sections from the original blocks, and we have shown the cores to accurately represent the morphology of the tumour in all cases. Two cores will provide representative immunohistochemical results in over 95% of cases.

3**Cervical Cancer in The Netherlands 1989-1998: Decrease of Squamous Cell Carcinoma in Older Women, Increase of Adenocarcinoma in Younger Women**© S Bulk¹, O Visser², L Rozendaal¹, RHM Verheijen¹, CJLM Meijer²
¹ VU University Medical Center, Amsterdam, Netherlands, ² Comprehensive Cancer Centre Amsterdam, Amsterdam, Netherlands

In The Netherlands, population-based screening for cervical cancer aims at women aged 30-60 years. This study determines the efficacy of screening for cervical cancer in The Netherlands, and whether the current practice to start screening at age 30 adequately prevents invasive cancer in young women. We performed a population-based study of the incidence of invasive cervical cancer. All histological diagnoses of invasive cervical cancer between 1-1-1989 and 31-12-1998 were retrieved from the Netherlands Cancer Registry. The incidence of squamous cell carcinoma (SCC) decreased from 7.1/100.000 women to 6.1/100.000 (P <0.001), while the overall incidence of adenocarcinomas remained stable. The incidence of SCC decreased most in women aged 60-74 (-4.4%). The incidence of adenocarcinoma increased in women aged 15-29 (+15.8%) and in women aged 30-44 (+2.5%). Most cases of cervical cancer, 60.5%, were detected in screened age categories. Cervical cancer in women below age 30 contributed 5.0% to the total incidence. Screening for cervical cancer in The Netherlands has been effective in reducing the incidence of SCC. Adenocarcinoma incidence seems to be increasing in younger women. These findings argue for an earlier start of cervical cancer screening to protect younger women from invasive cervical cancer as well.

2**BMD In hrHPV Positive Women Is Age Dependent And Is Probably A Cytopathological Effect Of A Primary hrHPV Infection**© NWJ Bulkman¹, L Rozendaal¹, PJF Snijders¹, FJ Voorhorst¹, AJP Boeke¹, GRJ Zandwijken¹, FJ van Kemenade¹, RHM Verheijen¹, K van Groningen², ME Boon³, HJF Keuning⁴, M van Ballegooijen⁵, AJC van den Brule¹, CJLM Meijer¹
¹ VU University Medical Centre, Amsterdam, Netherlands, ² Spaarneziekenhuis, Heemstede, Netherlands, ³ Leiden Cytology and Pathology Laboratory, Leiden, Netherlands, ⁴ Stichting PA Laboratorium Kenemmerland, Haarlem, Netherlands, ⁵ Erasmus Medical Centre, Rotterdam, Netherlands

POBASCAM is a population-based randomised-controlled trial to implement hrHPV-testing in cervical screening, comparing hrHPV-testing & cytology with cytology & hrHPV-blinded. Here, we present the baseline data. Between January 1999 and September 2002, 44,102 women, mean age 42.8 years, were included. The presence of hrHPV was age-dependent, decreasing from 12.0% at 29-33 years to 2.4% at 59-61 years. In the intervention group the distribution of cytology hrHPV by cytology class was normal cytology 96.6% (3.6% hrHPV-positive), borderline and mild dyskaryosis (BMD) 2.5% (34.6% hrHPV-positive), and moderate dyskaryosis or worse (>BMD) 0.8% (88.3% hrHPV-positive). In the control group, 96.5% normal cytology, 2.4% BMD and 0.8% >BMD. When stratified to hrHPV-status, in hrHPV-negative women the prevalence of BMD or >BMD were low and independent of age. In hrHPV-positive women, the prevalence of >BMD (13.7%) was also independent of age, i.e., women with an hrHPV-infection have a flat risk of having severe cervical lesions. In contrast, in women with a positive hrHPV-test the prevalence of BMD was age-dependent, (p for trend <0.01, 20.2% in women 29-33 years to 7.8% in women 54-58 years). These results strongly suggest that the majority of BMD in hrHPV-positive women reflect a cytopathological effect of a primary hrHPV-infection.

4**Spitz Tumours Show a Distinctive VEGF-c and Microvessel Profiles by Topographic Compartments**E Husain¹, A Blanes², L Pozo³, © SJ Diaz-Cano⁴
¹ Barts and The London NHS Trust, London, United Kingdom, ² University of Malaga School of Medicine, Malaga, Spain, ³ Homerton University Hospital, London, United Kingdom, ⁴ King's College Hospital, London, United Kingdom

The bases of the cell kinetics and microvessel profiles in Spitz tumors (ST) are poorly understood. No study has correlated cell kinetics, microvessel profile, and VEGF-c expression by topographic compartments in ST to date.

We selected ST (42), malignant melanomas (42, 15 radial growth phase MM-RGP and 27 vertical growth phase MM-VGP), and conventional melanocytic nevi (15 junctional, 20 compound), the latter two groups used as controls. Immunostaining for Ki-67 and VEGF-c, and in situ end labeling (ISEL) of DNA fragments (using Klenow fragment of DNA polymerase I) were scored by topographic compartments: junctional, superficial dermal (above 0.76 mm) and deep dermal (below 0.76 mm), screening the whole compartment in each case. Appropriate controls were run in each sample. CD-31-stained slides were used to estimate microvessel density. The results were statistically compared using analysis of variance and Student *t*-test, and considered significant if P<0.05.

Superficial-to-deep gradient was maintained for Ki-67 in all lesions, but was significantly higher in MM. From junctional to deep dermal compartments, ST showed a progressive and statistically significant increase of ISEL indices (4.38%, 4.73%, 8.35%) and microvessel density (4.38, 4.39, 7.41 vessels/HPF). VEGF-c expression by compartments appears in the Table.

	Junctional	Sup Dermis	Deep Dermis
Junctional Nevi	14.92	--	--
Compound Nevi	9.25	2.38	1.47
MM-RGP	30.68	14.05	19.25
MM-VGP	58.93	32.53	33
ST	54.34	46.65	49.45

The local VEGF-c expression in ST is directly correlated with the microvessel density and apoptosis index and inversely with the proliferation index, suggesting that this distinctive blood vessel pattern is reactive to regressive cellular changes.

Melanoma suppressor responses induced in melanocytes by oncogenic B-RAF^{E600}

C. Michaloglou², D.S. Peepers², © W.J. Mooi¹

¹ Vrije University medical centre, Amsterdam, Netherlands, ² Netherlands Cancer Institute, Amsterdam, Netherlands

Oncogenic B-RAF^{E600} or RAS^{V12} mutants have been identified in the large majority of melanocytic naevi, probably contributing to an initial phase of growth. However, there is subsequent growth arrest and induction of the tumour suppressor p16^{INK4a}. Interestingly, INK4a is frequently inactivated in melanoma. We hypothesized that the proliferative arrest of naevi reflects a senescence-type of response, similar to that observed by others and ourselves in vitro after the introduction of oncogenic RAS^{V12} into non-neoplastic cells, and may act as a tumour-suppressing mechanism in vivo.

We have identified immunohistochemical positivity for p16^{INK4a} in several hundreds of naevi. The percentage of p16^{INK4a}-positive naevus cells within naevi varied widely; positive and negative cells were indistinguishable, and often mixed in an haphazard fashion. Normal cutaneous melanocytes were generally p16^{INK4a}-negative.

Twenty naevi were stained for senescence-associated acidic β -galactosidase activity. They were usually, but not quite always, unequivocally positive. The staining contrasted with negativity of normal melanocytes and other cells of the same specimen.

In vitro, human primary fibroblasts (BJ, IMR90) acutely underwent proliferative arrest upon B-RAF^{E600} expression. They showed β -galactosidase activity and the occurrence of a characteristic senescent 'flat-cell phenotype', as well as accumulation of 'senescence-associated heterochromatin foci' (SAHF's). Western blotting showed a sharp increase in p16^{INK4a} levels upon B-RAF^{E600} expression.

Together, the data indicate that B-RAF^{E600} may induce a senescence-type of response in nonneoplastic cells.

Early Dysregulation of Apoptosis-Regulating Proteins in Usual Ductal Hyperplasia with Poor Outcome

© AM SHAABAN, C JARVIS, CS FOSTER

¹ St. James's Hospital, Leeds, United Kingdom, ² University of Liverpool, Liverpool, United Kingdom

Background: Members of the bcl-2 family are key regulators of apoptosis. Bcl-2 blocks apoptosis whereas Bax promotes apoptotic cell death. Their precise role in mammary carcinogenesis remains poorly understood. Since balance between pre-apoptotic and anti-apoptotic stimuli determines fate of cells, the relative expression of bcl-2 and bax would define the phenotypic behaviour of mammary epithelial cells.

Design: A case-control study was designed on 674 benign breast biopsy specimens received in three institutions in the period between 1979 and 1999. Study cases included all patients with benign breast lesions followed by in situ or invasive cancer of either breast at least 6 months after the benign lesion. Each study case was age and date of biopsy matched with three controls that had histories of benign breast lesions but did not develop breast cancer. Foci of hyperplasia of usual type (HUT) and adjacent morphologically normal lobules were identified from cases and controls and stained with monoclonal antibodies for bcl-2 and Bax.

Results: A total of 103 hyperplastic foci from 40 patients were available for analysis. The median percentage of bcl-2 expression in HUT foci from patients who progressed to breast carcinoma was 50 whereas that of controls was 17.5, $P < 0.001$. A trend towards higher bcl-2 expression in normal lobules from patient who progressed to breast cancer was seen. Bax was highly expressed in normal lobules from controls when compared with cases ($P = 0.008$). Although the percentage of positive cells in HUT foci from cases was higher than controls (32.5 vs 17.5), this difference was not statistically significant. Using multiple logistic regression analysis, the correct classification rate of bcl-2 and Bax in classifying cases and controls was 70.2%.

Conclusions: Our data show, for the first time, an early dysregulation of the levels of apoptosis-regulating proteins in normal and non-atypical hyperplastic foci of patients who progressed to breast cancer. A high ratio of bcl-2:Bax in normal breast and HUT might help identify patients at high-risk of developing breast carcinoma.

Angiogenesis and Prognosis in Human Melanoma: VEGF and Microvessel Density

W D Thompson², © I Depasquale¹

¹ Department of Plastic Surgery, Aberdeen Royal Infirmary, Aberdeen, United Kingdom, ² Department of Pathology, Aberdeen Royal Infirmary, Aberdeen, United Kingdom

204 cases of melanoma from Grampian over four years were studied for prognostic indicators. Immunohistochemistry was used to assess microvessel density (MVD), and expression of vascular endothelial growth factor (VEGF). Breslow thickness correlated significantly ($p < 0.001$) with both ulceration and risk of recurrence.

MVD estimation was performed using the Chalkley technique on sections stained using CD31 antibody. This was measured at the tumour edge of all specimens, and in the tumour centre for specimens with a Breslow thickness > 3 mm. The most significant correlations of MVD with Breslow thickness, ulceration and recurrence were obtained from the edge. Chalkley MVD is superior to Breslow for recurrence for tumours > 2 mm thick, but remains a time-consuming research technique. An immunostaining approach like oestrogen receptor assessment would find more general acceptance.

Staining intensity of VEGF correlates significantly with Breslow, Clark, ulceration and MVD, but not for metastatic recurrence. It appears paradoxical that VEGF expression is not more predictive of recurrence, but even low expression may be sufficient for tumour angiogenesis, and other factors must govern tumour aggression. Antagonism of VEGF may still prove a successful adjunct in future therapeutic trials.

In Lymph Nodes Draining Human Breast Cancer, Plasmacytoid Dendritic Cells (PDC) Express TLR-9 and are a Potential Target For Immune Modulation

© H El-Hassi¹, K Cox¹, NM Aqel², S Islam¹, H Singhal², S Renton², M Burke², SC Knight¹

¹ Imperial College, London, United Kingdom, ² Northwick Park Hospital, London, United Kingdom

Introduction. Dendritic cells (DC) are potent antigen presenting cells that stimulate naïve T-cells. They recognise pathogen-associated molecular patterns through toll-like receptors (TLR) and can induce both T-helper type (Th) 1 and Th2 responses. PDC are a distinct subset characterised by high expression of the interleukin (IL)-3 receptor α chain (CD123). PDC recognise unmethylated CpG motifs in microbial DNA through TLR-9, secrete interferon (IFN)- α and trigger Th1 responses. In cancer, PDC are present in peri-tumoural areas and tumour draining lymph nodes (LN). Stimulation of PDC with CpG motifs may have a role in tumour immunotherapy. Therefore, we analysed TLR9 expression by PDC in breast cancer draining lymph nodes.

Materials and Methods. Cell suspensions were prepared from fresh breast cancer draining axillary LN ($n=2$) and control inguinal LN ($n=2$). Lymph node PDC were magnetically enriched using anti-CD123 microbeads, centrifuged onto glass slides and labelled with fluorescein isothiocyanate (FITC) conjugated anti-TLR-9.

Results. In both tumour draining and control LN, PDC were found to express TLR-9. Expression of TLR9 was localised both to the surface membrane and intracellular compartments of PDC.

Discussion. Therapeutic activation of TLR-9⁺ PDC with unmethylated CpG DNA motifs may upregulate pro-inflammatory cytokines and polarise strong anti-tumour Th1 responses in the tumour microenvironment. This study highlights the role of PDC as potential targets for immuno-modulation in human cancer.

Stromal Contribution to Breast Cancer Cell Invasion: Intrinsic Genetic Differences Relate to Invasion Promoting Ability

© DL Holliday¹, JA Shaw¹, RA Walker¹, JL Jones²

¹ Breast Cancer Research Unit, Department of Cancer Studies and Molecular Medicine, University of Leicester, Leicester, United Kingdom, ² Tumour Biology Group, Cancer Research UK Clinical Centre, John Vane Science Centre, London, United Kingdom

The stromal component is recognised to contribute to tumour invasion at least in part via release of MMPs. Tumour-associated fibroblasts differ from normal fibroblasts but it is not clear to what extent these differences are intrinsic to the patient or acquired.

This study used matched breast and dermal fibroblasts isolated from normal donors and patients with breast cancer to investigate intrinsic versus acquired ability to promote tumour invasion between these 2 groups. Fibroblasts were classified as having high or low invasion promoting capacity (IPC) and then related to MMP polymorphism status for MMP-1, -3 and -9. Both breast and dermal fibroblasts from tumour patients exhibited higher intrinsic IPC than normal fibroblasts, although dermal fibroblasts did not cross-talk with breast cancer cells.

A higher frequency of the MMP-3 5A allele, which results in enhanced gene expression, was detected in the tumour patient group and correlated with high IPC fibroblasts. Interestingly, the low expresser MMP-1 1G allele also related to high IPC fibroblasts.

In conclusion this study demonstrates intrinsic genetic differences in patients with breast cancer versus normal donors, and this correlates with enhanced capacity of fibroblasts to promote invasion. Wider analysis of such functional polymorphisms may identify at risk patient groups.

Analysis of the Functional Significance of Altered Tenascin Isoform Expression in Breast Cancer

© R A Alcock, M Adams, J H Pringle, J A Shaw, R A Walker, J L Jones

University of Leicester, Leicester, United Kingdom

We have identified two apparently tumour-specific Tenascin (TN) isoforms in breast tissue, in addition to truncated TN (tTN) one containing exon 16 (TN16) and the other containing exons 14 and 16 (TN14/16).

The aim of the study was to investigate the ability of these isoforms to promote tumour progression. To do this, a PCR approach was used to generate isoform sequences (tTN, TN16, TN14/16 and the full length sequence LTN for comparison), which were over expressed in breast cancer cell lines and primary breast fibroblasts

Over expression in TN-null tumour cells (MCF7 and T47D) resulted in a significant increase in invasion with TN14/16 and to a lesser extent TN16. All isoforms caused increased tumour cell proliferation and also increased tumour cell expression of MMP-1. Co-culture of MCF7 cells with primary fibroblasts transfected with different isoforms exhibited the highest level of invasion in the presence of TN14/16 expressing cells ($p=0.013$), though all transfected fibroblasts displayed equivalent enhanced MMP-1 expression.

These results indicate that TN can affect tumour cell behaviour both directly, and indirectly by influencing fibroblast activity. The potent invasion-promoting effect of the TN14/16 isoform suggests distinct functional domains within the alternatively spliced region, which could provide tumour-specific targets for therapy.

Promoter Methylation in Five Members of the 3-OST Gene Family in Breast Cancer

© CCP Dick, JJ Going, GJR Brock

University of Glasgow, Glasgow, United Kingdom

Aberrant methylation of the promoter regions known as CpG islands is documented in many human cancers, often with down-regulation of the associated gene. We report promoter methylation status for five members of the heparan sulphate *D*-glucosaminyl 3-*O*-sulphotransferase (3-OST) gene family. These genes encode enzymes which perform post-translational modification of cell-surface heparan-sulphate proteoglycans (HSPGs). Members of this family have different substrate specificities; each modifies the 3-*O* position of glucosamine on a heparan-sulphate glycosaminoglycan (HSGAG) side chain. Such modifications alter the affinity of HSPGs for external stimuli such as growth factors. Aberrant methylation was first shown in two members of the family (3-OST1 & 3-OST3B). Subsequently, methylation of the promoter of 3OST2 was also reported in breast cancer. Promoter methylation and down-regulation of both 3OST2 and 3OST3B have been shown. In this study we examined methylation at these three loci and two paralogues, 3-OST3A and 3-OST4, in 69 primary breast carcinomas. Methylation was frequent in the promoters of 3-OST2 (51%, 40/69), 3-OST3B (41%, 28/69), and 3-OST4, (45%, 32/69). but rare for 3OST-1 (1%, 1/69) and never detected in 3OST3A. High levels of methylation in specific OST family genes suggests a significant role in breast carcinogenesis, which expression studies may elucidate.

Molecular classification of breast carcinoma based on the protein expression immunoprofiles

© DM Abd El-Rehim, G Ball, S Pinder, IO Ellis

¹ Hitopathology Department, University of Nottingham, Nottingham, United Kingdom, ² Department of Life sciences, Nottingham Trent University, Nottingham, United Kingdom

The development of Tissue Microarray [TMA] technology provides high throughput concomitant analyses of several proteins on a large number of tumors. Our aim was to examine the protein expression profiles of a large unselected series of breast cancers using TMA to determine the range of molecular diversity and presence and frequency of distinct and clinically relevant patterns which could improve our understanding of the molecular diversity of breast cancer and which may have a role in augmenting and improving the current classification systems.

Using immunohistochemistry, we studied the combined protein expression profiles of 1076 cases of invasive breast cancer using a large panel of well-characterized biomarkers. On the basis of these expression profiles, tumors were then stratified using hierarchical clustering and artificial neural network algorithms into 6 groups.

Two broadly similar luminal and hormone receptor positive groups were identified. A third c-erbB-2 driven group with altered E-cadherin expression and muc1 over-expression. The fourth group is not considered due to limited number of cases. The fifth was p53 driven / basal positive group and finally the sixth group showed broad similarity to the third one except for weak muc1 expression and strong E-cadherin expression. Significant differences were observed in relation to outcome with the poorest outcome observed in the p53/ basal group.

Our data imply that distinct types of breast cancer with biological and clinical relevance exist. Our overall results support the feasibility of improvement of classification of breast cancer based on morphological and protein expression characteristics.

Expression Of MHC Class I And II In Gastric Carcinomas N.O.S. In Relation To T-Cell Infiltrate: Differences Between Epstein Barr Virus Positive And Negative Tumours

© E. Bloemena¹, J. van Beek¹, A. Snel¹, W. Vos¹, C.J.H. van de Velde², E. Klein Kranenbarg², C.J.L. Meijer¹

¹ Dept of Pathology, VU University Medical Centre, Amsterdam, Netherlands, ² Dept of Surgery, Leiden University Medical Centre, Leiden, Netherlands

Epstein Barr Virus (EBV) is associated with several benign and malignant diseases, amongst which gastric adenocarcinomas (GCs). We have previously demonstrated, in a large Dutch cohort of GCs, collected between 1989 and 1993 in the course of a large randomised multicenter surgical study (D1D2), that the incidence of EBV-positive GCs was 7.2% (41 of 566 patients). Remarkably, EBV-associated tumours had a significantly lower frequency of lymph node metastases (63.4% N0) compared to EBV-negative tumours (38.7% N0) ($P=0.034$). In the present study we investigated whether the lower frequency of lymph node metastases could be attributed to differences in expression of MHC molecules and/or T cell infiltrate between EBV-positive and negative tumours, reflecting possible immune stimulation by the presence of foreign, virus related antigens. Formalin-fixed, paraffin embedded material of primary tumours (EBV+:n=20; EBV-: n=28) were stained with the antibodies HCA2, HC10 (MHC I), beta-2-microglobulin (MHCI), LN3 (MHCI), CD3 (pan T), CD4, CD8, and granzymB7. Results were scored semi-quantitatively.

EBV-associated GCs were significantly more often positive for MHC cl II (EBVpos= 12/20 vs EBVneg=8/28) ($P=0.029$), had a more extensive T cell infiltrate ($P=0.0001$), with a higher relative contribution of CD8+ cells ($P=0.022$) of which a higher percentage displayed an activated (granzymB positive) phenotype ($P=0.028$). These results demonstrate that in EBV bearing gastric carcinomas, in contrast to EBV negative tumours, a cytotoxic immune response is found, presumably directed against EBV related antigens on the neoplastic cells.

Array-CGH Demonstrates Chromosome Aberrations In Both Near-Diploid And Microsatellite Unstable Colorectal Cancers

© G Pouligiannis¹, K Ichimura¹, NG Miller¹, IM Frayling², RG Morris³, DJ Harrison³, VP Collins¹, A Ibrahim¹, AH Wyllie¹, MJ Arends¹

¹ Department of Pathology, University of Cambridge, Cambridge, United Kingdom, ² Institute of Medical Genetics, University Hospital of Wales, Cardiff, United Kingdom, ³ Pathology, School of Molecular and Clinical Medicine, University of Edinburgh, Edinburgh, United Kingdom

Previous analyses of colorectal cancer have shown at least two patterns of genomic abnormality with differing prognoses. Those with chromosomal instability, identifiable as aneuploidy, and those with microsatellite instability (usually near-diploid), which show inactivation of the DNA mismatch repair (MMR) system. Recently, a third category of colorectal cancers has emerged that are microsatellite stable and near-diploid. To further define these categories we applied array-based comparative genomic hybridisation (array-CGH) to examples of each, preselected from a series of 80 left-sided colorectal adenocarcinomas. Aneuploid tumours were distinguished from near-diploid by flow cytometric assessment of DNA index. MMR status was determined by hMLH1 & hMSH2 immunohistochemistry and microsatellite stability (MSS) or instability (MSI) at 10 microsatellite loci. We found that 26 of these tumours (32.5%) were near-diploid (single modal DNA index between 0.8 and 1.2) and MSS, whilst 38 (47.5%) were aneuploid and MSS, 10 (12.5%) were aneuploid and MSI+ and 6 (7.5%) were near-diploid and MSI+. Array-CGH revealed the presence of DNA copy number changes in all tumour categories, but there were two striking findings. First, several tumours in the near-diploid & MSS group showed the same pattern of common changes as has already been described in the aneuploid & MSS group (7+, 8p-, 8q+, 13+, 17p-, 18q-, 20+), but without the many other "background" chromosome imbalances. Second, near-diploid tumours, whether MSS or MSI+, often showed small regions of amplification or deletion. We conclude that genome-wide high resolution array-based analyses of colorectal cancers reveal a much more complex, but informative picture of genomic alterations in colorectal cancer.

Bone Marrow Cells Contribute To Vascular Lineages In Colitis

© M Brittan¹, V Chance², T Hunt¹, RE Jeffery¹, G Elia¹, R Poulosom¹, MR Alison³, TT MacDonald², NA Wright⁴
¹ Histopathology Unit, Cancer Research UK, London, United Kingdom, ² Division of Infection, Inflammation and Repair, University of Southampton, Southampton, United Kingdom, ³ Dept. Histopathology, Imperial College, London, United Kingdom, ⁴ Dept. Histopathology, Bart's and The London Hospitals, London, United Kingdom

Introduction: We report blood vessels containing bone marrow (BM)-derived smooth muscle (SM) cells and endothelial cells in the inflamed mouse colon, highlighting the role of BM in vasculogenesis in tissue regeneration. Methods: Lethally-irradiated female mice were rescued by a BM transplant from male donors. Colitis was induced by intrarectal injection of trinitrobenzene sulphonic acid (TNBS) 6 weeks post-transplant, and colons were analysed 1-14 days post-TNBS. In situ hybridisation for Y chromosome was combined with immunohistochemistry for specific antigens e.g., alpha smooth muscle actin [SMA], ICAM-1, PECAM-1, and F4/80, to identify transplanted cells and determine their phenotype. Results: Many venules and arterioles, delineated by morphological criteria, were identified in inflamed colons, and contained vascular SM and endothelial cells that displayed a Y chromosome and were thus derived from the transplanted BM. Vessels were observed, albeit rarely, that were composed entirely of cells of BM origin, indicative of neovasculogenesis by BM. Vascular SM lining cells were immunoreactive for SMA, and endothelial cells expressed ICAM-1 and PECAM-1 antigens. Importantly, cells were present in vessels that were BM-derived, but did not express the mouse macrophage marker, F4/80. In ethanol-treated control colons, BM contributed to 4.2% of vascular SM cells, which increased significantly to 26.8% in colitis. Conclusions: We believe this is the first report of BM regulation of vasculogenesis in colitis. It is possible that BM cells engraft within existing venules and promote regeneration by angiogenesis, or alternatively, that BM cells form entire new venules by neovasculogenesis. This demonstrates the importance of BM in tissue repair in diseases such as colitis.

Abdominoperineal Resection For Rectal Carcinoma; The Pathologists' View

© I.D. Nagtegaal¹, C.J.H. van de Velde², C.A.M. Marijnen², J.H.J. van Krieken¹, P. Quirke³

¹ UMC St Radboud, Nijmegen, Netherlands, ² LUMC, Leiden, Netherlands, ³ Academic Unit of Pathology, Leeds, United Kingdom

Abdominoperineal resection (APR) is in general indicated for low rectal cancer (i.e. located less than 5 cm from the anal verge). Although in recent years the prognosis of rectal carcinoma patients in general has been greatly improved, results for lower rectal cancer are still disappointing. Moreover, the application of pre-operative short-term radiotherapy in this group of tumours, has no significant effect on prognosis.

We studied a trial population of rectal cancer patients (n = 1530), in which 455 patients (29.7%) were operated upon using a Total Mesorectal Excision in combination with an APR. Half of the patients were irradiated (preoperative 5 x 5 Gy). Outcome measures were both prognosis and quality of surgery. Quality of surgery was measured indirectly, by using circumferential margin involvement, and directly using photographs of the specimen. The mesorectum was graded as previously described, and for the grading of the anal canal a new system has been developed; which has been applied by two pathologists.

In the APR group more CRM were positive compared to low anterior patients (28.8% versus 13.5%, $p < 0.001$). When prognosis was corrected for margin status, no differences were observed in the CRM negative group, but in the CRM positive group prognosis of APR patients was still worse (30.7% vs. 17.7%). The high number of positive margins in the APR group are at least partly caused by the incomplete resection (i.e. perforation or missing areas of the muscularis propria): 40-48%. The scoring of the quality of surgery in the anal canal did not show any independent prognostic value, but this evaluation identifies a major cause of local recurrence that may be avoided by wider excision or chemoradiotherapy.

Expression Of Epidermal Growth Factor Receptor And c-erb-B2 In Colonic Neoplasms of Familial Adenomatous Polyposis Patients - Are They Therapeutic Targets?

© M. El-Bahrawy¹, D. Horncastle¹, N. El-Masry², I. Talbot³, I. Tomlinson⁴, R. Poulson⁴, M. Alison¹

¹ Hammersmith Hospital, London, United Kingdom, ² Charing Cross Hospital, London, United Kingdom, ³ St. Mark's Hospital, London, United Kingdom, ⁴ Cancer Research UK, London, United Kingdom

The expression of epidermal growth factor receptor (EGFR) and c-erb-B2 are reported to be poor prognostic factors in sporadic colorectal carcinoma, and there are currently clinical trials targeting EGFR.

The aim of this study was to investigate the expression of EGFR and c-erb-B2 in normal mucosa, adenomas and carcinomas from familial adenomatous polyposis coli (FAP) patients, to explore the role of EGFR in the adenoma-carcinoma sequence.

The expression of EGFR and c-erb-B2 was studied by immunohistochemistry in normal mucosa, adenomas and carcinomas from 15 FAP patients. 165 adenomas and 15 carcinomas with the adjacent non-neoplastic mucosa were studied.

The non-neoplastic mucosa showed cytoplasmic expression and weak membranous expression of EGFR in the basolateral aspects of the cell. Of the adenomas, 64% showed weak cytoplasmic staining, 18% showed cytoplasmic and membranous staining and 18% were negative. In adenocarcinomas 47% showed cytoplasmic staining, 7% showed cytoplasmic and membranous staining, while 47% were negative.

In terms of c-erb-B2, weak cytoplasmic expression was seen focally in the surface epithelium of the non-neoplastic mucosa and of 17% of adenomas while all carcinomas were negative.

This is the first study investigating the expression of these two receptors in both adenomas and carcinomas from FAP patients. The study shows that c-erb-B2 is not upregulated in tumours of FAP patients, while EGFR appears to be upregulated in a considerable percentage of both adenomas and carcinomas. We conclude that EGFR, but not c-erb-B2, may be a target for therapeutic intervention in FAP patients.

A Characteristic Pattern Of Chromosomal Changes In Flat Adenomas And Carcinomas Of The Large Intestine Resembles That Of A Subgroup Of Polypoid Colorectal Tumours

© C. Postma¹, M.A.JA Hermsen¹, J. Coffa¹, J.P.A. Baak¹, J.D. Mueller², E. Mueller², B. Bethke³, J.P. Schouten⁴, M. Stolte³, G.A. Meijer¹

¹ Department of Pathology, VU Medical Center, Amsterdam, Netherlands, ² Department of Pathology, Baystate Medical Center, Springfield, United States, ³ Institute of Pathology, Klinikum Bayreuth, Bayreuth, Germany, ⁴ MRC Holland, Amsterdam, United Kingdom

Colorectal flat adenomas, compared with polypoid adenomas of similar size, show more frequently high-grade dysplasia and rapid submucosal invasion. This study aimed to analyse whether flat adenomas differ in their pattern of chromosomal aberrations from their polypoid counterparts.

Six flat adenomas and 12 flat carcinomas were analysed by array-CGH and the pattern of chromosomal aberrations was compared to those earlier obtained in a series of polypoid tumours (112 adenomas; 82 carcinomas). MLPA (on 20q genes) was done on 14 flat and 15 polypoid tumours.

With CGH, flat adenomas showed on average 1.8 gains (range 1-4) and 3.2 losses (range 0-4), and the flat carcinomas 4.5 gains (range 0-8) and 3.5 losses (range 1-6). In both adenomas and carcinomas a high frequency of 20q gain (83% and 92%, respectively) and 18q loss (83% and 92%, respectively) were found, as observed before in a subgroup of polypoid colorectal tumours.

By MLPA, BCL2L1, E2F1, TOP1 and ZNF217 genes had copy number ratios of 2.0 or higher, both in flat and polypoid tumours with 20q gains.

Flat adenomas and carcinomas of colon harbour a similar pattern of chromosomal aberrations as a specific subgroup of polypoid lesions, with 18q loss and 20q gain.

Tumour Suppressor Gene Methylation Status in Colorectal Adenomas: Relation to Point Gene Mutation and Chromosomal Abnormality

H Judson, A Stewart, A Leslie, NR Pratt, DU Baty, RJC Steele, © FA Carey

University of Dundee, Dundee, United Kingdom

Epigenetic mechanisms in carcinogenesis may have a significant role in development of colorectal cancer. To investigate this phenomenon in early-stage disease promoter methylation status in the tumour suppressor genes APC, MGMT, h-MLH1, p14 and p16 was investigated in 78 colorectal adenomas which had previously been characterised for mutations of APC, K-ras and p53 genes and for chromosomal abnormality by comparative genomic hybridisation (CGH). APC hypermethylation was seen in 51 tumours (65.4%). APC showed either methylation or mutation in 65 lesions (83.3%). MGMT methylation was detected in 38 cases (48.7%). Adenomas with this abnormality showed a significantly lower number of chromosomal changes by CGH ($p < 0.02$), confirming that DNA repair defect of this type is not associated with chromosomal instability.

MLH1 methylation defect was seen in only one adenoma (1.3%), from a patient who had a synchronous cancer showing the same defect. p14 methylation was seen in 31 adenomas (39.7%) and p16 abnormality in 25 (32.1%). DNA methylation at 2 or more loci was seen in 45 tumours (58%) while 11 lesions (14.1%) showed no evidence of hypermethylation at any of the loci studied. There was no association between particular chromosomal abnormalities, APC, K-ras or p53 mutation and any pattern of methylation abnormality.

We conclude that methylation abnormality is very common in pre-invasive colorectal neoplasia. Apart from the association between MGMT methylation and low number of chromosomal abnormality there would appear to be no systematic link between hypermethylation and common genetic changes.

Solid Muscle-Invasive Transitional Cell Carcinomas of the Bladder Reveal Microsatellite Instability and Somatic Down-regulation of Mismatch Repair

J Rubio¹, A Blanes¹, © SJ Diaz-Cano²

¹ University of Malaga School of Medicine, Malaga, Spain, ² King's College Hospital, London, United Kingdom

Histologic patterns have been demonstrated prognostically useful in transitional cell carcinomas (TCC) of the bladder, but no information is available on the prognostic significance and genetic profile of muscle-invasive TCC by infiltration patterns.

The predominant infiltration pattern of 72 muscle-invasive TCC was assessed in the deep compartment and classified as 'solid' (diffuse infiltration effacing the muscle fibers, 45 cases) or 'single-file' (tumor infiltration dissecting the muscle and inducing a dense stromal reaction, 27 cases). Tumors were studied by compartments (superficial and deep to muscularis mucosa), DNA being extracted from both compartments to analyze the microsatellite pattern of *TP53*, *RBI*, *WT1*, and *NFI* by PCR/denaturing gradient gel electrophoresis. Mitotic index, Ki-67 index, in situ end labeling, and DNA ploidy analysis were evaluated in the same areas. Statistical differences were tested using ANOVA and Fisher's exact test. Mismatch repair was assessed by MLH1 and MSH2 sequencing and immunostaining in TCC with ≥ 2 abnormal microsatellite loci.

The genetic profile was demonstrated significantly different for *RBI* ($p=0.0003$) and *NFI* ($p=0.0023$) only. Single-file TCC showed a low incidence of genetic deletion/SNP(s), not involving *RBI* locus, and very occasionally *NFI* locus (2 cases, 13%). Single-file TCC showed lower cell turnover (Ki-67 index 14.94 ± 4.28 , ISEL 14.1 ± 10.0), lower incidence of aneuploid DNA content, and shorter mean survival (20 months) than solid TCC (Ki-67 index 20.65 ± 4.94 , ISEL 20.2 ± 22.7 , 37-month survival, respectively). No mutations were identified in MLH1 or MSH2 genes, along with a significant decrease of their protein expression in TCC with solid growth pattern.

In conclusion, solid muscle-invasive TCC are characterized by high cellular turnover and microsatellite deletion/SNP(s) in *RBI* and *NFI*, through a somatic down-regulation of mismatch repair proteins. This microsatellite instability profile in solid TCC correlates with longer survival.

Immunohistochemical Subtyping Of Renal Cortical Tumours

© B Morgan , E Havranek , H Pandha , C Anderson , C Corbishley
St George's Healthcare NHS Trust, London, United Kingdom

Introduction: The Heidelberg classification of renal cortical tumours is widely accepted but clear distinctions between tumour types may be difficult on light microscopy. A panel of Immunohistochemical markers for distinguishing subtypes was assessed.

Method: 163 renal cortical tumours were stained for cytokeratins 7 and 20, CD 117 (CKIT) and vimentin. Cases were reviewed and subclassified into clear cell, mixed, chromophobe, chromophil (papillary), oncocytoma and unclassifiable. Immunohistochemical staining was assessed blind and correlated with grade and tumour type.

Results: 11/36 (30.6%) of chromophobe tumours stained with CD117 compared with other subtypes; Clear cell 4/81 positive (4.9%), Chromophil 1/29 positive (3.4%).

Vimentin was positive in all renal cell carcinomas (144/157, 91.7%) but negative in oncocytomas (0/8).

CK7 was positive in a higher proportion of chromophil tumours than other subtypes and negative in all oncocytomas. CK20 showed no significant discriminatory staining.

Conclusion: CK 7 helps in distinguishing chromophil tumours from other types but this distinction is readily possible on microscopy in the majority of cases.

Vimentin and CK7 is useful in distinguishing oncocytomas

CD117 expression is increased in chromophobe tumours- in keeping with molecular studies of KIT gene over-expression. CD117 is useful in subtyping chromophobe tumours, which may influence treatment.

Human Bone Marrow Stromal Cells as a Source of cells for Engineering Human Intervertebral Disc

S Richardson¹, C Le Maitre¹, C Kielty², © AJ Freemont¹, JA Hoyland¹

¹ *Spinal Research Group, UK Centre for Tissue Engineering, University of Manchester, Manchester, United Kingdom,* ² *UK Centre for Tissue Engineering, Manchester, United Kingdom*

INTRODUCTION: Intervertebral disc (IVD) degeneration occurs in over 40% of the adult population and involves loss of discal extracellular matrix leading to instability and pain. Autologous cells are the ideal choice for bioengineering a new disc, but removal of cells from the IVD is not practical as it promotes degeneration. The aim of this study was to examine whether mesenchymal stromal cells (MSCs) could be differentiated into disc cells.

METHODS: MSCs maintained in monolayer culture or alginate beads were studied for expression of markers of a nucleus pulposus cell phenotype (type II collagen, aggrecan, Sox-9) and *in situ* hybridisation (ISH) for SOX-9 mRNA. Both systems were also treated with cytokines (NP-induction medium [NPIM]) and/or transfected with a SOX-9 adenovirus (pAdloxFLSOX9; MOI=200) and/or seeded onto PLLA scaffolds.

RESULTS: Culture in alginate, TGF beta treatment, transfection with Sox-9 and seeding onto PLLA all led to increased production of RNA and/or protein for type II collagen, aggrecan and Sox-9. Certain combinations were synergistic.

DISCUSSION & CONCLUSIONS: Adult human MSCs can be induced, *in vitro*, to form cells with the phenotype of cells in the nucleus pulposus of the intervertebral disc by altering their internal and external chemical and external physical environments. Combinations of these techniques might allow production of cells suitable for tissue engineering purposes.

The value of post mortem examinations after surgery

© R J Delaney , P J Gallagher
Department of Pathology, Southampton University Hospitals, Southampton, United Kingdom

At present 24% of all deaths in England are followed by post mortem examination. The majority of these are sudden unexpected deaths but a significant proportion is in patients dying after surgery. In order to determine the value of these autopsies we made a retrospective audit of patients within 30 days of surgery in 2002. Our particular objective was to analyse the discrepancies between pre mortem diagnoses and post mortem findings.

The medical records and post mortem reports of 92 adults who died within 30 days of an operative procedure and underwent post mortem examination were reviewed. Major/minor clinical diagnoses were categorised by the Goldman method and compared with the post mortem findings to determine the discrepancy rate. Patients were grouped according to surgical speciality and type of operative procedure.

There was complete agreement in pre and post mortem diagnosis in 60 (65%) patients. 18 (20%) patients had discrepancies classified as major and 14 (15%) as minor. This varied between surgical specialities – cardiothoracic 5.6% major discrepancies, general surgery 26.9%, trauma and orthopaedics 35% and neurosurgery 33%. Of the major discrepancies 39% were infectious processes, 22% thromboembolic and 22% ischaemic in nature. The time from surgery to death did not appear to affect the likelihood of discrepancies occurring.

The rate of discrepancies is comparable to previous studies of similar populations in both England and North America. It is likely that the overall number of post mortems performed in England will be reduced in the near future. Our results suggest that this reduction should not apply to postoperative cases.

DNA content heterogeneity in neuroblastoma by image cytometry and fluorescent in situ hybridisation and its potential significance

© Z Melegh , E Tóth , E Csernák , Z Szentirmay
National Institute of Oncology, Budapest, Hungary

The aim of this study was to determine the frequency and significance of the tumour DNA content heterogeneity in 33 previously untreated human neuroblastomas. We used image cytometry to selectively analyse neuroblasts by excluding karyorrhectic or stromal cells from cytometric measurements.

MYCN gene amplification was determined by quantitative real-time PCR using FRET probes. DNA content heterogeneity with more than one tumour cell line on DNA histogram was found in 8 out of 33 cases. Four out of these eight cases showed MYCN amplification. Double labelling fluorescent *in situ* hybridisation (FISH) with probes for the centromeric region of chromosome 2 and MYCN gene confirmed the DNA content heterogeneity. Furthermore, the FISH analysis of the 4 heterogeneous MYCN amplified tumour revealed that each tumour cell population contained MYCN amplification. On the other hand, DNA content heterogeneity was associated with poorer prognosis in this study ($P < 0.05$). There was a significant correlation between euploidy (di- and tetraploidy) and worse prognosis, but only when heterogeneous neuroblastomas with euploid cell population were assigned to euploid tumours ($P = 0.006$). Our results may explain the conflicting data in the literature regarding ploidy and suggest that DNA content heterogeneity and the presence of a euploid population may predict worse prognosis in neuroblastoma patients.

Upregulation of nox2 expression in both acute and chronic hypoxia

© C. Meischl¹, P.A.J. Krijnen¹, S.A.G. Cillessen¹, R. Musters², W.S. Simonides², C.E. Hack³, D. Roos³, H.W.M. Niessen¹
¹ VU University Medical Center Department of Pathology, Amsterdam, Netherlands, ² VU University Medical Center Department of Physiology, Amsterdam, Netherlands, ³ Sanquin Research at CLB, and Landsteiner Laboratory, Academic Medical Centre, Amsterdam, Netherlands

NADPH oxidase-generated reactive oxygen species have been shown to play an important role in the pathophysiology of the heart in general. We previously have shown in human autopsy material that nox2 is upregulated following acute myocardial infarction.

We have now extended these findings to different in vitro and in vivo models of ischemia. In H9c2 cells, a rat cardiomyocyte-derived cell line, we observed upregulation of nox2 expression after 1-2 hours of metabolically induced ischemia, which was further increased after subsequent reperfusion. This upregulation colocalized with a concomitantly increased generation of reactive oxygen species. Furthermore, in an in vivo rat model of chronic hypoxia, we also observed a markedly increased expression of nox2 in cardiomyocytes. These data show that upregulation of nox2 is induced in cardiomyocytes by ischemia and/or reperfusion, both in acute and chronic alterations. Our present efforts are directed at elucidating the cell-biological consequences of the observed upregulation of the NADPH oxidase and the increased generation of reactive oxygen species.

Tissue Consenting For Surgically Removed Tissue. Has Performance Improved One Year On?

© J M Wheeler¹, M Agarwal¹, J Sugden¹, M Bladon¹, P Quirke²

¹ Leeds Teaching Hospitals NHS Trust, Leeds, United Kingdom, ² LTH NHS Trust & Academic Unit of Pathology, Leeds University, Leeds, United Kingdom

The Human Tissue Act suggests that surgically removed tissue requires consent for research. In Autumn 2002 we incorporated a section regarding use of tissue into the standard national surgical consent form. A total of 5840 consent forms were audited from Oct/Nov 2002 & Oct/Nov 2003. Initially the audits looked at the number of histology requests accompanied by consent forms. This had increased from 51% to 70% after one year. Few other changes occurred over this period. In 2003, 56% (55% - 2002) had completed the tissue section, 34% (36% - 2002) were blank and 10% (9% - 2002) were partially completed. Rejection rate for public health monitoring improved, falling from 10% to 4%. Rejection rates for the use of tissue for future diagnosis remained the same at 4% and for teaching/research remained at 5%. One consultant achieved a 100% rejection rate on all sections.

Conclusions: Receipt of consent forms has increased to 70% but only 56% of forms received were properly filled in. A lack of improvement in completing the tissue section, plus anomalies in the rejection rate indicates a significant need for education and training of clinicians, if this method is to be used routinely by the NHS.

Human Pulmonary Microvessels Express Abundant Myoendothelial Gap Junctions Composed Of Connexin 40

© M Koslowski¹, WR Roche¹, K Stuart-Smith²

¹ Department of Cellular Pathology, Southampton General Hospital, Southampton, United Kingdom, ² Department of Anaesthesia, Glan Clwyd Hospital, Rhyl, United Kingdom

Endothelium-derived Hyperpolarizing Factor (EDHF), generated by the endothelium of small blood vessels, initiates relaxation of the underlying smooth muscle. Direct contact between endothelial and smooth muscle cells in the form of gap junctions may be necessary for the EDHF-signal transfer. The present study used electron microscopy and immunohistochemistry to demonstrate direct myoendothelial contacts in human pulmonary microvessels. Electron microscopy demonstrated close membrane appositions between endothelial and smooth muscle cells with focal membrane fusion. All appositions were formed by membrane projections from smooth muscle cells through the internal elastic lamina. To determine whether these appositions contained gap junctions, immunohistochemistry was carried out for connexins 37, 40 and 43, the gap junction proteins commonly found in blood vessels. Connexin 37 was occasionally present in endothelial cells. Connexin 43 was absent. By contrast, connexin 40 was found abundantly on the abluminal side of endothelial cells and in the adjacent smooth muscle cells, implicating the presence of myoendothelial gap junctions. These results demonstrate for the first time that electron microscopic evidence of myoendothelial gap junctions can be correlated with immunohistochemical evidence of such junctions in blood vessels. Such structures may provide a pathway for the EDHF-signal transfer from the endothelium to the smooth muscle.

The Standing of UK Histopathology Research 1997-2002

G Lewison¹, K Wilcox-Jay¹, © NA Wright²

¹ City University, London, United Kingdom, ² Histopathology Unit, Cancer Research (UK), London, United Kingdom

INTRODUCTION: We have attempted a quantitative bibliometric assessment of the UK's research in histopathology. METHODS: histopathology and its subject areas were defined by means of 'filters' based on specialist journals and title words; the filters were developed by specialist histopathologists. The 'basic' or 'clinical nature of each publication was assessed and a measurement made of its 'potential impact category' (PIC). The results were compared both within the UK and relative to 11 OECD countries. RESULTS: Worldwide histopathology output has remained static, compare with a steady growth in biomedicine, with the UK's contribution at 10% below its average presence. Neuropathology, genetics and cardiovascular pathology emerged as the largest output, and ophthalmic pathology the smallest. Output volume in breast, gynaecological and osteoarticular and soft tissue pathology was strong, but hepatopathology was very weak. Genetic research proved most basic and cytopathology most clinical, and the bias of all UK research was more clinical than the other countries. UK papers had a PIC higher than the world average, although behind the USA, Netherlands, Switzerland and Canada. Only 59% of papers acknowledged funding source, with more basic papers acknowledging support than clinical papers and charitable funding was more prominent than government research council funding. In the UK the leading centres were London (WC 11.3%, W 8.3% SE 7.7% and SW 5.9%), Oxford 8% and Manchester 6%; in addition all these centres published more in histopathology than biomedicine overall. However, centres such as Cambridge, Aberdeen, Glasgow and Edinburgh were less committed to histopathology, with only Dundee in Scotland having a higher presence (3.1 v. 2.1%). A postal survey of 150 histopathology researchers revealed a good correlation between mean relative esteem value (REV) and journal citation scores ($r^2 = 0.60$). The UK appeared at the lower middle rank of REV, below USA, Switzerland and Canada, but above Spain and Sweden.

CONCLUSIONS: The data do provide data on the quantity of output, with insights into quality within methodological constraints.

Regional Quality Control by pathologists may improve efficacy of population-based cervical screening.

© FJ van Kemenade

Vrije Universiteit Med Centre, Amsterdam, Netherlands

Nationwide cervical screening program in the Netherlands was restructured in 1996 with introduction of an adjusted classification scheme (CISOE-A*) and institution of Regional Quality Pathologists (RQP). RQP were to collect follow-up data, monitor CISOE-score profiles, to facilitate education and to assess quality in the laboratory procedures. So far, it is unclear as to whether introduction of RQP's has increased overall laboratory effectiveness in cervical screening.

Here we show data from 14 laboratories in the greater Amsterdam Area (150000 women yearly invited) over 4 consecutive years: we measured histological follow-up profiles, detection rates of precursors lesions, percentage of compliance with recommended test turn-around times (TAT) and gauged feasibility of audits.

Fourteen regional laboratories delivered data with histology follow up percentages (of referral- and repeat smears) of 75%, 81% and 97% over a three year period, confirming CIN in 58%, 65% and 79% of these cases.

Recommended TATs were complied with in 94%, 79% and 79%. Laboratories were audited four times each to verify procedure adherence and to verify benchmarks.

In conclusion: RQP can contribute to quality control and enhance uniformity in laboratory procedures among 14 different laboratories in one region.

The Contribution of Bone Marrow to Liver Regeneration Depends Upon Indigenous Hepatocyte Replication Potential

© P Vig¹, F Russo², MR Alison², H Thomas², NA Wright¹, SJ Forbes²

¹ *Cancer Research Uk, London, United Kingdom*, ² *Imperial College, London, United Kingdom*

INTRODUCTION: The magnitude of bone marrow cell (BMC) contribution to liver damage is highly variable. We examined if regeneration is enhanced by inhibiting indigenous hepatocyte proliferation in a murine model of hepatitis B (HBs-tg). **METHODS:** HBs-tg female mice received lethal irradiation and bone marrow transplant (BMT) from C57Bl/6J males. Six weeks later half the mice were treated with retrorsine to block regeneration of indigenous hepatocytes. Mice were sacrificed at 3 and 6 months following BMT. Y chromosome-positive hepatocytes were identified by *in-situ* hybridisation (ISH), combined with phenotypic cell markers (i.e hepatocyte, oval cell and proliferation markers). **RESULTS:** In retrorsine-treated mice 4.7% and 1.6% of oof hepatocytes were Y chromosome+ at 3 and 6 months respectively after transplant, compared with 0.37% and 0.33% in the control groups. 2.59% and 0.63% of hepatitis B surface antigen-positive hepatocytes were Y chromosome-positive at 3 months and 6 months respectively, thus suggesting that fusion is occurring in this model. At 6 months we observed nodules composed of small hepatocyte-like cells progenitor cells (SHPCs) surrounded by larger and presumably older hepatocytes. Some of these nodules expressed HBsAg while others did not. However, all of the nodules expressed albumin, AFP and Ki67. **CONCLUSIONS:** BMCs contribute to the regeneration of the chronically damaged liver particularly under conditions where indigenous hepatocyte replication is blocked. It appears that both transdifferentiation and fusion occur in this model. Proliferation of SHPCs appearing at 6 months may compromise bone marrow cell engraftment in the HBs-tg mouse.

Somatic Down-regulation of Mismatch Repair Proteins Correlates with Accumulation of Microsatellite Abnormalities in Pheochromocytomas

A Blanes¹, © SJ Diaz-Cano²

¹ *University of Malaga School of Medicine, Malaga, Spain*, ² *King's College Hospital, London, United Kingdom*

Adrenal pheochromocytomas have been extensively studied at the molecular level, but no information is available on the molecular profile by topographic compartments of malignant and locally invasive pheochromocytomas (PCC).

Microdissected samples from the peripheral and internal zones of 143 pheochromocytomas (95 sporadic, 48 associated to MEN-2A) were selected for loss of heterozygosity (LOH) and single nucleotide polymorphism (SNP) analyses. Five polymorphic DNA regions from *TP53*, *RB1*, *WT1*, and *NF1* were systematically studied by polymerase chain reaction-denaturing gradient gel electrophoresis. Pheochromocytomas were classified malignant (16 sporadic tumors with distant metastases), locally invasive (30 sporadic tumors showing retroperitoneal infiltration only), and benign (all remaining tumors). Statistical differences were evaluated using Fisher's exact test. Mismatch repair was assessed by MLH1 and MSH2 sequencing and immunostaining in PCC with ≥ 2 abnormal microsatellite loci.

LOH/SNP involved *TP53* in 40/134 informative cases (29.9%), *RB1* in 22/106 informative cases (20.8%), *WT1* in 32/120 informative cases (26.7%), and *NF1* in 32/80 informative cases (40.0%). More genetic abnormalities involving the peripheral compartment were revealed in 34 pheochromocytomas (23.8%): 12/16 malignant, 10/30 locally invasive, and 12/97 benign. Multiple and coexistent genetic abnormalities characterized malignant PCC ($P < 0.001$), whereas locally invasive PCC showed significantly higher incidence of *NF1* alterations ($P < 0.001$). No mutations were identified in MLH1 or MSH2 genes, along with a significant decrease of their protein expression in peripheral compartments.

Only the accumulation of microsatellite lesions and intratumor heterogeneity characterizes malignant PCC, suggesting a multistep tumorigenesis for these neoplasms, through a somatic topographic down-regulation of mismatch repair proteins. In contrast, locally invasive PCC frequently reveals single locus alterations, especially involving *NF1*.

Expansion of hepatic stellate cell populations occurs in response to primary and metastatic liver tumours

© L Zhao, AD Burt

School of Clinical and Laboratory Sciences, University of Newcastle upon Tyne, Newcastle upon Tyne, United Kingdom

Some primary liver tumours and many intrahepatic metastatic deposits show a marked host desmoplastic response. While this may be beneficial, the host response may paradoxically favour tumour growth. The cellular origin of peritumoral matrix remains uncertain. The aim of this project was to study the density and distribution of hepatic stellate cells (HSC) in this response in an animal model of hepatocarcinogenesis and in human disease.

Dysplasia and hepatocellular carcinoma was induced in rats given diethylnitrosamine (DEN). Liver tissue was obtained at 10, 16 and 19 weeks. HSCs were identified by immunohistochemistry using antibodies to α smooth muscle actin, desmin, glial fibrillary acidic protein (GFAP) and KLF6. Immunoreactive cells were assessed as numbers per unit area (0.044mm²); densities at the different time points were compared. HSCs were also localised in explant and resection specimens from patients with hepatocellular carcinoma and with metastatic colonic carcinoma.

HSCs were seen around dysplastic areas in the livers of animals at week 16 post DEN and around/within carcinomas at week 19. The numbers of α -SMA-positive HSC per 0.044mm² at weeks 10, 16, and 19 were 2.7 \pm 3.4, 3.2 \pm 2.1, and 5.8 \pm 5.2 (random counts); 4.7 \pm 4.6, 6.4 \pm 3.3, and 19.7 \pm 16.4 (periportal counts). Increased numbers of HSCs were observed in human livers with primary or metastatic malignancies although the cellular densities were variable.

HSC populations thus expand during the process of hepatocarcinogenesis and as part of a host response to metastasis; interactions between this population and dysplastic/malignant cells may be important in determining tumour growth characteristics.

The Role of Lymph Node Trucut Biopsies in Primary Diagnosis of Lymphoma: All Wales Lymphoma Panel (AWLP) Experience

© J.L. Denson, S.D. Dojcinov, R.L. Attanoos
 Department of Pathology, Cardiff and Vale NHS Trust, Cardiff, United Kingdom

Background: Accurate lymphoma diagnosis is central to the optimal clinical management. The advocated method for primary lymphoma diagnosis is the excisional biopsy. The aim of this study was to evaluate the diagnostic utility and limitations of lymph node trucut biopsies. Methods & Results: Over a 6 year period all lymph node trucut biopsies submitted for primary lymphoma diagnosis to the AWLP were evaluated. On morphology with Immunohistochemistry the study cases were divided into groups of Definitive (DefDx); Indefinite (IndefDx); and Inadequate (InadDx) for diagnosis. In limited cases additional clonality studies, flow cytometry and molecular cytogenetic studies were available. Over the study period, the AWLP had received 192 trucut biopsies. Lymph node trucuts comprised 39% (n=76). DefDx was attained in 71%, IndefDx in 20% and InadDx in 9%. In 5/76 (7%) cases initial trucut biopsy yielded an incorrect diagnosis when correlated with excisional biopsy. Non – DefDx resulted from focal nodal disease, necrosis, small sample size with inadequacy for ancillary testing. In a limited series, flow cytometry conferred advantages over PCR clonality studies in providing contributory information. Conclusions: Definitive lymphoma diagnosis can be attained by trucut biopsy. With the increased use of specialized ancillary studies, particularly flow cytometry, trucut biopsies may play an increasingly important role in primary lymphoma diagnosis in poorly accessible sites and in evaluation of relapses. Application of these diagnostic modalities requires more extensive sampling and necessitates new operational protocols. However, it confers a lower diagnostic accuracy and higher error rate than excisional biopsy. Despite lower patient morbidity, clinicians should be dissuaded from performing trucuts for primary lymphoma diagnosis.

Evidence-Driven Microarray Data Analysis - Loss Of CD48 In Hodgkin's Lymphoma

© CE Hook, RNM Stitson
 Histopathology Department, Leicester Royal Infirmary, Leicester, United Kingdom

Introduction: Immunocompromised patients often develop EBV-driven B-cell malignancies, including Hodgkin's lymphomas. Common to many primary and acquired immunodeficiency states are defects in cell-mediated cytotoxicity. We hypothesised that in immunocompetent individuals, Hodgkin's cells might evade immune surveillance via reduced expression of co-receptors crucial to NK and CTL function, such as CD48, which is involved in EBV-targeted NK cytotoxicity.

Results: We analysed Affymetrix microarray datasets and found that compared to normal B-cell subsets and other B-cell lymphomas, Hodgkin's cell lines (KMH2, L1236, L428 & HDLM2) show significantly reduced expression of CD48 mRNA. This has been confirmed at the protein level and further experimental work is underway to elucidate the role of CD48 in lymphomagenesis.

Conclusion: Whilst microarray analysis has proven to be useful in identifying gene expression signatures or prognostic tumour subgroups, the huge amount of data generated and statistical approaches to data-mining have tended to concentrate on identifying genes specifically expressed or absent in particular tumours compared to controls or normal counterparts. However, this often overlooks genes that are variably expressed across normal subsets but may nevertheless play important roles in pathogenesis. We have shown that analysing the data using an evidence- and hypothesis-driven approach can also yield potentially important results.

Campylobacter Jejuni is a Strong Candidate for Involvement in the Development of Immunoproliferative Small Intestinal Disease

© TC Diss¹, L Baginsky¹, H Ye², M Du², B Wren³, A Dogan¹, PG Isaacson¹
¹ Histopathology Department, RF & UCL Medical School, London, United Kingdom, ² Division of Molecular Histopathology, University of Cambridge, Cambridge, United Kingdom, ³ Pathogen Molecular Biology Unit, London School of Hygiene and Tropical Medicine, London, United Kingdom

Immunoproliferative small intestinal disease (IPSID) is a MALT lymphoma that produces a characteristic truncated immunoglobulin α -heavy chain. Bacterial involvement is suspected in this disease, as some tumours resolve after antibiotic treatment and other MALT lymphomas have proven associations with infectious agents. A recent report implicated *Campylobacter jejuni* in the development of IPSID. We have used PCR and sequencing of 16S rDNA sequences (16S rDNA) to search for *C. jejuni* in paraffin sections of IPSID and other gastro-intestinal samples (12 Crohns disease, 13 coeliac disease, 5 EATL and 61 others). In positive cases the cytolethal distending toxin gene (Cdt) was amplified to investigate the role of this cellular toxicity gene. *C. jejuni* 16S rDNA was amplified from 11/20 IPSID samples and from 4/91 others. The positive non-IPSID samples were 3 small intestinal samples (one DLBCL) and a duodenal biopsy from a coeliac patient. Cdt PCR was negative in all 11 *C. jejuni* positive IPSID samples. These data confirm an association between IPSID and *C. jejuni* and support the hypothesis that *C. jejuni* is a causative agent of IPSID. Failure to amplify the Cdt gene may indicate a selection process for Cdt negative organisms.

Disruption of Etoposide Induced Apoptosis is Common in B-Cell Lymphomas but May Be Overcome by TRAIL/Apo2L

SAGM Cillessen, CJLM Meijer, K Castricum, P Niesten, JJF Muris, GJ Ossenkoppele, W Vos, M Flens, © JJ Oudejans
 VUmc, Amsterdam, Netherlands

Inhibition of the apoptosis cascade is a probable cause for chemotherapy resistance in lymphomas, for which treatment with TRAIL/Apo2L might be an alternative. We investigated whether disruption of one or both apoptosis pathways in aggressive B-cell lymphomas is associated with resistance to chemotherapy induced cell death and whether TRAIL/Apo2L can induce apoptosis in chemotherapy refractory B-cells.

B-cell lines and isolated human B-cell lymphoma cells were incubated with etoposide and TRAIL/Apo2L, in the presence or absence of caspase 8 and 9 inhibitors. Caspase activation was determined by Western blot and fluorimetric analysis. Execution of apoptosis was determined by morphological analysis.

In sensitive cell lines etoposide and TRAIL/Apo2L induced cell death depended on activation of both caspase 8 and caspase 9. In cell lines and lymphoma samples levels of etoposide and TRAIL/Apo2L induced caspase activation and apoptosis varied strongly between cell lines and etoposide resistant cells were frequently sensitive to TRAIL/Apo2L.

We conclude that in B-cell lymphomas and B-cell lymphoma derived cell lines etoposide induced cell death depends on activation of the apoptosis cascade, and that disruption of etoposide induced apoptosis pathways is a frequent event. Moreover, etoposide resistant B-cell lymphomas can still be sensitive to TRAIL/Apo2L.

Nuclear Morphometry, Immortalization, and Apoptosis in Laryngeal Cancer

© Laila Seada¹, Ahmed Khafagy²

¹ Benha Faculty of Medicine, Benha, Egypt, ² Ain Shans Faculty of Medicine, Cairo, Egypt

Background and Objectives: Laryngeal carcinoma is the most frequent neoplasm in the head and neck region and is notably prevalent in areas such as the Mediterranean basin. However, the numbers of reports that deal with the molecular biology of laryngeal carcinoma in this region are few. Thirty-three laryngeal cancer specimens were studied for the expression of telomerase catalytic unit (hTERT), bcl-x and bcl-2 together with morphometric analysis of nuclear parameters. **Material and methods:** The standard peroxidase method was used for immunohistochemical localization of hTERT, bcl-x and bcl-2 antibodies. Feulgen staining was used before morphometric analysis. **Results:** Expression of telomerase hTERT was found in 78.8% of cancers and in 12/16 adjacent tissue and was comparable to previous results from other studies using TRAP assays. Low bcl-2 and high bcl-x expression was also detected in 18.2% and 60.8% respectively. A significant correlation could be found between high telomerase expression and tumor grade, nuclear area and nuclear short axis. **Conclusion:** Immunohistochemical detection of hTERT is comparable to other assays and could be related to higher tumor grade, increased nuclear area and short axis. Its localization in nearby mucosa could favor the theory of field cancerization.

Telomerase Transduced, Life Span Extended Human T Cells Acquire Chromosomal Aberrations and a Premalignant Genotype

© MWJ Schreurs, RI Klein Geltink, EWM Kueter, AATP Brink, B Carvalho, CJLM Meijer, MAJA Hermsen, GA Meijer, E Hooijberg

Department of Pathology, VU University Medical Center, Amsterdam, Netherlands

Adoptive transfer of tumor reactive T lymphocytes represents a promising strategy to treat cancer patients. In order to obtain sufficient T cell numbers for adoptive immunotherapy, significant *in vitro* expansion of such T cells is required. The replicative potential of normal human somatic cells, including T cells, is limited by erosion of the telomeric ends of chromosomes and the resulting state of replicative senescence. However, this process can be efficiently counteracted by introduction into pre-senescent cells of human telomerase reverse transcriptase (hTERT) [1,2]. Since (over)expression of hTERT can be associated with malignant transformation, it is of utmost importance to evaluate the safety of hTERT mediated life span extension before clinical application. Consequently, we performed an extensive cytogenetic analysis of hTERT transduced, HPV16 E7 specific human cytotoxic T lymphocytes (CTL), potential candidates for adoptive immunotherapy of cervical carcinoma. Our results, obtained by DAPI karyotype staining, comparative genomic hybridization (CGH) and spectral karyotyping (SKY) clearly indicate the presence of chromosomal aberrations in hTERT transduced CTL, not observed in their untransduced counterparts. In spite of the lack of apparent malignant transformation *in vitro*, the mere presence of chromosomal aberrations, including unbalanced translocations, in hTERT transduced CTL is indicative of a premalignant genotype. Collectively, hTERT transduction of human CTL is a valuable tool to allow their prolonged availability for preclinical purposes *in vitro*, however imposes an unacceptable risk for clinical application *in vivo*.

1. The Journal of Immunology, 2000, 165: 4239-4245

2. The Journal of Immunology, 2003, 171: 2912-2921

Analysis Of Head And Neck Squamous Cell Carcinoma In Young Patients Using Microarray Comparative Genomic Hybridisation

© EM O'Regan¹, P Smyth², SP Finn², S Cahill², R Flavin², C Timon³, M Toner¹, JJ O'Leary², OM Sheils²

¹ Dublin Dental School and Hospital and University of Dublin Trinity College, Dublin, Ireland, ² Dept of Histopathology Research, University of Dublin Trinity College, Dublin, Ireland, ³ Dept of Head and Neck Surgery, St. James's Hospital, Dublin, Ireland

Head and neck squamous cell carcinoma (HNSCC) typically affects patients in the sixth and seventh decade, with a history of tobacco and alcohol use. Recently, a marked increase in the number of cases occurring in patients under 40 years of age has been noted worldwide, many of them being nonsmokers. Comparative genomic hybridisation (CGH), allows comprehensive screening of the genome for gains and losses of DNA segments thus providing an overall picture of genomic imbalances.

Aim To assess genomic aberrations in HNSCCs found in young patients (<40 yrs), using microarray CGH and to compare this pattern with the genomic aberrations found in HNSCC in older patients (>40 years).

Methodology Microarray CGH was performed on 20 cases of HNSCC cases (including 9 < 40 years old and 9 nonsmokers).

Results: The mean number of gains and losses in the older cohort was 31, in contrast to only 15.5 aberrations in the young non-smokers. There were significant differences between the younger and older patients with variations in aberrations (p<0.05) at the following loci MSH3 (5q11.2), p16 (9p21), CDK2 (12q13) CDH13 (16q24), Pak1 (11q13). Also there were significant differences (p<0.05) in the aberration profiles of smokers and non-smokers for example FHIT (3p), 5p, E2F5 (8p), AKT2 (19q), and 20qtel.

Conclusion: Microarray CGH demonstrates that there is less genomic instability in the young non-smokers with HNSCC than in the typical HNSCC patient, and the significantly different genomic profile observed in these young patients suggests that HNSCC presenting at a younger age and without any known risk factors has a different genomic profile to the classically described HNSCC.

Dysregulated Expression of Sonic Hedgehog Pathway Genes in Colonic Neoplasia

© A. Oniscu, R.M. James, R.G. Morris, S. Bader, R.D.G. Malcolmson, D.J. Harrison

Division of Pathology, The University of Edinburgh, Edinburgh, United Kingdom

Hedgehog (Hh) signalling pathway, crucial for normal development and patterning of various human organs, has been recently implicated in cancer, leading us to study the expression of the Hh genes in colon cancer. Normal colon and colonic lesions: hyperplastic polyps, adenoma and colonic adenocarcinoma, were examined by immunohistochemistry using antibodies against Sonic hedgehog (Shh), Patched (Ptch) and Smoothened (Smoh). Hh signalling pathway members are expressed in normal colonic epithelium, with Shh expressed at the top of the crypts and a few basally located cells, Ptch in the neuroendocrine cells and Smoh at the brush border of superficial epithelium. RT-PCR from laser-microdissected crypts from normal human colon confirmed that mRNAs encoding these proteins are expressed in colonic epithelium. Shh, Ptch and Smoh were over-expressed in hyperplastic polyps, adenomas and adenocarcinomas of the colon and Shh expression correlated with an increased expression of the proliferation marker Ki-67 in all lesions examined. To address whether the Hh signalling pathway is functional in the gut, primary murine colonocytes were exposed to either Shh-peptide or anti-Shh 5E1 antibody. The proportion of cells in S-phase was assessed by bromodeoxyuridine incorporation. We found that exogenous Shh promotes cell proliferation in colonocytes while anti-Shh inhibits proliferation, suggesting that Shh is required for proliferation of epithelial cells *in vitro*.

We suggest that Shh is required during epithelial proliferation in the colon and that there is a possible role for Hh signalling in epithelial colon tumour progression *in vivo*.

Septin 9 interacts with cytoskeletal factors leading to altered cell migration and resistance to microtubule-disrupting drugs

© P A Hall, A D Chacko, S Chanduloy, S W Church, R D Kennedy, S E H Russell

Centre for Cancer Research, QUB, Belfast, United Kingdom

Septins are an evolutionarily conserved gene family of GTP binding proteins associated with cytokinesis and cell polarity. Several lines of evidence implicate human septins with neoplasia including their involvement as fusion partners with MLL, allelic imbalance and over-expression in tumour cells. We have established cell lines expressing the Sept9-v4 isoform, and a constitutively active GTPase mutant G144V. We observe profound morphological changes with an increased number and length of actin-rich filopodia. In cell wounding experiments of confluent monolayers we observed differences in the kinetics of healing, data confirmed by time-lapse microscopy and Boyden chamber assay. The morphology of cell movement also differed. Wild type and G144V mutants bind to Cdc42 and N-WASP and the role of Cdc42 is confirmed by abrogation of the response by dominant negative Cdc42. Sept9 has been previously shown to interact with microtubules, and here we show that Sept9 over-expressing cell lines display increased resistance to the microtubule interacting drugs paclitaxel and vinorelbine without increased resistance to DNA damaging agents. Such properties indicate that Sept9 has a role in both tumour cell migration as well as drug resistance. We propose that the effects of Sept9 on the actin and tubulin cytoskeletons reflect a novel signalling role for septins via Cdc42. Our data makes a novel connection between the structural and biochemical properties of Sept9 and the genetic studies that have linked Sept9 to human cancer.

S100A11 Protein is Overexpressed in Common Human Cancers With Spatial Translocation From the Nucleus to Cytoplasm

© SS Cross¹, FC Hamdy², JC Deloulme³, I Rehman²

¹ Academic Unit of Pathology, School of Medicine & Biomedical Sciences, University of Sheffield, Sheffield, United Kingdom, ² Academic Urology Unit, School of medicine & Biomedical Sciences, University of Sheffield, Sheffield, United Kingdom, ³ Departement de Biologie Moleculaire et Structurale du Commissariat a l'Energie Atomique, INSERM Unite 244, Commissariat a l'Energie Atomique, Grenoble, France

S100A11 (S100C, calgizzarin) is a member of the EF-hand type calcium binding protein family which includes some proteins that have abnormal patterns of expression in human cancer. S100A11 has been shown to be expressed in most human epithelia and there is a report of reduced expression in carcinomas, but the data was only on 14 cancers. There is also an *in vitro* report of S100A11 being a key mediator of calcium-induced growth inhibition of human epidermal keratinocytes. We have performed an immunohistochemical survey of S100A11 expression on a custom made tissue array containing 291 tissue cores representing 28 human tissue types and 21 different tumour types. There was exclusively nuclear expression in virtually all epithelia except proliferative phase endometrium. There was expression in the majority of cancers including 40/45 breast cancers, 4/4 colorectal cancers, 8/8 cutaneous basal cell cancers, and 5/5 gynaecological cancers. However the expression in the tumours was cytoplasmic as well as nuclear. Other studies have shown that in the nucleus S100A11 increases the transcription of p21 which inhibits cell proliferation. Our results suggest that the cytoplasmic translocation of S100A11 in cancers could lead to increased proliferation in these cells. The mechanism for the translocation requires further investigation.

Blottin: A Novel TFF2-Binding Protein of Foveolar Cells

© MD Evans¹, WR Otto¹, K Patel², I McKinnell², C-Y Lee¹, D Frith¹, S Hanrahan¹, N Blin³, T Kayademir³, R Poulson¹, R Jeffery¹, T Hunt¹, NA Wright¹, F McGregor¹, K Oien¹

¹ Cancer Research UK, London & Glasgow, United Kingdom, ² Royal Veterinary College, London, United Kingdom, ³ University of Tubingen, Tubingen, Germany

Purpose: Trefoil factor family (TFF) peptide receptors remain elusive. In experiments to find such a molecule, we identified a novel murine TFF2-binding protein which we have named Blottin. **Methods:** We made a fusion protein of mouse TFF2 with secretory embryonic alkaline phosphatase (AP), expressed it in A293 cells, and probed tissue sections for binding. Substantial binding to gastric foveolium was seen. **Results:** A single protein was found by 2-D Western blots using the same ligand, and identified by mass spectrometry. This has only mammalian homologues, and is undescribed at the protein level. By RACE, the full-length mRNA averages 800bp in human, mouse, rat and cow, and these show much evolutionary conservation. The protein has molecular weight of 21kDa, a hydrophobic signal peptide and a pI of 6.9. Using rabbit antibodies, and mRNA *in situ* hybridisation, we found large signals in gastric foveolar cells. It is mainly cytoplasmic, but with some membrane associations, consistent with its N-, and particularly C-, termini being of hydrophobic amino acids; the latter has 3 potential myristylation sites. SAGE analyses report that the mRNA is reduced in human gastric cancers. Four human GI cell lines, including gastric (HGT-101, Kato-3) and colorectal (HT-29, Col-1), show positivity for Blottin by PCR and immunocytochemistry. Pilot data using *in vitro* wounding assays suggest antibody to blottin may increase wound recovery in HT-29 cells. Blottin ISH on human GI pathological sections shows high expression in surface UACL epithelium, gastric metaplasia of duodenum and pseudopyloric metaplasia of the stomach, mimicking some sites for TFF1 expression. **Conclusions:** A new TFF2 binding protein is reported in mammalian gastric foveolium, which may have expression patterns similar to TFF1.

Bone Marrow contributes to Tumour Stroma

© NC Direkze¹, K Hodivala-Dilke³, R Jeffery¹, T Hunt¹, D Oukrif⁴, SL Preston¹, MR Alison², NA Wright¹

¹ Cancer Research UK, London, United Kingdom, ² Imperial College, London, United Kingdom, ³ Barts and the London, Queen Mary School of Medicine and Dentistry, London, United Kingdom, ⁴ University College, London, United Kingdom

Background. We have previously shown that not only can bone marrow contribute to myofibroblast populations in the mouse and human gut but that this is an example of a more generalised phenomenon that is exacerbated by injury. We now report that the bone marrow contributes to myofibroblast populations in tumour stroma.

Method. RIPTag mice develop β cell tumours of the pancreas. Female RIPTag mice were transplanted with male bone marrow. The fate of the bone marrow derived cells was followed by detection of the Y chromosome by *in situ* hybridisation, combined with immunohistochemistry for myofibroblast markers such as smooth muscle actin. We also examined samples from patients who developed tumours after sex-mismatched bone marrow transplant in a similar way.

Results. Approximately 25% of myofibroblasts were found to be bone marrow-derived in pancreatic tumours post sex-mismatched bone marrow transplant. These tended to be concentrated within 1 high power field of the tumour edge ($p < 0.05$). Incidentally we have also found evidence of donor derived insulin producing cells. We have also found evidence of donor derived myofibroblasts in human tumours post sex mismatched bone marrow transplant.

Conclusion. We have shown that the bone marrow contributes to myofibroblast and fibroblast populations in tumour stroma. This is an illustration of the interaction of the bone marrow cells with other tissues and may lead to the development of new avenues for therapy.

Dietary Fibre Accelerates Polyp Development And Proliferation In The Min Mouse

© N Mandir, RA Goodlad

Cancer Research UK, London, United Kingdom

INTRODUCTION: High fibre diets maybe beneficial and protective against colorectal cancer. Some animal studies and human epidemiological studies have indicated the converse. We aimed to investigate this by using the Min mouse (C57BK/6J-ApcMin) that has a loss of APC gene function resulting in multiple intestinal polyps making it an ideal model for testing dietary factors and their effects on tumour progression.

METHOD: Four week old mice were used, fed either a chow diet, semi-synthetic diet or semi-synthetic diet supplemented with cellulose, wheat bran or apple fibre for 8 weeks. Fixed tissue was scored for polyp number and tumour burden. Stained tissue was microdissected to score for cell proliferation and crypt fission.

RESULTS: there were significant increases in polyp number in the proximal small intestine with bran. The action of apple fibre was seen throughout the small bowel and the mean number of polyps in the small intestine of the apple gp was 99.2 ± 11.1 vs. 40.0 ± 8.2 for the control 'semi synthetic diet' gp ($P < 0.004$). There were significant increases in tumour burden with apple fibre in the small intestine and with bran in the colon. There were marked differences in crypt fission index (CFI) in the distal small bowel with bran at 2.5% and with apple at 3.2% compared to control at 1%. In the mid colon, bran resulted in a CFI of 4% compared to control of 0.9%.

CONCLUSION: The most fermentable fibre was apple, which doubled polyp no., tumour burden and altered crypt fission in the small bowel. Wheat bran markedly increased the size of the polyps in the colon. Different fibres have different fermentation rates and the products of these can stimulate cell proliferation in vivo and thus be risk factors for tumour formation.

High Resolution Microarray-CGH Analysis Using Spotted Oligonucleotides

© B. Carvalho¹, E. Ouwerkerk², G.A. Meijer¹, B. Ylstra²

¹ Department of Pathology, VU University Medical Center, Amsterdam, Netherlands, ² Microarray Core Facility, Medical Faculty, VU University Medical Center, Amsterdam, Netherlands

Comparative genomic hybridisation array (Array-CGH) is nowadays the method of choice for studying genome-wide DNA copy number changes. So far, either amplified representations of BACs/PACs or cDNAs have been spotted as probes.

Here we propose to use spotted oligonucleotides, recently used in expression profiling, as probes for array-CGH.

Hybridisation of 2 tumour cell lines, with known array-CGH profile, to oligonucleotides that are mapped to the human genome.

We show that oligo-CGH is able to detect amplifications with high accuracy and greater spatial resolution, compared to other current array-CGH platforms. In addition, single copy-number changes can be detected with a lower resolution, however still comparable to conventional CGH.

Oligos are easy to handle and flexible, since they can be designed for any part of the genome without the need for laborious amplification procedures. The availability of a full-genome array (around 30.000 oligos) would represent a big step forward in the analysis of DNA copy number changes. Moreover, this technique can be easily applied to any organism for which the full-genome sequence is known.

Modes of Growth of Colorectal Adenomas (Flat and Polypoid): Evidence Against 'Top-Down' as a Major Method of Expansion.

© SL Preston¹, D Oukrif³, A Kyriakides¹, G Elia¹, M Novelli³, N Direkze¹, IC Talbot⁴, IP Tomlinson¹, L Lipton¹, NA Wright²

¹ Cancer Research UK, London, United Kingdom, ² Barts and the London Hospital, London, United Kingdom, ³ University College London, London, United Kingdom, ⁴ St Marks Hospital, London, United Kingdom

BACKGROUND: Controversy exists concerning the mode of expansion of colorectal adenomas. The Vogelstein group champion the 'top-down' theory - lesions arise and grow across the mucosal surface and down into the crypts, whereas our group propose 'bottom-up' spread. 'Top-down' spread is said to be the mode of expansion of flat adenomas. **METHODS:** 116 tubular, 47 tubulovillous, 58 villous adenomas and 44 flat adenomas from 97 patients were available, measuring from 5 mm to 3.6 cm in diameter. Sections were stained with H&E, and by immunohistochemistry for Ki-67 and MCM2 and carbonic anhydrase II to detect both β -catenin-dependent and independent gene products. **RESULTS:** (i) 44% of all adenomas showed nuclear β -catenin; (ii) only 9% of adenomas, mainly tubulo-villous, showed 'top-down' spread, but growth from the surface between crypts was frequently seen; (iii) growth by budding or fission was common in all types; (iv) 11%, of mainly villous adenomas, showed basal crypt nuclei with nuclear β -catenin, while more superficial cells showed cytoplasmic and membranous staining and (v) a 'reversal' of proliferative architecture in adenomatous crypts was frequently seen. **CONCLUSIONS:** (i) 'top-down' spread is rare and associated with a villous format; (ii) adenomatous crypts are mainly formed by fission, but also by a previously unreported mode of growth where new crypts develop between pre-existing crypts; (iii) the loss of nuclear β -catenin indicates positional regulation and (iv) 'reversal' of proliferation is a feature of larger lesions. We conclude that crypt fission and budding, and the formation of new crypts from the surface, are the main modes of expansion of colorectal adenomas. Vogelstein's results are not explained by the analysis of flat adenomas.

Tubular Regeneration After Folic Acid-Induced Acute Renal Failure Involves Proliferation Of Bone Marrow-Derived Epithelium

T-C Fang⁴, © R Poulsom¹, HT Cook², MR Alison², NA Wright³

¹ Histopathology Unit, Cancer Research UK, London, United Kingdom, ² Dept. Histopathology, Imperial College Hammersmith Campus, London, United Kingdom, ³ Queen Mary - University of London, London, United Kingdom, ⁴ Division of Nephrology, Tzu Chi General Hospital, Hualien, Taiwan

OBJECTIVE: To see if bone marrow-derived cells contribute to recovery of tubules after folic acid (FA)-induced acute renal failure.

METHODS: Female FVB/N mice (6wk old) were 'lethally-irradiated', transplanted with male bone marrow and later assigned to treatment groups (18/group): CON = vehicle injection (150 mM NaHCO₃ i.p.); FA = folic acid (250 mg/kg i.p.), and killed 3 or 7 days later (1 hour after injection of ³H-Thymidine). Kidney sections were stained for proximal or distal epithelial markers, for Y-chromosomes (in situ hybridization), and subjected to autoradiography. Renal tubular epithelial cells (1000 per mouse) in S-phase were scored as female (recipient) or male (bone marrow-derived tubular cells (BMDTCs)).

RESULTS: FA induced damage of proximal and distal tubular epithelium. The ³H-labelling index (LI) of proximal tubular epithelium of recipient origin increased significantly after FA, from a baseline of $0.62 \pm 0.08\%$ (mean±sem) to $5.02 \pm 0.19\%$ at 3d and $1.27 \pm 0.06\%$ at 7d after FA. The ³H-LI for BMDTCs also increased significantly after FA but transiently, from $0.03 \pm 0.02\%$ before FA injection to $0.65 \pm 0.06\%$ at 3d then decreased to $0.05 \pm 0.02\%$ at 7d after FA. The abundance of ³H-labelled tubular cells of BM origin increased 20-fold after FA damage at day 3. The ³H-LI response pattern of distal tubular epithelium to FA was similar to that of proximal tubular epithelium; collecting ducts were almost unaffected.

CONCLUSION: We confirm that a small proportion of renal tubular cells are derived from the bone marrow, and report for the first time that they respond appropriately by cell proliferation after FA damage.

Risk For \geq CIN3 After Five Years In HrHPV Positive And HrHPV Negative Women With Normal Cytology

© NWJ Bulkman, L Rozendaal, PJF Snijders, CJLM Meijer
VU University Medical Centre, Amsterdam, Netherlands

In a prospective population-based study, we studied the risk for \geq CIN3 of hrHPV-positive and hrHPV-negative women after five years.

From 1995 to 1999, women who attended the Dutch screening programme age 30-60 years participated. Cytology and hrHPV-testing (GP5+/6+ PCR) was performed.

The mean age of 3,203 included women was 44.8. 3,031 (94.6%) women had normal cytology. 107 (3.5%) had a positive hrHPV-test and 2,924 (96.5%) had a negative hrHPV-test. Follow-up was available for respectively 85 and 2,340 women (80.0%), with a total of 6/2,425 (0.25%) \geq CIN3. The mean follow-up time was 81.3 months (60.5-104.5). For 85 hrHPV-positive women the follow-up revealed 5 (5.9%) \geq CIN3. For 2,340 hrHPV-negative women follow-up revealed 1 (0.04%) \geq CIN3. The negative predictive value of hrHPV-testing in women with normal cytology for \geq CIN3 was 99.96% (95%CI; 99.76-99.99).

For women with normal cytology and a positive hrHPV-test the relative risk for \geq CIN3 was 137.6 compared to women with normal cytology and a negative hrHPV-test (95%CI; 16.3-1165.4). Compared to women with normal cytology not hrHPV-tested (risk for \geq CIN3 0.25%), in women with normal cytology and a negative hrHPV-test the risk for \geq CIN3 (0.04%) is so much lower that for them the screening interval can be significantly increased with at least 4 years.

Ex vivo IL-1Ra gene therapy for disc degeneration

CL Le Maitre¹, NJ Rothwell², © AJ Freemont¹, JA Hoyland¹
¹Injury Repair and Rehabilitation Research Group, Manchester University, Manchester, United Kingdom, ²Neuroscience, Manchester, United Kingdom

A significant proportion of cases of back pain are associated with intervertebral disc degeneration. However no back pain treatments target the disease processes of disc degeneration although such treatments would be of potential benefit for back pain. We have shown that IL-1 is a key mediator of disc degeneration, hence its inhibition may benefit patients with back pain. The natural inhibitor of IL-1, IL-1Ra could be used in this context, the problem being how to deliver this molecule to an avascular tissue for the length of time needed to inhibit a chronic disease process. In this presentation we report work on establishing a gene delivery system for this purpose.

Methods: Production of molecules involved in matrix degradation, a key feature of degeneration, was assessed by ELISA and real time PCR in freshly extracted human disc cells and cells infected with an adenoviral vector carrying the IL-1Ra gene (Ad-IL-1Ra). Also normal disc cells were infected with Ad-IL-1Ra, labelled and injected into explants of degenerate disc. Immunohistochemistry was used to assess IL-1Ra production in these discs.

Results: Both NP and AF cells infected with Ad-IL-1Ra produced IL-1Ra in monolayer and alginate cultures, with elevated levels maintained for 72 days post infection in alginate culture. In addition infection inhibited the effects of IL-1. When infected cells were injected into disc explants elevated levels of IL-1Ra were observed which was maintained for the 2 weeks investigated.

Conclusions: This study has shown that the use of *ex vivo* gene transfer to degenerate disc tissue is a feasible therapy for the prevention of disc degeneration.

Profiling of Caspase Signaling Pathways Predicts Clinical Response to Chemotherapy in Diffuse Large B-Cell Lymphomas

JJF Muris¹, SAGM Cillessen¹, I van Houdt¹, W Vos¹, J van Krieken², NM Jiwa⁴, GJ Ossenkoppele¹, PM Jansen³, © CJLM Meijer¹, JJ Oudejans¹

¹VUmc, Amsterdam, Netherlands, ²Radboud University Medical Center, Nijmegen, United Kingdom, ³LUMC, Leiden, United Kingdom, ⁴MCA, Alkmaar, United Kingdom

We investigated whether inhibition caspase 8 and/or caspase9 signaling pathways in biopsy specimens predicts clinical outcome. in patients with diffuse large B-cell lymphomas (DLBCL)

Expression levels of Bcl-2 and XIAP were used to determine the status of the caspase 9 pathway. Expression levels of c-FLIP and numbers of active caspase 3 positive lymphoma cells were used to determine the status of the caspase 8 mediated pathway.

Inhibition of either or both caspase signalling pathways was detected in all cases. Thus three groups were identified: one group of lymphomas with only inhibition of the caspase 8 pathway, one group with inhibition of both pathways and one group of lymphomas with inhibition of the caspase 9 pathway. Inhibition of the caspase 9 mediated pathway was strongly associated with a poor response to chemotherapy and a usually fatal outcome, whereas inhibition of only the caspase 8 mediated pathway was associated with excellent clinical outcome. This prognostic value was independent from the IPI and from a germinal centre versus non-germinal centre cell phenotype.

Our results indicate that inhibition of the caspase 9 and not caspase 8 mediated pathway is a major cause for a poor clinical response to chemotherapy in patients with nodal DLBCL.

Genotypic And Phenotypic Characteristics Of Human Breast Carcinoma

© E.A Rakha, J.A.L Armour, S.E Pinder, C.E Paish, I.O Ellis
City Hospital, NHS Trust, Nottingham University, Nottingham, United Kingdom

Loss of chromosomal material at 16q is one of the most frequent genetic events in breast cancer. The smallest region of deletion at 16q has been localised to 16q22.1, indicating the presence of a tumour suppressor gene (TSG) at this region. Multiplex Amplifiable Probe Hybridisation (MAPH) is a simple, accurate and a high-resolution technique that provides an alternative approach to DNA copy-number measurement. The aim of this study was to apply MAPH to measure the genomic copy number alteration at 16q22.1 in malignant breast tissues and to examine the expression of the most likely candidate genes at this region by immunohistochemistry. RESULTS: We identified deletion of the whole 16q22.1 region in 13 cases (37%) and interstitial deletion in 9 cases (26%). We delineated the smallest region of deletion at 16q22.1 to a 3Mb region centromeric to the P-cadherin gene. A significant correlation was found between E-cadherin protein expression and gene copy number changes, as well as with histological tumour type. No correlation was detected between the expression of P-cadherin, E2F-4, CTCF or TRF2 genes with tumour type or with copy number changes. No expression of Ksp-cadherin or VE-cadherin was detected in normal and/or malignant epithelial tissues of the breast in these cases. CONCLUSIONS: We have demonstrated that MAPH is suitable for the assessment of genomic imbalances in malignant tissues. The smallest region of deletion in invasive ductal tumours of the breast at 16q22.1 is located between the VE-cadherin and P-cadherin genes. Although our results support E-cadherin as the TSG in invasive lobular carcinoma, they argue against the candidacy of E2F-4, CTCF, TRF2, P-cadherin, Ksp-cadherin or VE-cadherin as TSGs in ductal carcinoma of the breast.

Intestinal Tumourigenesis : Navigating Through The β -Catenin Cascade

© M Ilyas

University of Leeds, Leeds, United Kingdom

Colorectal cancers usually arise due to increased levels of β -catenin protein altering transcription of target genes. We identified β -catenin target genes in intestinal tumours arising in the *Multiple Intestinal Neoplasia (Min)* mouse (a model of Familial Adenomatous Polyposis) by comparing the transcriptomes of tumours with normal mucosa. Over 2 fold change in expression was seen in 121 genes (63 up, 58 down). Three members of the *Matrix Metalloproteinase (Mmp)* gene family were up-regulated and the expression of 15 *Mmp* genes was studied by Real-Time quantitative RT-PCR (Q-PCR). Multiple *Mmp* genes were found to be up-regulated and each of 59 tumours showed up-regulation of at least 4 different *Mmp* genes. Since six of the up-regulated genes map to the same region on chromosome 9, the changes may be coordinated.

Osteopontin (OPN) was also up-regulated and gene knockdown using RNA-interference in the cell line CMT93 inhibited proliferation ($p=0.008$) suggesting OPN may influence tumour development through stimulating proliferation.

The OPN promoter was analysed and shown to be non-responsive to β -catenin signaling but responsive to c-myc. Since *C-myc* itself is activated by β -catenin target gene, these data imply that up-regulation of osteopontin is a secondary event following up-regulation of *C-myc*.

Cyclin D1 (*Cnd1*) was also up-regulated and we tested the importance of cyclin D1 by crossing Min mice with cyclin D1 knockout mice. Cyclin D1 was not essential to tumour development but it did appear to act as a modifier gene. Thus, although β -catenin activates a cascade of downstream events, scrutiny of these events is increasing our understanding of intestinal tumour formation.

Wnt-5a Expression In Breast Carcinomas – Differences Between In-Situ and Invasive Disease

J Dhillon, © RA Walker

University, Leicester, United Kingdom

The wnt family of secreted proteins play diverse biological roles in the regulation of cell growth, differentiation and oncogenesis, signalling through β -catenin and Ca^{++} pathways and, more recently described, EGFR. Wnt-5a is a non-transforming member of the family. There is conflicting evidence for its role in breast cancer: in vitro reduced expression has been related to enhanced migration; in vivo both upregulation and decreased expression has been found, the latter associated with early relapse.

Immunohistochemistry has been used to detect wnt-5a, E-cadherin and α, β, γ catenin in 81 infiltrating ductal (IDC), 15 infiltrating lobular (ILC) carcinomas and 11 DCIS. Findings were related to tumour size, grade, node status, ER and EGFR, and compared to each other using Spearman's rho test

50% of invasive carcinomas and 82% of DCIS had a higher level of wnt-5a than associated normal breast, 12.5% and 18% respectively were the same, and 36% of invasive were lower/negative. Stromal cell reactivity was present in 48% IDC, 72% ILC and 82% DCIS. There were no relationships with size, grade, node or receptor status and no correlation with ether membrane or cytoplasmic staining for E-cadherin or the catenins. Nuclear β -catenin was not seen.

The findings point to a potential role for wnt-5a in the in-situ stages of breast cancer development, but its significance and signalling pathway in invasive disease remains unclear.

Stem Cells and Regenerative Medicine

© J Polak

Tissue Engineering and Regenerative Medicine Centre, Imperial College London, Chelsea & Westminster Hospital, London, United Kingdom

Stem cells are defined by their capacity for long-term self-renewal without senescence and ability to differentiate into one or more specialized cell types. Recent discoveries in stem cell biology are presenting new opportunities for the use of cell-based therapies in disease areas with critical, unmet medical needs, particularly through the application of regenerative medicine. This emerging field approaches the repair/replacement of tissues/organs by incorporating the use of cells, genes or other biological building blocks along with bioengineered materials and technologies. Adult, cord blood, embryonic and fetal stem cells hold great potential for use in these new therapeutic strategies and current studies are evaluating their differentiation potential, frequency, availability, and the normality, compatibility, trafficking/homing and engraftment of their derivative progenitor and mature phenotypes. At present, all types of stem cells are being investigated as none has been shown to have unique advantages. Major research goals include the control of stem cell differentiation into specific phenotypes, an objective that must be met if the cells are to be used for therapeutic implantation, testing drugs or screening potential toxins, scale up of production and developing robust methods to assess engraftment. Clearly, the potential benefits of stem cells to medicine and to the healthcare economy are immense.

S100A6 Protein is Overexpressed in Breast Cancer and is Significantly Associated With Increasing Tumour Grade But Not With Axillary Lymph Node Metastasis

© SS Cross¹, SP Balasubramanian², CA Evans³, MWR Reed², FC Hamdy⁴, I Rehman⁴

¹ Academic Unit of Pathology, School of Medicine & Biomedical Sciences, University of Sheffield, Sheffield, United Kingdom, ² Academic Surgical Oncology Unit, School of Medicine & Biomedical Science, University of Sheffield, Sheffield, United Kingdom, ³ Department of Histopathology, Sheffield Teaching Hospitals NHS Trust, Sheffield, United Kingdom, ⁴ Academic Urology Unit, School of Medicine & Biomedical Sciences, University of Sheffield, Sheffield, United Kingdom

S100A6 is a member of the S100 calcium binding protein family and there are some reports of overexpression of this protein in tumours, however those descriptions do not include a definitive study on breast cancers. In normal breast tissue we found that S100A6 was only expressed in the myoepithelial cells, so expression in tumours could be a marker of myoepitheliomatous differentiation and may have related prognostic implications. 400 invasive breast cancers (20% grade 1, 50% grade 2, 30% grade 3) were sampled in triplicate in tissue microarrays and immunohistochemistry for S100A6 was performed with 2 different antibodies. The results for both antibodies were virtually identical. There was strong immunohistochemical expression of S100A6 in 50% of tumours. There was a significant increase in tumour expression of S100A6 with increasing tumour grade ($p<0.0005$, median value for grade 1=0, grade 2=3, grade 3=5). There was no significant association between S100A6 expression and axillary lymph node metastasis ($p=0.11$). In a separate population of 36 breast cancers and sampled axillary lymph node metastases there was concordance of S100A6 expression between primary and metastasis in 72%, loss of expression in metastasis in 17% and gain of expression in metastasis in 11%. S100A6 is overexpressed in breast cancer with increasing frequency in higher grade tumours, the mechanism of this warrants further investigation.

Osteoprotegerin is Overexpressed in Breast Cancers and Intratumoural Endothelial Cells and is Significantly Associated With Tumour Grade But Not With Axillary Lymph Node Metastasis

© SS Cross¹, SP Balasubramanian², CA Evans³, MWR Reed², I Holen⁴

¹ Academic Unit of Pathology, School of Medicine & Biomedical Sciences, University of Sheffield, Sheffield, United Kingdom, ² Academic Surgical Oncology Unit, School of Medicine & Biomedical Sciences, University of Sheffield, Sheffield, United Kingdom, ³ Histopathology Department, Sheffield Teaching Hospitals NHS Trust, Sheffield, United Kingdom, ⁴ Academic Unit of Clinical Oncology, School of Medicine & Biomedical Sciences, University of Sheffield, Sheffield, United Kingdom

Osteoprotegerin (OPG) is a protein, physiologically involved in control of bone growth, which has been shown to act as a decoy receptor for tumour necrosis factor related apoptosis inducing ligand (TRAIL) and thus to act as a tumour cell survival factor *in vitro*. We have shown that OPG is not expressed in normal breast tissue but is strongly expressed in luminal epithelial cells with columnar change. In this study we look at OPG expression in breast cancers and analyse its expression in relation to surrogate markers of tumour aggressiveness. 400 invasive breast cancers (20% grade 1, 50% grade 2, 30% grade 3) were sampled in triplicate in tissue microarrays and immunohistochemistry for OPG was performed. There was strong immunohistochemical expression of OPG in 40% of tumours. It was also noted that intratumoural endothelial cells showed strong expression of OPG in 37% of tumours. There was a significant decrease in tumour expression of OPG with increasing tumour grade ($p=0.001$) but a significant increase in intratumoural endothelial cell OPG expression with increasing tumour grade ($p=0.004$). There was no significant association between either protein and axillary lymph node metastasis ($p=0.48$, $p=0.44$ respectively). There was no significant association between tumour cell and endothelial cell OPG expression ($\kappa=0.17$).

E-Cadherin Expression In Invasive Non-Lobular Carcinoma Of The Breast And Its Prognostic Significance

© E.A Rakha, D.A Abd El-Rehim, S.E Pinder, I.O Ellis
Nottingham City Hospital, University of Nottingham, Nottingham, United Kingdom

E-cadherin is a cell adhesion molecule expressed in normal breast tissue and absence of its expression is a characteristic feature of lobular carcinomas. However, in the more frequent non-lobular tumours, its biological and prognostic value is still unclear. Material and Methods: In the current study, E-cadherin expression was assessed immunohistochemistry in a large and well characterized series of invasive non-lobular breast carcinoma ($n=1516$) with a long term clinical follow-up (median of 56 months), using tissue microarray technology, to determine the relationship between its expression and primary tumour characteristics and disease outcome. Results: Membranous expression of E-cadherin was detected in 92.8% of cases. A significant correlation was found between absent or reduced expression of E-cadherin and indicators of poor prognosis including larger tumour size, higher histological grade, development of distant metastasis, regional and local recurrence, tumours negative for estrogen receptors and those positive for p53. No correlation was found between E-cadherin expression and lymph node status. Univariate and multivariate analyses showed that E-cadherin is an independent prognostic indicator of disease free survival and overall survival. The highest significance was detected among patients with definite vascular invasion and those with positive lymph nodes and to a lesser extent in those with bigger tumour size and p53 positivity. Conclusion: These results suggest that E-cadherin may play a role in progression, development of distant metastasis and recurrence in the non-lobular carcinomas of the breast and its immunostaining can be used efficiently in finding patients with poor outcomes especially in those with vascular invasion and positive lymph nodes.

Lymphocytic Lobulitis In Breast Core Biopsy: A Peritumoural Phenomenon

© AG Douglas-Jones
Department of Pathology, University of Wales College of Medicine, Heath Park, Cardiff. CF4 4XW., Cardiff, United Kingdom

The aim of this study is to describe two cases of breast carcinoma associated with an intratumoural lymphocytic infiltrate and peritumoural lymphocytic lobulitis. In both cases initial core biopsy showed lymphocytic lobulitis only but subsequent investigations showed an adjacent invasive ductal carcinoma. Both carcinomas were grade 3 with extensive lymphocytic infiltrate (lymphoepithelioma-like) and showed peritumoural lymphocytic lobulitis extending for 7 mm beyond the margins of the invasive tumour. The infiltrating cells were predominantly of T lineage and the affected lobular breast epithelium expressed HLA DR suggesting an autoimmune pathogenesis. Although diabetic mastopathy may present as a breast mass associated with lymphocytic lobulitis, the cases presented illustrate that lymphocytic lobulitis in core biopsy may represent a peritumoural phenomenon and further investigation is required.

Expression of E2F-4 in invasive breast carcinomas is associated with poor prognosis

© E.A Rakha, C.E Paish, S.E Pinder, I.O Ellis
Nottingham City Hospital, Nottingham University, Nottingham, United Kingdom

The E2F family of transcription factors plays a key role in the control of cellular proliferation and apoptosis. Some family members act as oncogenes, others act as tumour suppressor genes (TSGs), behaviour which appears to be tissue specific. E2F-4 is a member of the E2F family located at the chromosomal band 16q22.1 that shows frequent deletion in breast cancer. In the present study, the expression of E2F-4 was assessed immunohistochemically on paraffin sections from 265 cases of breast carcinoma and the expression was compared to both clinicopathological variables and disease outcome. E2F-4 protein expression was detected in the nuclei and in the cytoplasm of normal and malignant epithelial cells of the breast. In the malignant tissues, no significant loss or decrease of expression was seen in association with any specific tumour type. There was a correlation between increased nuclear expression of E2F-4 and indicators of poor prognosis including larger tumour size ($p=0.000$), grade 3 lesions ($p=0.033$), lymph node stage ($p=0.037$) and poorer Nottingham Prognostic Index group ($p=0.003$). Also, with the development of recurrent disease ($p=0.004$), distant metastasis ($p=0.001$) and poorer outcome including poorer overall survival time ($p=0.002$) and shorter disease free interval ($p=0.001$). In multivariate analysis, E2F-4 was of an independent prognostic significance along with grade and lymph node stage. These results suggest that E2F-4 may play a role in breast cancer progression and that increased nuclear expression is associated with the more advanced tumours with poor outcomes. E2F-4 appears to have an oncogenic role rather than a tumour suppressor role in breast carcinogenesis and hence, it is not the gene targeted by 16q22.1 loss in the carcinoma of the breast.

Expression Of The Transcription Factor CTCF In Invasive Breast Cancer: A Candidate Gene Located At 16q22.1

© E.A Rakha , C.E Paish , S.E Pinder , I.O Ellis
 Nottingham, City Hospital, Nottingham University, Nottingham, United Kingdom

CTCF is a ubiquitous 11-zinc finger protein that plays a role in gene silencing or activation, chromatin insulation and genomic imprinting. The CTCF gene has been mapped to chromosome band 16q22.1 that shows frequent loss of heterozygosity in breast cancer. Because CTCF targets include TSGs and oncogenes and it has the ability to inhibit cell growth and proliferation, it has been suggested that it may be the target gene at the 16q22.1 especially in ductal tumours. In the present study, tissue microarray technology was used to study the expression pattern of CTCF immunohistochemically in 344 cases of invasive breast carcinoma and its expression was correlated with clinicopathological variables and patient outcome. Expression of CTCF was detected in the cytoplasm and nuclei of the normal parenchymal as well as malignant cells of the breast. In the malignant tissues, no significant loss or decrease of expression was noticed in association with any specific tumour type. There was a significant correlation between nuclear and cytoplasmic expression of CTCF and histological grades; lower expression was associated with grade 3 tumours. Cytoplasmic expression was associated with increased tumour size and with the presence of vascular invasion. However, no association was found between CTCF expression and tumour type, lymph node stage, oestrogen receptor expression or patient outcome. *Conclusion:* The current results show that CTCF, although it may play a role in breast carcinogenesis, is unlikely to be the TSG targeted by the 16q22.1 loss in breast cancer and thus another gene or genes at this region remain to be identified.

Expression of luminal and basal cytokeratins in human breast cancer

© DM Abd El-Rehim , S Pinder , IO Ellis
 Department of Histopathology, University of Nottingham, Nottingham, United Kingdom

We have examined basal and luminal cell cytokeratin expression in 1944 cases of invasive breast carcinoma, using tissue microarray technology, to determine the frequency of expression of each cytokeratin subtype, their relationships and prognostic relevance, if any. Expression was determined by immunocytochemistry staining using antibodies to the luminal cytokeratins 7/8, 18 and 19 and the basal cytokeratins 5/6 and 14. Additionally, assessment of alpha smooth muscle actin and estrogen receptor status was performed. The vast majority of the cases showed positivity for ck 7/8, 18 and 19 indicating a differentiated glandular phenotype, a finding associated with good prognosis, ER positivity and older patient age. In contrast, basal marker expression was significantly related to poor prognosis, ER negativity and younger patient age. Multivariate analysis showed that ck 5/6 was an independent indicator for relapse free interval.

We were able to subgroup the cases into four distinct phenotype categories [luminal, mixed luminal/basal, basal and null], which had significant differences in relation to the biological features and the clinical course of the disease. Tumors classified as expressing a basal phenotype [the combined luminal plus basal and the pure basal] were in a poor prognostic subgroup, typically ER negative in most cases. These findings provide further evidence that breast cancer has distinct cellular differentiation subclasses that have both biological and clinical relevance.

Expression and co-expression of the Epidermal Growth Factor Receptor [EGFR] family members in invasive breast cancer

© DM Abd El-Rehim , S Pinder , IO Ellis
 Department of Histopathology, University of Nottingham, Nottingham, United Kingdom

We have evaluated more than 1500 cases of invasive breast carcinoma immunohistochemically using tissue microarray technology to examine the expression of EGFR family receptor proteins. Overall, 20.1% and 31.8% of cases were positive for EGFR and c-erbB-2 respectively and 45% and 45.1% of tumors over-expressed for c-erbB-3 and c-erbB-4 respectively. The expression of either EGFR or c-erbB-2 was associated with bad prognostic features and with poor outcome.

c-erbB-2 had an independent prognostic effect on overall and disease free survival in all cases as well as in the sub-set of breast carcinoma patients with nodal metastases.

Cases were stratified according to receptors co-expression into distinct groups with different receptor positive combinations. Patients whose tumors co-expressed c-erbB-2 and c-erbB-3, as well as those whose tumors co-expressed EGFR, c-erbB-2 and c-erbB-4 showed an unfavorable outcome compared with other groups, whilst combined c-erbB-3 and c-erbB-4 expression was associated with a better outcome. Additionally, we found a significant association between c-erbB-4 homodimer expressing tumors and better disease free survival. In contrast, patients with c-erbB-2 homodimer expressing tumors had a significant poorer disease free survival compared with other cases. These data imply that the combined profile expression patterns of the four receptor family members together provides more accurate information on the tumour behaviour than studying the expression of each receptor in isolation.

Effect of Assay Sensitivity on ER Negativity Rate

© AG Douglas-Jones , JM Morgan , S Wozniac , S Hughes , S Thomas , S Rivett , M McKenny , B Jasani
 Department of Pathology, University of Wales College of Medicine, Cardiff, United Kingdom

An audit of 2,595 consecutive routine ER results determined ER negative rates at 3-month intervals. Sensitivity of the assay was monitored by semiquantitative assessment (H score) of control sections. The H scores of selected sub-groups allowed modeling of the whole set of results to show the relationship between assay sensitivity and ER negativity rate.

The ER negativity rate varied between 7.5 and 21% and assay sensitivity varied by 58 H score points about a mean of 116 (16%). Modeling showed that this range of assay sensitivity would translate into a change in ER negativity rate of 14%. The model also shows how alteration of the threshold for ER positivity changes ER negative rates.

Changes in ER assay sensitivity can account for the differences in ER negativity rate observed in routine clinical practice.

Multiple Papillomatosis of the Breast: Characterisation of 20 Cases

© A G Douglas-Jones, M Khan

Department of Pathology, University of Wales College of Medicine, Cardiff, United Kingdom

In order to characterise the entity, twenty cases of multiple papillomatosis (greater than 5 papillomas) of the breast was studied. The mean age of the patients was 55. Four patients (20%) had a diagnostic procedure only and 16 were treated, 7 (35%) had a wide local excision and 9 (45%) underwent mastectomy. Two cases (10%) were bilateral. The mean number of papillomas per case was 47 (range 5-140) and the papillomas over all cases had a mean diameter of 2mm (range 0.1-11.5mm).

In individual cases the mean size of papillomas ranged between 0.6 and 5mm. In all but one case there were other associated proliferative breast lesions and in half the cases papillomas only accounted for 50% of the lesions present. All the cases contained epithelial hyperplasia (epithelium more than 2 cells thick) and in the different cases between 4.7% and 68.9% of lesions showed epithelial hyperplasia of usual type. 15 (75%) of cases showed atypical ductal hyperplasia (ADH) in the different cases 4.5-38% of lesions showed ADH. Ten (50%) of cases contained DCIS and in the different cases between 5-45% of the lesions were DCIS.

Multiple papillomatosis shows great variation in the numbers of papillomas present but the individual papillomas are small (less than 5mm). Most cases are associated with other proliferative lesions of the breast. All cases show epithelial proliferation and 50% contain foci of DCIS.

Study of the Potential Predictive Factors of Response of Breast Cancer to Chemotherapy

© AR HINNIS, JCA Lockett, RA Walker

University of Leicester, Breast Cancer Research Unit, Leicester, United Kingdom

Chemotherapy is used in the management of breast cancer, either neo-adjuvant or adjuvant, selection being based on pathological features such as size, node status and grade. The aim of this study was to determine whether biological features of breast cancer could provide additional information about the response to chemotherapy.

115 breast cancer patients who had received adjuvant (100) or neo-adjuvant (15) treatment and had died from the disease were studied. Immunohistochemistry was used to assess p53 and phosphorylated p53, apoptotic index (M30), proliferation index (MIB-1), apoptotic proteins bcl-2 and bax, inhibitors of apoptosis proteins Survivin and XIAP, checkpoint kinase 2 (ChK2), and p21^{waf-1}. The expression was correlated with tumour size, type, grade, and lymph node status and with the duration of survival.

P53 was detected in 38.5%, with phosphorylated p53 in 26.0%. P21^{waf-1} was in 25.0%, ChK2 in 69.2% and bcl-2 in 67.3% and all showed a significantly inverse relationship with p53. Survivin (67.6% cases positive) significantly correlated with the presence of p53 and high proliferation.

There was a relationship between the absence of phosphorylated p53, low proliferation and lack of Survivin with duration of survival greater than three years. These markers may aid in the selection of patients who would benefit from chemotherapy.

Signal transduction and cell cycle regulation by the breast myoepithelial cells

© JCA Lockett, JA Shaw, JL Jones, RA Walker

University of Leicester, Leicester, United Kingdom

Cellular cross talk is an important mechanism for the homeostatic control within tissues. The breast lobular compartment is made up of two main cell types, with a myoepithelial cells layer surrounding the luminal cells. This layer of cells is lost on the progression from DCIS to invasive breast cancer. To examine the role of myoepithelial cells in the control of tumour progression a non-contact tissue culture model has been developed. T47D breast cancer cells grown in either 2D and 3D Matrigel in the presence of myoepithelial cells have demonstrated a reduction in proliferation rate and an increase in apoptosis rate. This suggests a paracrine influence of the myoepithelial cells on the T47D cells. Aim: To dissect this paracrine mechanism by looking at key signalling cascades Pi3K/Akt and ERK pathways.

T47D cells were grown in myoepithelial conditioned media (myocm) for 6hr, 2 and 7 days in both 2D and 3D models. The effect of myocm on proliferation and apoptosis was confirmed for both time points and this corresponds to changes in phosphorylation status of ERK1/2 and pAKT. However no differences were found at 6 hrs suggesting an indirect effect on cell cycle regulation in the T47D cells.

Oestrogen Receptor Assays in Breast Cancer : Correlation Between Core Biopsies and Resection Specimens

© AD Graham, J Loane

Western General Hospital, Edinburgh, United Kingdom

Immunohistochemical oestrogen receptor (ER) assays were performed on the initial diagnostic core biopsy and the subsequent resection specimen in 86 consecutive cases of invasive breast cancer, 27 treated by mastectomy and 59 by wide local excision (WLE). ER expression was assessed, independently, by a consultant pathologist, using the Quick Score. This places each specimen into one of 4 prognostic categories – negative, weakly positive, moderately positive or strongly positive. These categories correlate well with response to anti-oestrogen chemotherapy. Categorisation was then compared, both in terms of 'exact' agreement (same category score for both core and resection specimen) and 'clinically relevant' agreement (ER positive or ER negative). The latter dictates whether anti-oestrogen chemotherapy is indicated.

Overall there was exact agreement between the core biopsy and the resection specimen in 68/86 cases (79%) and clinically relevant agreement in 79/86 cases (92%). The mastectomies showed slightly lower agreement than WLE specimens [exact agreement 20/27 vs 48/59 (74% vs 81%); clinically relevant agreement 24/27 vs 55/59 (89% vs 93%)].

This large study indicates that ER status in breast cancer can, in most cases, be accurately assessed on the initial diagnostic core biopsy. The small possibility of a 'false negative' result, however, suggests that, following a negative core, it may be prudent to repeat ER assessment on the resection specimen.

Id2 expression is inversely correlated with tumour grade in breast cancer

© JP Bury, SS Cross, S Balasubramanian, MW Reed, CE Lewis
University of Sheffield, Sheffield, United Kingdom

Id proteins are members of the basic-Helix-Loop-Helix (bHLH) family of transcription factors. The four known members of the family (Id1, Id2, Id3 and Id4) lack a DNA binding domain, and function as dominant negative regulators of DNA transcription by other bHLH transcription factors, with which they heterodimerise and thus inactive. Id2 expression has been shown to be required for the maintenance of a differentiated phenotype in breast epithelial cells. In this study we sought to compare levels of Id2 expression in breast tumours, as assessed immunohistochemically, with tumour grade. 3 triplicate tissue microarrays were created, each containing 170 1mm diameter cores, one from each of 170 breast cancers. These arrays were immunostained using a polyclonal antibody against Id2 (Santa Cruz sc-489). Specificity of staining was demonstrated using a specific peptide blocker, which blocked all staining. Each core was assigned a score of 0 or 1 on the basis of the presence or absence of Id2 staining. A composite score was calculated for each tumour by adding together the scores for tissue cores from the same tumour in each of the three microarrays. The mean total score was 1.81 for grade 1 tumours (n=36), 1.68 for grade 2 tumours (n=79) and 1.05 for grade 3 tumours (n=55). This decrease in Id2 expression with increasing tumour grade was statistically significant (p=0.005, Kruskal Wallis test). To our knowledge, this is the largest series of breast tumours in which Id2 expression has been correlated with tumour differentiation, and a clear association between tumour de-differentiation and loss of Id2 expression is demonstrated. Studies of the prognostic significance of Id2 expression in breast carcinoma may be valuable.

Audit Of C3 And C4 Breast Fine Needle Aspirate Cases With Histological Correlation

© I U Nicklaus-Wollenteit, N Singh, RJ Howitt
Southampton University Hospitals NHS Trust, Department of Cellular Pathology, Southampton, United Kingdom

All fine needle aspirates of the breast reported as C3 "atypia probably benign" or C4 "suspicious of malignancy" during 2002 in a large university teaching hospital department have been audited with regard to frequency and histological outcome. In total 982 cases were reported by one of four cytopathologists according to the NBSBSP guidelines for cytology.

74 cases (7.5%) were reported as C3 of which 61 proceeded to biopsy, and 42 cases (4.3%) were reported as C4 of which 41 had a histological diagnosis. 18 of the 61 C3 cases (29.5%) were malignant on subsequent histology: 4 low or intermediate grade DCIS; 11 grade 1 or 2 invasive carcinomas, including lobular, mucinous and adenoid cystic subtypes; and 3 invasive grade 3 carcinomas.

Of the 42 C4 cases 31 were confirmed as histologically malignant (73.8%): 25 grade 1 or 2 invasive carcinomas; 4 grade 3 invasive carcinomas; and 2 cases of pure DCIS. Fibroadenomas and epithelial hyperplasia accounted for a high proportion of benign lesions reported as C4.

Comparison with a previous study shows similar results. The C3 and C4 categories have distinct histological counterparts, and when used appropriately allow the classification of challenging cases into clinically distinct groups with different likelihood of malignancy.

Should random quadrant samples be taken when assessing a cancer mastectomy specimen?

© CDT Bratten, P Carder, S Lane, A Hanby
Leeds Teaching Hospitals NHS Trust, Leeds, United Kingdom

When assessing a mastectomy specimen, pathologists take great care to accurately locate and extensively sample all macroscopic or radiologically detected lesions. In addition, it is common practice to randomly sample each of the four quadrants.

The utility of so doing has only been studied once (Gupta-Dilip et al., 2003, *Breast J*, 9(4), 307-11). In this US study of 78 mastectomy specimens the authors concluded that random quadrant sampling added clinically useful information in a high proportion of cases (27%). The relatively high number of 'random' blocks taken (mean 9, range 2 to 19), and the high percentage of cases with positive quadrant findings, lead us to believe that this study might not be representative of our experience, where traditionally only two to four random blocks are taken and positive findings were thought to be less frequent.

Accordingly, we reviewed all mastectomy specimens over a two year period (2001-2002) received by our hospital. In total 388 reports were examined; in 47 cases (12%), random quadrant blocks were positive for malignant disease (17 in-situ disease, 22 invasive, 8 lymphovascular permeation). In all of these cases these features had been noted in the main tumour blocks. There was no association with invasive tumour type and positive quadrant findings.

However, there were 14 cases (3%) where the random findings were the only indication of disease potentially more widespread than the main tumour blocks (i.e. all nodes negative and lymphovascular invasion not seen). 10 of these cases identified further in-situ disease and 4 cases invasive disease in the random quadrants. Nevertheless, the clinical impact these extra findings had on patient management is debatable.

The Retrospective Reconstruction Of Prognosis In Breast Cancer: The Use Of The Nottingham Prognostic Index In The Medico-Legal Arena.

C Elston¹, M Blamey¹, © NA Wright²
¹ *Department of Histopathology, City Hospital, Nottingham, United Kingdom,* ² *Histopathology Unit, Cancer Research (UK), London, United Kingdom*

INTRODUCTION: The Nottingham Prognostic Index (NPI) is well-established in comparative use in clinical trials and for assessing prospective prognosis.

Here we assess both its application and success in the retrospective determination of prognosis in cases of litigation for delayed diagnosis of breast cancer. METHODS: the usual request is to reconstruct the prognosis of a case of breast cancer if diagnosis and treatment had occurred at some time previously, which varies between cases. The usually available data are (i) the diameter of the tumour at resection; (ii) the grade of the tumour at resection and (iii) the nodal status after axillary sampling or clearance. Using published data for the doubling time of breast carcinomas, the diameter of the tumour at the time in question can usually be calculated within confidence intervals.

Published data relating the size of the tumour to the probability of nodal metastases can be used to assess nodal status at this time for unit grade of tumour. The NPI can then be calculated for the time(s) of alleged misdiagnosis. RESULTS: In many cases, the dataset is sufficient to provide values for the NPI and thus survival probability, and in a considerable number of cases the NPI has been accepted by the Court since the index case of *Judge v Quick*, which we believe was the first to show causation in an alleged case of missed breast cancer. The success of this approach can be assessed now from a dataset which includes several hundred cases. Problems which have been encountered include cases where (a) the diameter of the diameter at diagnosis/excision cannot be assessed; (b) the nodal status is unknown and (c) where there are metachronous tumours. Areas where disputes in expert evidence arose included disagreements about the growth rate of breast carcinoma and the significance of the size of nodal and systemic metastases. CONCLUSION: the NPI has found an unlooked for niche within the medico-legal field which makes it very valuable so long as the assumptions and constraints implicit in the method are remembered.

Alterations in SEPT9 Gene Expression in Ovarian Epithelial Neoplasia: an Archival Tissue-Based Analysis

© M Scott, SEH Russell, PA Hall

Queen's University Belfast, Belfast, United Kingdom

Several lines of evidence indicate that the cytoskeletal septin gene SEPT9 may be involved in human neoplasia as a type II cancer gene where alterations in levels of expression are key. SEPT9 has a complex genomic architecture through alternative splicing. Information on the expression of SEPT9 in normal and neoplastic tissues is limited. We have therefore developed a semi-quantitative reverse transcription-PCR strategy to study SEPT9 expression in formalin-fixed paraffin-embedded tissue. Intron-spanning PCR primers produce small amplicons ranging from 61 to 88 base pairs. Laser microdissection allows identification of SEPT9 transcripts from <500 cells. We find that SEPT9 isoforms are ubiquitously expressed in a panel of normal adult human tissues. Cell culture studies in our laboratory have suggested that v4* expression is confined to neoplastic cells with downregulation of v4 in ovarian neoplasia. Having investigated SEPT9 expression in a panel of archival ovarian epithelial tumours, we find that all transcripts are qualitatively expressed. However, we observe a striking upregulation of the v1 and v4* transcripts in ovarian tumours with a subtle decrease in levels of other transcripts. We define SEPT9 as a ubiquitously expressed septin and show consistent alterations in the expression profile of ovarian epithelial tumours compared with normal ovaries.

An Immunohistochemical Analysis Of Ovarian Small Cell Carcinoma Of Hypercalcaemic Type

© WG McCluggage, E Oliva, LE Connolly, H McBride, RH Young

Royal Hospitals Trust, Belfast, United Kingdom

Ovarian small cell carcinoma of hypercalcaemic type (OSCCHT) is a rare neoplasm with an aggressive behaviour, broad differential and unknown histogenesis. 15 cases of OSCCHT were stained with a range of antibodies, some of which have not been investigated previously in this neoplasm. Cases were stained with AE1/3, EMA, BerEP4, CK5/6, calretinin, WT1, chromogranin, CD56, synaptophysin, CD99, NB84, desmin, S100, CD10, α inhibin, TTF1 and p53. All cases were positive with p53, 14 of 15 cases were positive with WT1, 14 of 15 with CD10, 13 of 15 with EMA, 11 of 15 with calretinin, 9 of 15 with AE1/3, 4 of 15 with CD56, 3 of 15 with BerEP4, 2 of 15 with synaptophysin and 1 of 15 with S100. All cases were negative with CK5/6, chromogranin, CD99, NB84, desmin, α inhibin and TTF1. OSCCHT is characteristically positive with AE1/3, EMA, CD10, calretinin, WT1 and p53. Combined EMA and WT1 positivity, the latter usually intense and diffuse, may be of diagnostic value, in as much as few of the neoplasms in the differential diagnosis are positive with both antibodies. The results of this investigation do not settle the issue of histogenesis which remains enigmatic.

Cytomegalovirus Infection Of The Cervix: Morphological Observations In Five Cases

© CE McGalíe, WG McCluggage

Dept of Pathology, Royal Group of Hospitals Trust, Belfast, United Kingdom

Histologically diagnosed cytomegalovirus (CMV) infection of the cervix is rare and the associated morphological features are not well described. We describe the histopathological findings in five biopsies from four patients with CMV cervicitis. CMV inclusions were identified in five cervical biopsies from four patients in a single institution over an 8 month period. The morphological features were documented and immunohistochemical staining for CMV performed. CMV immunohistochemical staining was also performed on 30 consecutive cervical biopsies in which inclusions were not seen histologically. None of the patients was immunocompromised but one was postnatal. The number of CMV inclusions ranged from occasional to abundant and they were located mainly in endocervical glandular epithelial cells but also in endothelial and mesenchymal cells. Inclusions were not seen in squamous cells. Inclusions were eosinophilic and were intracytoplasmic rather than intranuclear. They were positive immunohistochemically with CMV. Associated morphological features included fibrin thrombi within small blood vessels (3 cases), a dense active inflammatory infiltrate (5 cases), lymphoid follicles (2 cases), vacuolation of glandular epithelial cells (2 cases) and reactive changes in glandular epithelial cells (2 cases). CMV inclusions were not identified in the 30 additional cases which underwent immunohistochemical staining. CMV infection of the cervix may be more common than is generally appreciated. Patients are usually immunocompetent and require no treatment. Morphological features such as a dense inflammatory cell infiltrate with lymphoid follicles and especially fibrin thrombi within small vessels should alert the pathologist to look closely for the pathognomonic CMV inclusion bodies.

An Analysis Of Negative LLETZ (Large Loop Excision Of The Transformation Zone) Biopsies Over A One Year Period

© R Brannan, W Gregory, R Hutson, N Wilkinson

St James University Hospital, Leeds, United Kingdom

AIM: To analyse LLETZ biopsies in patients who have had either positive cytology or cervical biopsy to determine the proportion of cases that showed no CIN (cervical intraepithelial neoplasia) or invasive neoplasia at LLETZ (i.e. negative LLETZ).

METHODS: All LLETZ specimens received over a year period (1st June 2002-31st May 2003) were identified from computer records and the percentage of negative LLETZ biopsies determined. Cases were excluded if the LLETZ was a repeat procedure or if it was done on the basis of a clinical diagnosis in the presence of negative cytology or cervical biopsy.

RESULTS: 715 LLETZ biopsies were performed, of which 79 were excluded. 86 (14%) cases examined were negative. There were significant associations between negative histology and older age ($p < 0.05$), inadequate cytology ($p = 0.04$), inadequate biopsy ($p = 0.04$) and low-grade CIN at biopsy ($p = 0.01$).

CONCLUSION: The proportion of LLETZ biopsies showing negative histology in this institution exceeds that recommended by the National Health Service Cervical Screening Programme, which states that less than 10% should be negative. The identified factors that were significantly associated with negative histology may offer a means of reducing the number of negative LLETZ biopsies in the future.

A Study of Insitu Hybridisation for HPV in Women With High Grade HPV and Low Grade Smear With Clinical Progression or Regression

K Morris², B Fakokunde¹, S Glew¹, © J Pawade³

¹ St Michael's Hospital, Bristol, United Kingdom, ² University of Bristol, Bristol, United Kingdom, ³ Bristol Royal Infirmary, Bristol, United Kingdom

We have investigated for presence of high grade HPV by PCR and insitu hybridisation using a wide spectrum probe in women presenting with low grade smear abnormality and koilocytosis and or CIN1 in cervical biopsies and correlated the findings with clinical regression and progression.

Nine patients (progressors group) on HPV assessment had single HPV type in 3 (2 with HPV 16) and multiple in 6 (5 with HPV 16). The cervical punch biopsies showed positive insitu signal in all cases with punctate pattern in 6 and diffuse in 3. There was strong nuclear expression of P16 in 7 biopsies.

Ten patients (regressor group) had single HPV type (HPV 16) and 8 with multiple HPV (4 HPV 16 and 2 with HPV 18). Positive insitu signal was seen in 9 cases with a diffuse pattern in 7 and punctate in 2. There was positive staining for p16 in 4 cases.

Integration of HPV in the cells demonstrated by punctate signal by insitu and strong expression of p16 were features associated with clinical progression.

COMPARISON OF THE CONVENTIONAL CERVICAL CYTOLOGY SMEAR, LIQUID-BASED CYTOLOGY AND HC2 HIGH-RISK HPV DNA TEST USING UCM™-COLLECTED SPECIMENS IN CLINICAL PRACTICE

© N Bolger², L Pilkington², N Murphy¹, W Prendiville², JJ O'Leary¹

¹ Department of Pathology, Trinity College, Dublin, Ireland, ² The Coombe Women's Hospital, Dublin, Ireland

Digene's Universal Collection Medium (UCM) was developed to provide dual cytologic and direct HC2 DNA testing. The study sought to compare performance of UCM Pap cytology, conventional Pap smear, combination testing and HPV stand alone testing.

Each subject consented to a conventional Pap smear and a second sample collected with Digene's Cervical Sampler™ for the UCM Pap test and HPV test. The Digene brush sample was placed in 1 mL UCM. A 500 µl aliquot was processed according to the Shandon PapSpin™ protocol. The remaining 500 µl was processed by the HC2 method for HPV DNA detection. Both cytology slides were routinely stained and read in a blinded manner. Overall agreement between conventional and UCM Pap tests was 88%.

Compared to biopsy results, the cytologic sensitivity of conventional Pap smear and UCM Pap test for HSIL (CIN 2/3) was 32% and 35% respectively. HC2 HPV test alone detected 97% biopsy confirmed HSIL. The combination of conventional and/or UCM Pap cytology and HPV test resulted in 100% sensitivity for biopsy confirmed high-grade lesions and cervical cancer. The preliminary data support the use of UCM-collected cervical samples as a convenient method of combination LBC and HPV testing for cervical cancer screening.

Digene Corporation and Thermo Electron Corporation funded this study.

Cytokeratin Immunostaining Differentiates Endometrioid Carcinoma Of Ovary From Metastatic Colorectal Carcinoma

© M Jiménez-Liñán¹, L Happerfield¹, X Giannakouloupoulos², RAF Crawford², MJ Arends¹

¹ Department of Pathology, University of Cambridge, Cambridge, United Kingdom, ² Addenbrooke's Hospital, Cambridge, United Kingdom

Ovarian metastases from colorectal adenocarcinoma can sometimes histopathologically mimic primary ovarian carcinomas of endometrioid type. Distinction of endometrioid from colorectal cancer morphology is widely recognised as problematic on histological examination. However, it is important for therapeutic and prognostic reasons to differentiate between primary ovarian endometrioid carcinoma and metastatic colorectal adenocarcinoma. We examined a series of 14 cases originally reported as primary endometrioid carcinomas of ovarian to ascertain whether the site of origin could be determined by using immunohistochemistry for cytokeratin 7 and cytokeratin 20. Follow-up showed that of the 14 patients, 3 were subsequently shown to have colorectal carcinomas. Immunohistochemistry showed a cytokeratin 7+/cytokeratin 20- immunophenotype in 82% of the eleven primary ovarian endometrioid carcinomas; cytokeratin 7+/cytokeratin 20 focally positive pattern in 18% of the 11 primary ovarian endometrioid carcinomas; and cytokeratin 7-/cytokeratin 20+ immunophenotype in 100% of the three metastatic colorectal adenocarcinomas.

We conclude that the combination of cytokeratin 7 and cytokeratin 20 immunohistochemistry is very useful in distinguishing between metastatic colorectal adenocarcinoma and primary endometrioid carcinoma of ovary.

p16^{INK4A}, MCM5, CDC6 and High-Risk HPV status: A Screening Algorithm for Cervical Disease

© N Murphy¹, M Ring², M Griffin³, O Sheils³, JJ O'Leary¹

¹ Department of Pathology, Trinity College, Dublin, Ireland, ² Department of Pathology, The Coombe Women's Hospital, Dublin, Ireland, ³ Department of Histopathology, Dublin, Ireland

Increasing knowledge of the underlying pathogenesis of cervical cancer combined with advances in molecular testing herald the emergence of a "molecular age" in cervical cancer prevention. This new era promises the use of HPV testing and molecular biomarkers of cervical dysplasia. The objective of this study was to develop a screening algorithm which allows risk stratification of women on the basis of high-risk HPV DNA detection and the expression of p16^{INK4A}, MCM5 and CDC6 in squamous and glandular dysplastic cervical cells.

Generic HPV detection was carried out using a modified SYBR green assay system. Taqman PCR was employed for the detection of HPV 16, 18, 31 and 33 DNA. Immunohistochemical analysis using mouse monoclonal antibodies was employed to examine the protein expression pattern of p16^{INK4A}, MCM5 and CDC6 in normal cervical epithelium (n=20), CIN1 (n=38), CIN2 (n=33), CIN3 (n=46), cGIN (n=10), invasive squamous cell carcinomas (n=10) and adenocarcinomas (n=10) of the cervix. All samples were formalin fixed and paraffin embedded. Staining intensity was assessed using a 0 to 3 scoring system. In addition expression status was examined in 10 normal ThinPrep smears and 15 smears exhibiting mild, moderate or severe dyskaryosis. p16^{INK4A}, MCM5 and CDC6 mRNA expression was examined using quantitative TaqMan RT-PCR.

In this study p16^{INK4A} identified dysplastic squamous and glandular cervical lesions with a sensitivity of 99.9% and a specificity of 100%. MCM5 marked squamous and glandular dysplastic lesions with a sensitivity of 95% and a specificity of 100%. Quantitative TaqMan RT-PCR demonstrated an increase in MCM5 mRNA expression with increasing severity of dysplasia. CDC6 identified squamous and glandular dysplastic lesions of the cervix with a sensitivity of 70% and a specificity of 100% and was preferentially expressed in high-grade lesions and in invasive disease. TaqMan RT-PCR revealed an increase in CDC6 mRNA expression in dysplastic cells. The results of this study strongly indicate that the combined use of HPV DNA testing and MCM5, CDC6 and p16^{INK4A} detection methods can be employed to identify cervical neoplastic cells and can markedly increase the sensitivity and specificity of cervical cancer screening.

Human Papillomavirus DNA Vs mRNA: Clinical Indicators for the development of cervical neoplasia ?

© N Murphy¹, H Skomedal², M Oder Oye², P Gronn², IM Falang², O Sheils³, JJ O'Leary⁴

¹ Department of Pathology, The Coombe Women's Hospital and Trinity College, Dublin, Ireland, ² NorChip NS, Klokkestua, Norway, ³ Department of Pathology, St. James's Hospital and Trinity College, Dublin, Ireland, ⁴ Department of Pathology the Coombe Women's Hospital, St. James's Hospital and Trinity College, Dublin, Ireland

The persistent activity of HPV oncogenes E6 and E7 are necessary prerequisites for the development and progression of high-grade cervical lesions and cervical cancer. Testing for HPV oncogenic activity rather than the presence of HPV DNA may be a more relevant clinical indicator for the development of cervical lesions and cervical cancer. The aim of this study was to examine the correlation between HPV DNA detection and actual HPV oncogenic expression in the context of increasing severity of dyskaryosis. A second objective of this study was to examine the effect of co-infection of HPV types and oncogenic expression as to date the effect of multiple HPV infections and HPV type specific oncogenic expression remains unclear.

In this study HPV DNA and mRNA detection and typing was carried out for four of the high-risk HPV types most frequently associated with cervical cancer namely HPV 16, 18, 31 and 33. HPV analysis was performed on 10 normal ThinPrep samples and 30 ThinPrep samples exhibiting mild, moderate and severe dyskaryosis. TaqMan Real-Time PCR was employed for HPV DNA detection and typing. The PreTect HPV-Proofer (NorChip AS, Norway) molecular test kit, which is based on Real-Time NASBA technology, was employed for HPV mRNA detection. This study demonstrated that HPV oncogenic expression increased with increasing severity of dysplasia. Oncogenic activity was absent in up to half of cases demonstrating mild dyskaryosis. In addition this study demonstrated that the majority of HPV co-infection were composed of a single persistent transcriptionally active HPV type (typically HPV16) and a non-active potentially transient/silent HPV type. The results of this study indicate that the use of HPV mRNA detection may be a more clinically significant indicator of cervical dysplasia in both single and multiple HPV infections.

SEROUS CARCINOMA OF THE OVARY: A LINK BETWEEN RADIATION EXPOSURE AND RET/PTC-1 ACTIVATION?

© RJ Flavin¹, SP Finn¹, P Symth¹, M Ring², EM O'Regan¹, S Cahill¹, E Gaffney¹, JJ O'Leary¹, O Sheils¹

¹ St. James Hospital and Trinity College Medical School, Dublin, Ireland, ² Coombe Women's Hospital, Dublin, Ireland

RET/PTC is an activated form of c-ret, a proto-oncogene, which has been linked, with the development of papillary thyroid carcinoma. RET/PTC expression has not been looked at before in other papillary tumours despite similar morphology. Furthermore, increased risk of epithelial ovarian carcinoma has been described following diagnostic X-rays and radiation therapy to the pelvis, and ret rearrangements following radiation have been linked to papillary thyroid carcinoma.

Epithelial cells were laser capture microdissected from formalin-fixed, paraffin-embedded papillary tumours (N=31 included 18 cases of serous carcinoma of the ovary, 1 serous surface peritoneal carcinoma, 7 serous carcinoma of the endometrium, 3 renal cell carcinoma, and 2 urothelial cell carcinoma). Total RNA was extracted, and analyzed for expression of GAPDH and ret/PTC-1 using real time RT-TaqMan@PCR.

Ret/PTC-1 transcripts were detected in 2 of 10 serous surface ovarian carcinomas. Immunostains for TTF-1 and thyroglobulin were negative. One patient having a 20-year long history of renal stones had episodic KUB X-rays performed.

There may be a tenuous link between radiation with subsequent ret/PTC-1 activation and serous surface papillary carcinoma development.

Lack Of Interobserver Agreement In The Diagnosis Of Endometrial Cytological Atypia And Endometrial Hyperplasia

© MJ Staunton¹, PA Cross², JN Bulmer¹

¹ Department of Histopathology, Royal Victoria Infirmary, Newcastle upon Tyne, United Kingdom, ² Department of Histopathology, Queen Elizabeth Hospital, Gateshead, United Kingdom

Aim: Published criteria are available to diagnose endometrial hyperplasia, with or without cytological atypia (which have a different prognosis). We observed discord in this area, both locally and in the National Gynaecological Pathologist's External Quality Assurance scheme. This study was designed to assess the consistency of diagnosis of endometrial cytological atypia among a group of specialist gynaecological pathologists.

Methods: 15 pipelle biopsies were chosen to include a range of histological appearances from normal to adenocarcinoma. Nine pathologists independently assessed each case (5 Newcastle, 4 Gateshead). The results were compared between pathologists, with the original diagnosis and with outcome.

Results: Concordance was good at extremes of the spectrum from normal to malignant. There was an unexpected wide range of answers offered for hyperplasia (with or without atypia) and grade of atypia. Pathologists in one centre were no more likely to be concordant with colleagues in their own centre. The number of years of experience of individual pathologists did not influence the findings.

Conclusions: The literature suggests that by rigorously applying specific criteria, it is possible to reliably diagnose endometrial hyperplasia (with or without cytological atypia) and that patients can be offered different treatments on this basis. Our results challenge this assumption.

Development and Audit of a Risk Management System for the Histopathological Reporting of Melanocytic Lesions

© M Bamford, J Osborne, G Saldanha, A Fletcher

University Hospitals of Leicester NHS Trust, Leicester, United Kingdom

Introduction: The purpose of the MDT meeting is for clinical review and to allow standardised, co-ordinated clinical management of cancer cases. At the skin cancer MDT, current methods only identify melanomas for discussion. This paper develops a method to identify three additional groups of melanocytic lesions that would benefit from discussion.

Methods: The clinicians quantitated their impression of likelihood of melanoma. This was compared with the final histological diagnosis.

Clinicopathological discrepancies, naevi with high grade atypia and cases with histological diagnostic uncertainty were identified. An anonymous survey was administered to assess clinical management of atypical naevi.

Results: From 100 cases, 5 clinicopathological discrepancies, 6 naevi with high grade atypia and 0 cases of diagnostic uncertainty were identified. It was established that the clinical management of naevi with high grade atypia was not standardised.

Discussion: Identification of clinicopathologically discrepant cases allowed the possibility for histological error trapping. The questionnaire led to clearer understanding of the implications of a diagnosis of naevus with high grade atypia and the need for standardised treatment.

Conclusion: In addition to melanomas, the routine identification of certain carefully selected melanocytic cases for discussion allows the MDT to move closer to achieving its overall purpose.

Is There Agreement Between IMF-Diagnosed And Histologically-Diagnosed Immunobullous Skin Diseases At The University Hospitals Of Leicester NHS Trust?

© MA Ben-Gashir, G Saladanha, A Fletcher

¹ University Hospitals of Leicester NHS Trust, Leicester, United Kingdom.

² Department of Cancer Studies and Molecular Medicine - University of Leicester, Leicester, United Kingdom

Direct Immunofluorescence (DIMF) has a crucial role in diagnosing skin immunobullous diseases. At the University Hospitals Leicester (UHL) a skin biopsy is divided - one half is sent to histopathology for microscopic diagnosis and the other half sent to immunopathology for DIMF studies. An audit was carried, and the aim was to compare the reporting of histology and DIMF by different laboratories.

Using SNOMED we identified all cases coded as bullous pemphigoid, bulla, dermatitis herpetiformis, epidermolysis, erythema multiforme, pemphigus vulgaris, pemphigus foliaceus, and lupus erythematosus – between January 1998 and October 2003.

We were able to find complete data for 182 subjects. Complete histology and DIMF agreement was found in over 70% of cases. Discrepancies in the remaining cases were related to technical and interpretative issues. Full discussion and its implication for the service will be presented at the meeting.

The Impact Of National Minimum Datasets On The Reporting Of BCC And SCC In A University Hospital

© RF Flora, AF Fletcher, GS Saldhana

University Hospitals Of Leicester NHS Trust, Leicester, United Kingdom

Objective : To evaluate the compliance of histological reporting of BCC and SCC with the national minimum datasets before and after their introduction in 2002. The emphasis of the audit was on the description of skin tumours rather than the administrative features of the report.

Methods : 50 consecutive reports for SCC from 1998 and 2003 were analysed against the minimum datasets and the compliance for each pathological parameter, from either year was compared. This process was also repeated for 100 consecutive reports for BCC from 1998 and 2003.

Results : Following the introduction of the national minimum datasets there has been an improvement in recording of most of the parameters specified by the datasets for both SCC and BCC e.g. excision margins with measurements of clearance. However there remains a deficiency in the recording of other parameters, but there are cogent reasons for this e.g. Clarks level is very rarely stated in SCC reports, however it is implied by the pathologist stating the level within the dermis to which the tumour has penetrated.

Overall, the introduction of minimum datasets has led to an improvement in the reporting of key clinico-pathological parameters for both BCC and SCC.

Morphoform Sarcoidosis- An Enigmatic Dermatological Entity

© R Swamy, K M MacLaren, H Horn

Departments of Pathology & Dermatology, Royal Infirmary, Edinburgh, United Kingdom

We describe an unusual case of cutaneous sarcoidosis which clinically presented as localised scleroderma (morphoea).

The patient was an elderly lady in the sixth decade who presented to the Dermatology department with cutaneous plaques over both forearms of three months duration. The plaques were indurated with a violaceous border and were compatible with a clinical diagnosis of morphoea. Incisional biopsies revealed a non-caseating granulomatous reaction predominantly in the deep dermis and sub-cutis. Histologically, the granulomas were characteristic of sarcoidosis and showed intracellular asteroid bodies. There were no demonstrable acid-fast bacilli. The patient had no other clinical manifestations of sarcoidosis and the biopsy findings were regarded as being inconsistent with the clinical appearances. Because of the strong clinical impression of morphoea, repeat biopsies were performed three months later which again showed sarcoidosis. Following a medical literature search, the entity of morphoform sarcoidosis was discovered which was best suited to describe this unusual presentation of cutaneous sarcoidosis.

This case demonstrates that a discrepancy between the clinical presentation and histological features in skin disease has significant implications on patient management and requires close clinico-pathological correlation.

Clear Cell Sarcoma – A Case Report

© D Faratian¹, K M McLaren²

¹ Royal Infirmary of Edinburgh, Edinburgh, United Kingdom, ² University of Edinburgh Division of Pathology, Edinburgh, United Kingdom

Clear cell sarcoma (CCS, melanoma of the soft parts) is a rare and unusual malignancy that usually affects adolescents and young adults. It shares clinical and histological features of both melanoma and soft tissue sarcoma, and as such provides challenges in diagnosis and treatment to both the clinician and pathologist. In order to demonstrate the pitfalls that may be encountered, we present a case of CCS that had metastasised to a regional lymph node seventeen years after excision of the primary lesion. We discuss the clinicopathological features, including diagnostic immunohistochemistry and electron microscopy, of the primary tumour, the metastasis and the fine needle aspirate. Since the tumour is also characterised by a distinct chromosomal fusion product, the EWS/ATF1 oncogene, we discuss our experiences with diagnostic cytogenetics on paraffin-embedded tissue and the applicability of cytogenetics and molecular profiling to routine clinical practice.

The Prognostic Significance Of The Pattern Of Invasive Front In Malignant Melanomas

© I Roxanis, J Chow

St George's Hospital Medical School, London, United Kingdom

Malignant melanomas have a high metastatic potential. Although Breslow thickness is the single most important prognostic factor, it is common in clinical practice to encounter cases that challenge this correlation.

In order to identify additional histological parameters with prognostic significance we studied the pattern of invasive front in all primary cutaneous melanomas in vertical growth phase with tumour thickness >0.76mm diagnosed in our Department between 1990-1995. Follow-up was up to 12 years. We employed an invasive front grading score (0-3) based on the histological characteristics of the tumour-host interface. Score 0 corresponded to a 'pushing' pattern of invasion and score 3 to a predominantly infiltrative pattern. We found a lack of correlation between pattern of invasion and Breslow thickness. However, comparison of the Kaplan-Meier survival curves showed a significant difference in the disease-free survival between cases with scores 0-2 and those with score 3 ($p < 0.001$, logrank test).

We previously showed that melanoma cell dyscohesion was correlated with the likelihood of metastasis. It is possible that variations in the pattern of invasion (including both dyscohesion and invasive front) reflect differences in the adhesion molecule phenotype in melanoma cell subpopulations. We are currently studying the distribution of cadherins in these patients.

Chest Wall Injuries At Autopsy Following Cardiopulmonary Resuscitation

© C J Black¹, A Busuttill², C Robertson³

¹ *Department of Pathology, Royal Infirmary of Edinburgh, Edinburgh, United Kingdom,* ² *Forensic Medicine Section, Department of Pathology, The University of Edinburgh, Edinburgh, United Kingdom,* ³ *Department of Accident and Emergency Medicine, Royal Infirmary of Edinburgh, Edinburgh, United Kingdom*

The forensic records were reviewed of 1823 deaths referred to Edinburgh City Mortuary for autopsy over a 15 month period, 2000-2001; 499 cases (343 male, 156 female) that received CPR prior to death were studied.

Rib fractures were found in 29%, sternal fracture in 14% and 11% of cases showed external chest wall bruising. More females sustained rib fractures than males (37% vs 26%; $P < 0.05$). There was no significant gender difference for sternal fracture (females 17%, males 12%; $P = 0.051$). The incidence of rib fractures increased with age ($P < 0.001$). There was no significant difference in the number of left or right ribs fractured ($P = 0.631$).

This study incorporates all cases of in and out-of-hospital CPR and does not discriminate for the CPR provider or technique employed, therefore providing a current and representative overview of the incidence of rib and sternal fractures in the general population.

This study was funded by The Resuscitation Council, UK.

Angiogenesis and Prognosis in Human Melanoma: PAR-1 Expression the Best Marker of Tumour Progression from the Coagulation Components Studied

WD Thompson², © I Depasquale¹

¹ *Department of Plastic Surgery, Aberdeen Royal Infirmary, Aberdeen, United Kingdom,* ² *Department of Pathology, Aberdeen Royal Infirmary, Aberdeen, United Kingdom*

The presence of fibrin makes malignant melanoma unusual amongst cancers. The relevance of this to tumour growth, spread and angiogenesis is unknown. Immunostaining for tissue factor (TF) fibrin, and PAR-1 thrombin receptor in 204 cases of melanoma was performed, and intensity of expression scored, and Chalkley microvessel counts (MVD) obtained for the tumour edge.

TF expression and presence of fibrin correlated well with Breslow thickness and ulceration, reaching statistical significance, but surprisingly not for metastatic recurrence. Fibrin was variably present in over half the cases, located at the invasive edge, ulcerated surface, between tumour cell surfaces, and in a few cases within tumour cells, typically co-located with melanin, confirmed by electron microscopy. In contrast, staining for PAR-1 produced statistically significant results, correlating expression with Breslow ($p = < 0.001$), ulceration ($p = 0.001$) and recurrence ($p = < 0.005$).

Both MVD and PAR-1 can be used as adjuncts to Breslow thickness and ulceration as prognostic indicators for melanoma as they appear to give independent information for all thicknesses. PAR-1 expression is the best antibody marker of recurrence risk from the candidates studied.

Septic Shock With Massive Haemolysis And Abdominal Malignancy – A Case Presentation

© S Haider, Z Choudhary, M Lesna

Royal Bournemouth Hospital, Bournemouth, United Kingdom

Clostridial sepsis is a rare condition most often associated with intravenous drug addiction, post abortion, wound and intra-abdominal infections. Only rarely does clostridial infection develop in a patient with carcinoma as demonstrated by a large autopsy series by Cabrera et al, in which only 21 of 4145 with various malignant lesions were found to have clostridial infections. Despite its rarity awareness of clostridial bacteraemia is important since it can result in massive haemolysis and toxic shock. Mortality is in the range of 50-70%. The outcome is determined by the interaction of different variables but prompt recognition and treatment are important.

A 62 year old woman presented with collapse and was clinically found to be in shock. She had previous history of endometrial adenocarcinoma treated by hysterectomy, bilateral salpingo-oophorectomy and pelvic radiotherapy. She died soon after admission. Autopsy showed necrotic tumour in the colon and the mesentery and the features of clostridial septicaemia. Results of blood culture were positive for *Clostridium perfringens* but became available after the patient's death.

This case highlights the association between clostridial infection and underlying abdominal malignancy.

Recruiting Donors for Autopsy-based Cancer Research in Uveal Melanoma

J Thombs¹, NJ Borthwick³, JL Hungerford¹, © IA Cree²
¹ Ocular Oncology Service, Moorfields Eye Hospital, London, United Kingdom, ² Translational Oncology Research Centre, Portsmouth, United Kingdom, ³ Institute of Ophthalmology, UCL, London, United Kingdom

The use of human tissue for scientific research is a sensitive issue, but nevertheless, access to human tissue is essential for clinical research. It is important that appropriate, effective procedures are used to recruit patients for tissue donation.

We set up a prospective post-mortem research study to investigate latency of metastatic cells in uveal melanoma. Uveal melanoma provides an ideal model of haematogenous metastasis, as it does not have access to lymphatics. Furthermore, it commonly exhibits latency: the poorly understood process by which tumour cells may remain dormant for years before becoming clinically detectable. This latency may be due to tumour cell quiescence, lack of angiogenesis, or anti-tumour immunity. The project uses RT-PCR and immunohistochemistry to investigate each of the above models. Our consent procedure involves experienced oncology nurses who interview patients prior to signature of the consent form by the patient and their next of kin. To date we have approached a total of 105 patients, only 11 of whom have refused consent. This 89% take-up rate compares favourably with many clinical trials of treatment. Comparison of the results between those who die of metastasis and those in whom micrometastases are detected should allow us to determine which of these models is the most important, or whether there is significant variation between patients.

Clusterin acts as a protective mediator in cardiomyocytes

© PAJ Krijnen¹, SAGM Cillessen¹, R Manoe², CE Hack², LA Aarden², JWM Niessen²

¹ VU Medical Center, Dpt Pathology, Amsterdam, Netherlands, ² Sanquin Research at CLB, Dpt Immunopathology and Laboratory of Experimental and Clinical Immunology, AMC, Amsterdam, Netherlands

BACKGROUND Clusterin (Apolipoprotein J), a highly conserved and heavily glycosylated disulfide-linked heterodimer, was shown to co-localize with complement on jeopardized human cardiomyocytes after infarction.

Furthermore, it is known that clusterin can protect cells by inhibiting complement. In this study we examined clusterin in the human heart and in rat neonatal cardiomyoblast cells (H9c2), as a model of AMI.

METHODS We examined the distribution of clusterin and complement factor C3d in the human heart after AMI. We analysed protein expression of clusterin in ischemic H9c2 cells. The binding of purified human clusterin on H9c2 cells was analyzed by Flow Cytometry. Morphological analysis was used to examine the effect of clusterin on ischemic H9c2 cells.

RESULTS Clusterin was found on scattered morphologically viable, complement negative cardiomyocytes within the infarcted area. In H9c2 cells, clusterin was rapidly expressed after ischemia, but decreased rapidly after reperfusion. Clusterin only bound to Annexin-V and/or PI positive H9c2 cells. Morphological analysis showed that clusterin inhibited the damaging effect of ischemia on H9c2 cells in the absence of complement.

CONCLUSIONS We conclude that ischemia induces up-regulation of clusterin on ischaemically challenged but partly still viable cardiomyocytes, and subsequently protects against cell death, via a complement independent pathway.

1911 & 2002: A Comparative Study of Causes of Death Recorded at Autopsy

© R BouHaidar, ME Mathers

Department of Cellular Pathology, Royal Victoria Infirmary, Queen Victoria Road, Newcastle upon Tyne, United Kingdom

Identification of an accurate cause of death is one of the most important functions of the autopsy. Epidemiological studies show that causes of human morbidity and mortality have evolved in line with changes in socio-economic conditions. We conducted a comparison study of causes of death recorded in our centre following autopsy examination in 1911 and 2002.

Data for the 1911 cohort was retrieved from a hand-written ledger, whilst the 2002 data was retrieved from the departmental computer system and typewritten paper reports. 371 autopsy reports were available from 1911. 1123 autopsy examinations were carried out in 2002, including consented and coronial cases.

The most frequent causes of death recorded in 1911 were peritonitis, pneumonia, tuberculosis, meningitis and sepsis. Some unusual historical terminology was identified in this cohort, such as marasmus and epulis. There were cases of syphilis, diphtheria and tetanus; infectious diseases which have all but disappeared in Western populations. The 2002 profile was different, with the most frequent causes of death being ischaemic heart disease, pulmonary embolus, ruptured aortic aneurysm and pneumonia. This study provides an interesting insight into the evolution of human pathology, highlighting the decreased incidence of fatal infectious disease and the emergence of atherosclerosis as a major cause of mortality in contemporary society.

The Diagnostic Yield of Image Guided Versus Abrams Pleural Biopsies

© KA Scott, C Richards, S Muller

Universities of Hospital Leicester NHS Trust, Leicester, United Kingdom

Background: Pleural biopsies and cytology are standard procedures for the investigation of pleural disease and effusions. Recent medical literature has suggested improved sensitivity for the diagnosis of malignant pleural disease with CT guided pleural biopsies, compared to the more common Abrams' biopsies, which are performed without imaging. Abrams' biopsies are often less accurate in sampling pleura, leading to an increased number of secondary invasive investigative procedures.

Methods: We re-examined all image guided (CT and US) and Abrams' pleural biopsies over a two-year period, and compared the inadequate biopsy rate for both. All final diagnostic information about patients was obtained from the respiratory MDT database and patient notes. We were therefore able to calculate the sensitivity and specificity for the diagnosis of malignant pleural disease for each type of biopsy.

Results: Only 5.5% (n=37) of image-guided biopsies were inadequate, compared to 49.6% (n= 117) of Abrams' biopsies. The sensitivity of image guided pleural biopsies was higher (95%) compared to Abrams' pleural biopsies (35%) in diagnosing malignant pleural disease.

Conclusions: Image guided pleural biopsies yield a higher rate of positive malignant diagnoses, result in fewer inadequate biopsies and consequently reduce the need for secondary invasive diagnostic procedures compared to Abrams' biopsies.

Cardiomyopathy and Intravascular Involvement of Gut in Systemic Senile Amyloidosis

© S Haider¹, M Lesna¹, PJ Gallagher²

¹ Royal Bournemouth Hospital, Bournemouth, United Kingdom, ² Southampton University Hospital, Southampton, United Kingdom

In 1956 Symmers reported that the gastrointestinal tract was involved in 70% of cases of primary amyloidosis. Since that time it has been infrequently mentioned in the literature.

Cardiac amyloidosis is rare and presents as a restrictive cardiomyopathy or low output cardiac failure. Despite the advances in cardiac imaging techniques, tissue diagnosis usually requires an endomyocardial biopsy.

We have analysed the data from 9 cases of systemic amyloidosis collected over a period of 10 years; 6/9 had an autopsy, 3/9 were diagnosed histochemically in biopsy samples. The age of the patients varied from 74 to 97 years, all but one were males.

Our study has shown a frequent association of cardiac amyloidosis with intravascular amyloid in the sub mucosal arterioles and venules of the gut, particularly of stomach. In the heart the amyloid was deposited in the basement membrane of the myocardial cells and media of the arterioles. There were similar intravascular deposits in the medium sized blood vessels of lungs and kidneys but the glomeruli were spared.

We propose that in certain cases of restrictive cardiomyopathy, endomyocardial biopsy could be replaced by less demanding gastric biopsy if amyloidosis is considered to be a cause.

An Investigation Into The Relationship Between Sudden Unexpected Cardiac Death And Lung Weight

© E Beeson, R. E Owers, P. J Gallagher, M Walker

Pathology Department, Southampton University Hospitals Trust, Southampton, United Kingdom

Sudden unexpected cardiac death (SUCD) is an important cause of mortality in developed countries with a frequency of 10.5-13 per 100,000 populations per annum in the UK. At post mortem pulmonary oedema is found in many, though not all, cases of SUCD. In this study we have investigated the relationship between pulmonary oedema and demographic, clinical and pathological findings. Our particular objective was to relate pulmonary oedema to the degree of certainty of cardiac death.

Data was taken from observed autopsies and past autopsy records of 990 Southampton cases over a 38 month period. Each cardiac death was classified into one of five categories. For example definite cardiac deaths (certainty grade 1) had fresh myocardial infarction or recent coronary thrombosis whilst sudden arrhythmic death syndrome cases (SADS, grade 5) had no cardiac abnormalities. Up to 14 other variables were recorded and compared with lung weight using Minitab.

There was no relationship between lung weight and the degree of certainty of cardiac death. In particular there was no evidence that lung weight was higher in patients with definite evidence of infarction or thrombosis. Lung weights were higher in males. Heart weights were higher in patients with a history of previous infarction or hypertension and in patients taking diuretics, ACE inhibitors, aspirin and statins but this did not apply to beta blockers or calcium channel blocking agents.

This study has not added significantly to our understanding of cardiogenic pulmonary oedema at post mortem. We believe that we have studied adequate numbers of cases and that our data base is sound. The cause of post mortem pulmonary oedema is largely unexplained.

ATRIAL MORPHOLOGY DOES NOT PREDICT THE ONSET OF POSTOPERATIVE ATRIAL FIBRILLATION

© RJ Flavin, B Foley, J Cosgrave, D.S. O'Briain, E Fitzpatrick, K Bennett, E McGovern, M Tolan, V Young, P Crean, M Walsh
St.James's Hospital and Trinity College Medical School, Dublin, Ireland

Atrial fibrillation remains the commonest complication of cardiac surgery. Prophylactic therapies have been studied but their utility has been limited by the inability to accurately identify patients who will develop this complication. Recent studies have suggested that atrial myolysis or lipofuscin pigmentation predict atrial fibrillation.

To determine whether there is an association between pre-operative atrial morphology and subsequent post coronary artery bypass surgery (CABG) atrial fibrillation, samples of right atrial appendage were obtained from 94 patients undergoing CABG. Tissue was formalin fixed and paraffin embedded. Four µm sections were cut and stained with H&E. Sections were examined for the following parameters: fibrosis, myolysis, inflammation, nuclear size, pericardial exudates, lipofuscin pigment, arteriolar hypertrophy, contraction banding, mesothelial hyperplasia and atrial diverticulae. Results were graded into absent, mild, moderate or severe. Slides were reviewed by two independent observers who were blinded to the clinical outcomes. Univariate and multivariate analysis were carried out.

39% of the patients developed atrial fibrillation. No correlation was found between the 10 features assessed including myolysis and lipofuscin pigmentation and the development of atrial fibrillation.

In conclusion, conventional microscopy provides no evidence of a morphological basis in the right atrial appendage for post-operative atrial fibrillation.

Sudden Maternal Death Due To Cardiovascular Causes

© GC Behrendt¹, AG Nicholson¹, SB Lucas², MN Sheppard¹

¹ Royal Brompton Hospital, London, United Kingdom, ² St Thomas Hospital, London, United Kingdom

Introduction: Between 89-126 cases of maternal deaths occur each year in the UK and there has been criticism of autopsy reports in these deaths¹. Obvious causes linked to pregnancy are common but the hemodynamic changes associated with pregnancy may worsen pre-existing cardiovascular disorders, which may or may not be established before autopsy. Pathologists need to be aware of these.

Material We examined cardiovascular causes of maternal deaths in our files referred to our hospital between 1995 and 2003. 14 cases were identified and slides and reports reviewed. Additional clinical information was requested where necessary.

Results: The following causes of death were found: Eisenmengers syndrome due to (operated) congenital heart disease (4), thrombotic microangiopathies (3), idiopathic myocardial fibrosis (1), peripartum cardiomyopathy (1), sudden adult death (1), floppy mitral valve (1), pulmonary arterio-venous malformation (1), coronary artery dissection (1) and chronic recurrent thromboembolic disease (1).

Discussion: A variety of common and rare cardiovascular disorders can cause death in pregnancy or post-partum. Detailed examination of heart and lungs including histology is necessary as some cases show subtle pathologic changes.

Reference List

1. Why Mothers Die? 1997-1999 Confidential Enquiry into Maternal Deaths in the United Kingdom. Royal College of Obstetricians and Gynaecologists Press London 2001. p27-45.

101

Workload Implications of Case Review; an Audit of the Review Process in a Specialist Paediatric Histopathology Unit

© N J Sebire, M Malone, V V Smith, A D Ramsay
Histopathology Department, Great Ormond Street Hospital, London, United Kingdom

Although few histopathology departments in the UK formally double report cases, an increasing percentage of surgical specimens are reviewed at the request of the clinicians. An audit was performed to determine the extent and nature of these reviews in a specialist paediatric department. Over a four-month period we recorded all instances where clinical contact led to a review of a previously reported case. The setting of the review, the clinical team involved, the pathologist time incurred and any reasons given for review were all noted.

A total of 509 cases were reviewed in the audit period; this represented 48.9% of the surgical workload. The majority of the reviews (440 cases, 86.4%) were carried out in the setting of a multi-disciplinary team meeting. 49 reviews (9.6%) took place at a multi-headed microscope within the department. 17 cases (3.4%) were reviewed following a telephone contact and 3 cases (0.6%) of reviews followed a letter or e-mail message.

53 cases (10.4%) were reviewed on more than one occasion. The majority of reviews (448 cases, 88%) involved one Consultant Pathologist. Two Consultants were present at 13 reviews (2.6%); an SpR was present at 323 reviews (64%). The total Consultant Pathologist time required was 54.2hrs, which extrapolates to 162.6 hours/year (~ 20 working days).

Reasons for review included "to see the slides", to determine the "certainty" of the pathological diagnosis, a requirement for "more information", requests for special stains or investigations and to ask about a specific diagnosis not mentioned on the original request form. We conclude that the review of reported cases is a major component of our workload.

103

Too Many 'Suspicious' Prostatic Biopsies? The Outcome Of Prostatic Biopsies Initially Reported 'Suspicious' Over 5 Years

© M F Hickling, L D'Souza, S R Rasbridge
Royal Bournemouth Hospital, Bournemouth, United Kingdom

Our department received prostatic biopsies from 3925 men between 1998-2003; 2929 (74.6%) followed trans-rectal ultrasound (TRUS) whilst 996 (25.4%) followed digital rectal examination (DRE) for investigation of prostatic adenocarcinoma.

3388 (86.3%) had 1 set of biopsies, whilst only 36 (0.92%) ended up having more than 3 sets. The prostatic adenocarcinoma detection rate in initial biopsies was 1789 (45.6%) overall. The number of biopsies reported as malignant was greater and as suspicious was lower for DRE than for TRUS in both first and second biopsy sets.

In 537 cases having further biopsies, 152 (28.3%) had an eventual diagnosis of adenocarcinoma whilst only 3 (0.56%) remained suspicious. Each biopsy set demonstrated a constant rate of adenocarcinoma (30%) and suspicious (16%) cases. 32 biopsies were sent for independent review; this agreed with our diagnosis in 11 biopsies but upgraded 20 biopsies from strongly suspicious to adenocarcinoma. 1 biopsy was downgraded from suspicious to benign. This demonstrates our department has a good rate of adenocarcinoma diagnosis and produces an acceptable number of suspicious biopsies compared to published data. Multiple biopsy sets appear helpful but the high proportion of suspicious biopsies called adenocarcinoma on expert review should be addressed.

102

A Study Of The Reporting Times Of Bronchial Biopsies And Primary Lung Malignancy Resection Specimens

© EE Carling
The General Infirmary at Leeds, Leeds, United Kingdom

The reporting time for bronchial biopsies and primary lung malignancy resection specimens was studied over a nine month period within one department of histopathology. The mean reporting time for a bronchial biopsy was 7 days, with 95% of specimens being reported within 14 days. Current guidelines suggest all such specimens should be reported within two weeks. There was variation of reporting time with diagnosis and reporting pathologist.

The mean time between the issuing of a diagnostic biopsy report, and receipt of a primary lung malignancy resection specimen was 54 days (range 10 to 120 days), indicating that the time taken to produce a biopsy report is not a significant contributor to the length of time between tissue diagnosis and the surgical treatment of primary lung malignancy. The length of time between tissue diagnosis and surgical treatment of lung malignancy is not currently assessed as an NHS Cancer Plan waiting time target.

104

Audit of Adequacy and Accuracy of SNOMED Diagnostic Coding

PM Yarrow², © DK Worrall², HM Gilmour¹, HM Kamel¹
¹ *University of Edinburgh, Edinburgh, United Kingdom,* ² *Royal Infirmary of Edinburgh, Edinburgh, United Kingdom*

Pathology departments spend considerable time and effort applying diagnostic codes to reports. The most commonly used system is the SNOMED system. SNOMED coding is important to enable retrieval of past cases by diagnosis for the purposes of review, audit and research. For this reason accurate and adequate diagnostic codes for all reports are essential.

We reviewed the diagnostic (SNOMED) codes of 1500 consecutive reports within our department (6% of annual workload) to assess the accuracy of coding and to identify problems within the coding system and potential sources of error. Both Topography and Morphology codes were assessed.

Of the reports assessed 7% contained errors in coding or inadequate coding. Inconsistencies of coding were identified in cases with more than one diagnosis and cases submitted in multiple parts. Adequacy of topography coding was variable.

Recommendations and possible approaches for improving the accuracy and adequacy of coding are made. These include subspecialty specific coding manuals for departments with subspecialty reporting, linking of codes to synoptic reports, proper and formal training of new medical and secretarial staff in coding methods during their induction period and the establishment of a SNOMED monitoring group.

Obtaining Tissue Consent, Who Should Do It? A Comparison Of Health Professionals Obtaining Tissue Consent For Identical Procedures.

© J M Wheeler¹, M Bladon¹, P Quirke²

¹ Leeds Teaching Hospitals NHS Trusts, Leeds, United Kingdom, ² LTH NHS Trust & Academic Unit of Pathology University of Leeds, Leeds, United Kingdom

We examined the pattern of tissue consent taking for gastroenterological and gynaecological procedures consented routinely by either nurses or doctors. As part of a wider audit of our Trust's surgical consent forms, 600 were audited for tissue consent taking. 275 were consented by nurses, the remainder by doctors. 94% of nurses completed the tissue section, 36% of SHOs, 58% of SpRs, 50% of consultants and 52% of other grades. Figures for tissue consent sections left entirely blank were 1.5% by nurses, compared to 58% by SHOs and between 33 and 38 % by all other clinicians.

Conclusion: Wide variation is seen in success rates for completion of forms, with nurses out performing doctors. Nurses in our Trust receive specific training related to the consent form. This may account for their high completion rates. Introduction of such forms without an associated training programme is likely to fail.

Audit of Colorectal Adenocarcinoma Specimens with Reference to Lymph Node Yield and its Potential Significance

© V S Howarth, R J Hale

Department of Histopathology, Stepping Hill Hospital, Stockport, United Kingdom

Aims: This retrospective audit looked at 311 colorectal carcinoma resection specimens from our department over a three year period. This is a baseline audit using our standard formalin fixation time of 24-48 hours.

Methods: Inclusion criteria were that the specimen had been reported on our colorectal carcinoma minimum dataset protocol reporting form. The parameters examined were age, sex, site of tumour, length of specimen, diameter of the tumour, tumour differentiation, number of lymph nodes found, number of positive lymph nodes, presence or absence of extramural lymphovascular space invasion, rectal high tie node status, Dukes and TNM staging, and doctor performing the dissection.

Results: The mean number of nodes found per case was 10. Most cases were Dukes B (42.4%), followed by Dukes C (37%) and 'D' (17%). The more lymph nodes that were found, the more likely that positive nodes would be found ($p < 0.05$). There was a positive correlation ($p < 0.05$) between the increasing diameter of the tumour and also tumour site, and the total number of nodes found, but not between positive nodes. The more poorly differentiated the tumour, the more positive nodes that were found ($p < 0.05$) and in rectal tumours the more nodes involved, the more likely the high tie node was to be involved. The number of nodes found was dependent on the prosector ($p < 0.05$). There was no correlation between the total number of nodes or positive nodes found, with age, sex or specimen length.

Conclusions: This audit proves the importance of maximising lymph node yield to accurately stage specimens. We intend to increase our formalin fixation time to 72 hours to see if this will increase our lymph node yield and re-audit.

Gastrointestinal Biopsies Of Limited Or No Clinical Value Within A Large Teaching Hospital

© A Jeffery, M Holbrook, A McGregor, C Richards
University Hospitals of Leicester, Leicester, United Kingdom

Background/Aims:

Following concerns regarding workload demands in Histopathology, The Royal College of Pathologists published a document in August of 2002 titled 'Histopathology of Limited or No Clinical Value'. This identified histological investigations which make minimal contribution to patient management. The aim of this audit was to assess the appropriateness of G.I. biopsy histology requests made within a large UK teaching hospital, 2 years following the publication.

Methods:

Information regarding clinical details, endoscopic appearances, number and site of biopsies was collated from biopsy request forms over a 2 month period. They were then categorised as inappropriate, appropriate or borderline using advice from the Royal College document and consensus specialist consultant opinion.

Results:

Over the two month period, 526 upper and 454 lower gastrointestinal biopsies were processed and examined. 32% of the upper and 21% of the lower G.I. biopsies were found to be inappropriate.

Outcomes:

Gastric biopsies were a particular problem area with 37% of gastric biopsies classified as inappropriate. Reasons for such classification, included the biopsy of normal mucosa and biopsies for erythema and reflux. Continuing education of clinicians and interdisciplinary communication is required to limit the number of inappropriate histology requests.

Implementation Of A Comprehensive Pathology Laboratory Information Management System; One Year Later

© GA Meijer, JAM Belien, BME von Blomberg, AH van Hattum, F van Kemenade, CJLM Meijer
VU University Medical Center, Amsterdam, Netherlands

Although at a slower pace than in e.g. clinical chemistry, automation and information technology are finding their way into the surgical-and cytopathology laboratory, ranging from programmable tissue processors in the lab to speech recognition and digital microscope cameras at the pathologists desk. There also is an increasing need for detailed management information and workflow analysis. We have implemented one year ago a comprehensive pathology laboratory information management system that can cope with all these different aspects. After a system analysis (input: samples and request forms, output: reports, slides, blocks, and photographic material) and workflow analysis (complex) of the department, functional requirements were specified, and after extensive evaluation ultimately the program Sympathy (Informationslogik, Malmö, Sweden) was chosen, and its implementation was prepared over a period of about six months. Major issues were data conversion and connections to other hospital information systems. After one year most goals have been achieved, downtime has been limited in frequency and duration and no major disruptions of the primary process have occurred. Benefits are emerging, acceptance is high, although some problems still remain. The system has contributed to improved quality management within the department.

Proposal for a Peer Standardised Assessment Scheme in Histopathology

© D F R Griffiths¹, S Dojcinov²

¹ Dept of Pathology, University of Wales College of Medicine., Cardiff, United Kingdom, ² Dept of Histopathology, Cardiff and Vale NHS Trust, Cardiff, United Kingdom

External Quality Analysis schemes are an established part of professional development in histopathology. However the current RCPATH model, on which many schemes are based, has several problems including the difficulty in using small biopsy material, ensuring the uniformity of material, differing pathologist repertoires and the objectiveness of the marking. We here propose a scheme that avoids many of these problems.

Briefly, the scheme composes and publishes a list of diagnoses of conditions that can be diagnosed histologically with reasonable confidence and builds and maintains a bank of cases each consisting of a history and a slide and with an agreed diagnosis.

For each assignment a participant receives a package of cases selected according to a declared repertoire and the participants previous scoring history. The participant is expected to assign a diagnosis to each case by entering a code on an answer sheet. Each response can then be marked immediately as agreeing, if matching the agreed diagnosis, or divergent. Feedback can be given immediately and appropriate educational material offered in the event of a divergent response. Cases can be considered inappropriate if significant numbers of participants' responses are divergent. The objective responses allow formal statistical assessment of suitability of cases and the performance of participants.

Opposite Inverse Correlations of Proliferation and Apoptosis Segregate Benign from Malignant Follicular Thyroid Neoplasms

J Patel¹, A Blanes², © SJ Diaz-Cano³

¹ Barts and The London NHS Trust, London, United Kingdom, ² University of Malaga School of Medicine, Malaga, Spain, ³ King's College Hospital, London, United Kingdom

The kinetic differences (proliferation and apoptosis) by topographic compartments in follicular thyroid (FT) lesions have not been studied to date.

We selected 82 FT lesions (9 hyperplastic nodules, 22 adenomas, 14 minimally-invasive carcinomas, 24 widely-invasive carcinomas and 13 anaplastic carcinomas, classified according to AFIP criteria). Representative samples were selected for Ki-67 immunostaining and In situ end labeling (ISEL) of DNA fragments (using Klenow fragment of DNA polymerase I), running appropriate controls in each sample. The Ki-67/ISEL index was analyzed by topographic compartments (1-mm peripheral vs. internal), and the results compared using analysis of variance and Student *t*-test (significant if $P < 0.05$).

Internal compartments of benign lesions and peripheral compartments of carcinomas revealed the predominant kinetic advantage (Ki67/ISEL index, Table).

	Internal (Av±SD, %)	Peripheral (Av±SD, %)
Nodules	2.8±3.8	1.2±0.9
Adenomas	5.2±5.8	0.9±0.7
MI Carcinomas	0.7±0.7	1.5±2.2
WI Carcinomas	1.5±2.1	5.4±6.3
Anaplastic Ca	36.0±32.0	5.9±5.6

These results were the result of the only statistically significant decrease of ISEL indices at internal compartment in adenomas (5.3±7.8% vs. 1.3±2.4%; $P = 0.0213$) and at peripheral compartments in carcinomas (1.4±1.7% vs. 2.3±5.5%; $P = 0.0474$).

Inverse and opposite proliferation/apoptosis correlations characterize FT lesions, the kinetic advantage predominating in the internal compartment of benign lesions and in the peripheral ones of malignant lesions. These relationships provide some indications and bases to separate benign from malignant FT lesions and an explanation as to why the benign lesions are well circumscribed and encapsulated.

Inaccuracies In Frozen Section Diagnosis

© CA Evans, SK Suvarna

Sheffield Teaching Hospitals, Sheffield, United Kingdom

Frozen section (FS) is a well-recognised perioperative process, with little medical literature. Many clinicians are unaware of FS realities / limitations.

We aimed to assess the FS reporting accuracy, reporting standards and whether specific limitations exist. 240 FS cases were analysed. The cases were analysed with clinical data; then compared against paraffin sections, the final diagnosis/ report. Specific attention was paid to errors that could affect patient outcomes.

13 cases contained incorrect information in varying guises. Six correctly reported the diagnosis, but omitted this data on the final report. Three had variations of diagnosis following paraffin section (eg SCC – adenocarcinoma). Two had diagnostic errors (carcinoid diagnosed, actually melanoma; fragmentary biopsy with carcinoma missed in inflammatory tissue). One had a sampling error (neoplasia elsewhere in sample, not in FS), and one case had a typographical error. Ultimately, inaccurate diagnostic interpretation accounted for 0.83%, and sampling inaccuracies accounted for 0.42% of study cases. The two diagnostic inaccuracies had potential for negative outcomes, but neither altered final surgery procedures. Overall, the FS accuracy rate for this series is regarded as 98.75%, and supports the surgeons' general faith in FS diagnosis.

Expression Of Adrenal Secretory Protease, AsP, (Human Airway Trypsin-Like Protease, HAT) In The Adult Human Adrenal Cortex And Its Tumours.

© JA Miller¹, DC Murray¹, AB Bicknell², HR Haak³, AM McNicol¹

¹ University of Glasgow, Glasgow, United Kingdom, ² University of Reading, Reading, United Kingdom, ³ Maxima Medisch Centrum, Eindhoven, Netherlands

Peptides derived from N-terminal proopiomelanocortin (POMC) can stimulate adrenal cortical growth and may be generated locally within the adrenal. A putative proteolytic enzyme, AsP, has been described in rodents and is an isoform of HAT. The expression of the protein in the human gland is not documented.

Aims. To examine expression of AsP/HAT in normal adrenal glands and adrenocortical tumours.

Methods. Immunoblotting was performed on normal adrenal glands (2) and immunohistochemistry on normal (6) and hyperplastic (4) glands and on adenomas (18) and carcinomas (21) using a rabbit polyclonal antibody raised to a sequence common to AsP and HAT.

Results. Immunoblotting demonstrated a band of ~46KDa, consistent with HAT. Membrane and cytoplasmic positivity was present in all zones of the normal cortex, although the patterns varied with the zone. Adenomas and carcinomas showed cytoplasmic and membrane staining, with relative loss of membrane staining in carcinomas ($p = 0.004$, Fisher's exact test).

Conclusions. Our data indicate that HAT is expressed in the human adrenal cortex. The cytoplasmic staining and widespread distribution would suggest that regulation of growth is not the only role. Loss of membrane staining in carcinomas may reflect a loss of function of the membrane bound isoform in tumour progression.

Temporal Trends in BRAF T1796A and ret/PTC oncogene detection in Irish thyroid neoplasms

© P Smyth, S Finn, R Flavin, S Cahill, E O'Regan, JJ O'Leary, O Sheils

Trinity College, Dublin, Ireland

The Ras/Raf/MEK/ERK pathway has been highly implicated in a variety of human neoplasms. B-Raf, a serine/threonine kinase is an integral part of this signalling pathway. It has been shown to be mutated in as high as 90% of some cancers, with 80% of these mutations being a V599E amino acid substitution caused by a missense mutation (T1796A). Its mutation rate in thyroid carcinomas is second only to melanomas/nevi.

ret/PTC oncogenes were, prior to the discovery of the involvement of B-Raf, the most common genetic changes among papillary thyroid carcinomas (PTCs). Our group have previously demonstrated a pathobiological link between PTC and Hashimoto Thyroiditis (HT) using ret/PTC oncogene studies, and suggested that HT may in fact be a pre-neoplastic lesion of PTC.

The purpose of this study was to assess B-Raf mutation rates in thyroid tissues and to investigate concomitant mutations with ret/PTC (-1 and -3) activation. Heterozygous T1796A mutations were detected in 15 of 34 (44%) PTCs tested. No mutations were detected in the other tissue types tested including HT further supporting the notion that this type of thyroiditis may be a pre-neoplastic lesion of PTC. Concomitant presence of both oncogenes was reported in 5 of the 34 PTCs. A significant temporal trend was observed, with ret/PTC oncogenes tending to occur pre-1997 and B-Raf mutations being more prevalent post-1997. Our results suggest that some environmental/etiological agent(s) may have influenced the pathobiology of thyroid tumour development over time.

Array CGH profiling of laser capture microdissected Papillary Thyroid Carcinoma tumours and clonal cell lines.

© SP Finn¹, PA Smyth¹, EM O'Regan², C Timon¹, S Cahill¹, M Toner², R Flavin¹, JJ O'Leary¹, OM Sheils¹

¹ University of Dublin, Trinity College, Dublin, Ireland, ² Dublin Dental Hospital, Dublin, Ireland

Previous classical Comparative Genomic Hybridization (CGH) studies of Papillary thyroid carcinoma (PTC) have demonstrated a low prevalence of copy gain and loss, with the majority of tumours showing no evidence of chromosomal instability demonstrable by CGH. The technique of CGH has been improved, however, by the introduction of array CGH and by the use of laser capture microdissection to ensure pure cell populations for analysis. We describe array CGH profiles of laser-captured thyrocytes from 11 well-characterised PTC with known ret/PTC and BRAF mutation status. The cohort includes 5 classic and 3 follicular variant tumours. In addition we examined 3 clonal PTC cell lines. Our results indicate that copy gain and loss occurs at low levels in **all** of the tumours and cell lines examined. Cell lines, as would be anticipated, show a higher prevalence of aberrations than tumour samples. The most common recurrent aberrations involve gains on chromosomes 1, 5, 7, 11, 15, 17 and 22 with recurrent deletions occurring on chromosomes 4, 18 and 19. Independent analysis of the data from the 8 tumour samples shows that amplifications of TP73 (1p36.33), SNRPN (15q12) and PDGFB (22q13.1) occur exclusively in tumours with a wild type BRAF status and variant morphology. None of the 8 tumour samples showed either of the 2 common ret/PTC rearrangements.

This study of PTC shows a higher prevalence of aberrations than previously described in the literature. Recurrent patterns of gains and losses are seen with potential oncogenes identified in tumours with no well-described molecular trigger. The combination of laser capture microdissection and arrayed clones optimises studies utilizing CGH.

IMMUNOHISTOCHEMICAL EXPRESSION OF NESTIN IN GASTRO-INTESTINAL STROMAL TUMORS(GISTs):A STUDY FROM NEUROENDOCRINE 'TISSUE MICROARRAY(TMA)' PANEL

© K HIRABAYASHI, C INOMOTO, K YONEDA, H KAJIWARA, S MIYAI, S UMEMURA, M YASUDA, R.Y OSAMURA

Tokai University, Isehara, Japan

Tissue microarray(TMA) has been applied for immunohistochemical(IHC) staining to evaluate the particular antibodies or to characterize group of tumors with particular antibodies. In this study using neuroendocrine(NE) TMA panels, we have experienced high frequency of nestin expression in GISTs and very occasional expression in the NE tumors(NETs). GISTs are the tumors which are derived from Cajal(pacemaker cells) and may sometimes morphologically mimic NETs, especially in epithelioid type.

Design:Total 60 NETs(pituitary adenomas, WDET:carcinoids, pheochromocytomas, pancreatic islet cell tumors,medullary carcinoma of thyroid,PDNC: small cell carcinomas) and 5 cases of gastrointestinal stromal tumor:GISTs were subjected to the study. Tissue microarrayer(Beecher Instrument) was used to make TMA paraffin blocks. Indirect IHC staining was performed on paraffin sections using antibodies against CGA,NCAM,PGP9.5,SV2,SNAP25,PC/3 and PC2 as well as nestin. Antigen retrieval was done according to the manufacture's instructions.

Results and conclusions:Immunohistochemistry on TMA showed satisfactory staining for all markers studied. NETs showed the positive staining with various patterns not only among NETs but also among individual tumor cells. It is particularly noteworthy that all GISTs(including epithelioid type) are negative for NE markers and are positive for nestin which is very occasionally positive in NETs. Our studies indicate that GISTs show different IHC profiling from NETs and suggest that nestin could serve as an additional marker for GISTs.

PREDICTIVE VALUE OF THYMIDINE PHOSPHORYLASE IN GASTRIC CARCINOMA

M Kandil, © M Abd el Wahed, M El Tahmody
Menoufeya University, Shebin el Kom, Egypt

Aim of work: Evaluation of TP/PD-ECGF expression in gastric adenocarcinoma and its correlation with established clinicopathological parameters and patients' survival.

Material and methods: The material of this study consisted of archival paraffin blocks of fifty-two gastric specimens. Twenty-seven cases of chronic gastritis and twenty-five cases of malignant adenocarcinoma. The tumor was considered positive for TP/PD-ECGF staining when more than 5% of cells showed positive staining.

Results: TP/PD-ECGF expression was significantly higher in malignant group than control group (p=0.001). Tumor and stromal cell TP/PD-ECGF expression in the malignant group correlated with postoperative chemotherapy, size of tumor, mitotic count, stage grouping, depth of invasion, number of lymph node (LN) involved, perineural invasion, lymphoplasmacytic and tumor associated macrophages (TAMs) infiltration, VD and positive surgical margins. Survival analysis revealed that superficial tumors, moderate grade, negative LN metastasis, absence of vascular or perineural invasion, low VD, negative surgical margins, postoperative chemotherapy and negative tumor and stromal TP/PD-ECGF expression correlated with better survival of the patients. Depth of invasion was the independent prognostic factor in Cox regression analysis (P=0.03).

Conclusions: TP/PD-ECGF might have angiogenic function and role in tumor growth, invasion and metastasis. TP/PD-ECGF could enhance the effect of postoperative chemotherapy.

Key words: Thymidine Phosphorylase/ Platelet Derived – Endothelial Cell Growth Factor (TP/PD-ECGF) - gastric carcinoma

Expression of hTERT in gastrointestinal stromal tumours occurs preferentially in malignant neoplasms

© M Sabah, R Cummins, M Leader, E Kay
Royal College of Surgeons in Ireland, Dublin 9, Ireland

Background: Telomerase is expressed in many human cancers and cell lines and is thought to contribute to their immortality. To date, little is known about the expression of telomerase in non-epithelial tumours. The objective of this study was to evaluate the expression of human telomerase reverse transcriptase (hTERT) in gastrointestinal stromal tumours (GISTs).

Methods: Twenty three GISTs (9 low malignant potential, 10 primary malignant and 4 intra-abdominal recurrences) were evaluated for hTERT expression using immunohistochemistry on tissue microarray. Tissue blocks were retrieved and H&E stains were performed to evaluate the histologic tumour type. All cases were strongly positive for KIT (CD117). Immunohistochemistry for hTERT was performed.

Results: Eighty nine percent (8/9) of the low malignant potential group were negative for hTERT immunoreactivity whereas all malignant GISTs showed positive staining which varied from weak to strong immunoreactivity. 60% (6/10) of the primary malignant GISTs were strongly positive. The remaining 40% (4/10) showed weak staining. All recurrent GISTs (4/4) exhibited strong positive immunostaining for hTERT.

Conclusions: Telomerase expression occurs during the progression of GISTs and immunohistochemical staining for hTERT may be a useful marker for the prognostication of GISTs

Metastatic Lymph Node Deposits Originating From A Different Primary To That Of The Resection Specimen

© R Swamy, H M Kamel
Department of Histopathology, Royal Infirmary, 51, Little France Crescent, Edinburgh, United Kingdom

We describe an unusual finding in a resection specimen for colonic carcinoma. The primary tumour in the resection specimen was a moderately differentiated adenocarcinoma of the sigmoid colon. Ten out of sixteen lymph nodes retrieved from the specimen including the apical lymph node showed metastatic adenocarcinoma with a morphological pattern different to that of the primary cancer. A close examination of the colonic cancer showed no evidence of a similar phenotype in any part of the tumour. The morphology of a micro-acinar architecture raised the suspicion of metastases from a primary prostatic adenocarcinoma. Immunohistochemistry was performed which showed positive staining for PSA and negative staining for CK20 and CEA markers, confirming our suspicion.

This case highlights the importance of proper histological comparison and evaluation of any variations in the phenotypes between the primary tumour and their metastases in the draining lymph nodes. While tumour de-differentiation in nodal metastases is common, unusual variations in tumour phenotype must be diligently recorded since this can have significant implications on patient management, staging and prognosis. It can also lead to identification of new pathology or another primary as in this case.

Chromosomal Changes in Colorectal Adenomas: Specific Relation to Gene Mutation and Clinical Utility in Screening

A Leslie, A Stewart, DU Baty, NR Pratt, RJC Steele, © FA Carey
University of Dundee, Dundee, United Kingdom

We have previously shown that the model of colorectal carcinogenesis involving sequential changes in the APC, K-ras and p53 genes is not supported by the mutational profile of cancers (PNAS 2002; 99:9433). We have also demonstrated specific associations between gene mutations and chromosomal abnormalities (eg p53 with 20q+, 18q-, 13q+, K-ras with 12p+. Cancer Res 2003; 63:4656).

We have now analysed APC, K-ras and p53 mutations and chromosomal change by comparative genomic hybridisation (CGH) in 79 colorectal adenomas. APC (52%) and K-ras (27%) mutations were seen at a similar frequency to that observed in cancer. p53 mutation (3 cases, 4%) was rare. As in cancers we did not see any cases with both K-ras and p53 mutation supporting our previous contention that these mutations may define separate pathways to colorectal carcinoma.

Many of the important CGH changes seen in cancer were also present in adenomas. The 2 most frequent cancer changes, 20q+ (80%) and 18q- (76%), were much less common in adenomas (11% and 10% respectively). However both abnormalities were significantly associated with histological severe dysplasia ($p < 0.01$) and with p53 mutation ($p < 0.03$). 12p+ was linked to K-ras mutation ($p < 0.01$) and increased adenoma size ($p < 0.01$). 13q+ was seen more often in patients with synchronous neoplasms ($p < 0.05$). This finding may have implications in follow up of adenoma patients.

This work shows that specific chromosomal changes (not currently included in prevailing models of tumorigenesis) interact with point mutations in complex and specific ways in colorectal adenomas and carcinomas. Some of the changes show promise of clinical utility.

Gastrointestinal Endoscopic Biopsies Of "Limited Or No Clinical Value"(LONCV): Completing The Audit Cycle

© S. E Littleford, B. J Rembaken, A Cairns
Leeds General Infirmary, Leeds, United Kingdom

Background and Aim: A previous audit conducted by the same authors found that 18% of gastrointestinal endoscopic biopsies fell into the LONCV category as defined by the RCPATH. The majority of these were gastric biopsies taken for diffuse gastritis. Endoscopists were presented with this data and adherence to RCPATH guidelines discussed. The effect of this intervention on LONCV biopsies was evaluated.

Methods: All gastrointestinal endoscopic biopsies received during July-September 2003 were retrieved from computer records and the clinical data provided on the request forms used to identify LONCV biopsies.

Results: 1025 biopsies were received, of which 5% were defined as of LONCV. There was a significant reduction in the percentage of gastric, ileal and duodenal LONCV biopsies ($p < 0.05$). No significant pathology would have been missed.

Conclusion: A significant and sustained reduction in the percentage of gastrointestinal endoscopic LONCV biopsies was achieved after discussion with endoscopists. This represents the effect of increased awareness of RCPATH guidelines and the presentation of audit data showing no significant pathology in LONCV biopsies.

The correlation between phenotypic expression and tumor development in colorectal epithelia tumors

© T Yao , K Nishiyama , M Tsuneyoshi
Kyushu University, Fukuoka, Japan

The purpose of this study is to clarify the correlation between the phenotypic expression and tumor development. Colorectal adenomas and adenocarcinomas were randomly selected, including 236 tubular (15 low-grade adenoma, high-grade adenoma 34, invasive carcinoma 187) and 60 villous (low-grade adenoma 15, high-grade adenoma 23, invasive carcinoma 22) tumors. By the combination of expression CD10, MUC2 and human gastric mucin, the lesions were classified into five types, large intestinal (LI), mixed (Mix), small intestinal (SI-type), gastric (G-type) and unclassified (UC) types.

Villous tumors revealed higher incidence of Mix-type (60% in low-grade and 83% in high-grade adenomas) than tubular tumor did (13% in low-grade and 6% in high-grade adenomas). On the other hand, tubular tumors contained SI-type (35% in high-grade adenoma and 22% in invasive carcinoma), however, no villous tumors revealed SI-type. In tubular tumors, polypoid growth carcinomas revealed similar phenotypic expression to tubular adenomas, but they revealed different phenotypes from non-polypoid ones. In addition, higher incidence of venous invasion was seen in SI-type.

In conclusion, the different carcinogenic pathway is suggested between villous and tubular tumors and between polypoid and non-polypoid carcinomas. Such phenotypic classification is also useful for evaluation of the biological behavior.

Audit Of Compliance With Upper GI Cancer Minimum Datasets

© A BISWAS , KP WEST
LEICESTER ROYAL INFIRMARY, LEICESTER, United Kingdom

Minimum datasets assist pathologists in providing clinically useful and relevant information in surgical pathology reports. The purpose of this study was to audit the compliance of upper GI cancer reports with the minimum datasets for oesophageal and gastric cancers.

We included all upper GI cancer resection specimens reported during the period 2001 to 2003 at Leicester. There were 225 cases, comprising gastric adenocarcinomas (56%), oesophageal adenocarcinomas (20.2%), gastro oesophageal adenocarcinomas (14.8%), oesophageal squamous cell carcinomas (7%) and others (2%). In spite of the free text style of reporting, pathologists were generally compliant with the relevant minimum datasets. We assessed the impact of using minimum datasets by comparing the present group with a randomised collection of 100 cases from 1998.

Overall, present day surgical pathology reports are more likely to contain prognostically relevant data like circumferential margin status in lower oesophageal cancers (98% versus 82%), lymphovascular invasion (84% versus 72%) and character of invasive margin in gastric cancers (70% versus 53%). A significant improvement in the prognostic value of the reports was readily apparent with the incorporation of minimum datasets in reporting of upper GI cancers.

Dysplasia Risk and Subtypes of Intestinal Metaplasia in Barrett's Mucosa

LJ Neilson , RC Stuart , © JJ Going
University of Glasgow, Glasgow, United Kingdom

Dysplasia is strongly associated with intestinal metaplasia (IM) but not with non-intestinal metaplastic mucosal phenotypes (cardiac, fundic) which also occur in Barrett's mucosa. This study sought to investigate whether the risk of dysplasia in Barrett's metaplasia varies between IM subtypes (type I or complete IM and the two subtypes of incomplete IM defined by the absence (IIa) or presence (IIb) of sulphomucins in columnar cells).

Biopsies from a total of 812 oesophageal sites (excluding the OG junction) in long-segment Barrett's oesophagus patients were stained with High Iron Diamine / Alcian Blue pH 2.5 to reveal acidic and sulphated mucins and were scored for the presence of type I IM (with a brush border and negligible alcianophilia of columnar cells), type IIa IM and type IIb IM (as defined above). Dysplasia was grouped as either absent (no atypia or reactive only) versus probable and definite dysplasia. The table shows observed and (expected) numbers of biopsies by dysplasia category and IM type:

IM type	No dysplasia	Dysplasia present
I	74(60)	2 (16)
IIa	222 (214)	48 (55)
IIb	376 (397)	123 (102)
$\chi^2 = 21.4 P < 0.0005$		

This highly significant P value is not due to any difference of dysplasia risk between types IIa and IIb IM but type I IM appears to be a marker of low dysplasia risk at that site in Barrett's oesophagus.

Detection Of Adenocarcinoma In Barrett's Oesophagus

© K P Prasad , J I Wyatt , N Scott , C Verbeke , M Denyer
Leeds Teaching Hospitals NHS Trust, LEEDS, United Kingdom

Surveillance of patients with Barrett's oesophagus (BO) aims at detecting oesophageal adenocarcinoma (AC) at an early stage, although >90% of the patients with AC are still diagnosed at first endoscopy.

We reviewed coded diagnoses of all oesophageal biopsies between 1996 and 2003. Surveillance patients are defined as BO or dysplasia on first biopsy with at least one further biopsy within 3 years. Index AC are diagnosed at first biopsy, or early repeat biopsy. Surveillance AC are detected in a biopsy during surveillance.

Results: 1674/5624(30%) biopsies showed BO. 300/980(30.6%) patients with BO had surveillance, averaging 3.3 endoscopies each. Histology in first biopsy and worst histology in subsequent biopsies are shown in the table.

First histology	Worst histology in subsequent biopsies			
	BO	LGD	HGD	AC
BO (n=265)	228	25	6	6
LGD (n=28)	11	15	1	1
HGD (n=7)	0	1	6	0

Only 7 of 217(3.3%) patients diagnosed with AC were under surveillance. 6/7(86%) surveillance cases were stage 1 compared with 12/65(18.5%) of the resectable index AC. Only 2/7 patients with surveillance AC had previous dysplasia; 5 AC were diagnosed after 1-3 previous biopsies showing BO only.

Conclusion: Only 3.3% AC were diagnosed during BO surveillance; we have so far seen a BO-dysplasia-AC sequence in only 1 patient in 8 years despite increased frequency of endoscopy in patients with dysplasia.

Assessing Inter-observer Variation In The Reporting Of Local Peritoneal Involvement (LPI) In pT3 and pT4 Colon Carcinoma

© S. E Littleford, A Baird, A Cairns, O Rotimi, C Verbeke, N Scott

Leeds General Infirmary and St. James's University Hospital, Leeds, United Kingdom

Background and Aim: LPI has been found to be one of the strongest independent predictors of recurrence of Dukes' B colon cancer and provides a potential means of selecting patients for adjuvant therapy. However, substantial variation in the frequency of LPI reporting has been documented between histopathology departments. Shepherd et al. have proposed a grading system for the assessment of LPI. This study aimed to validate this grading system by determining the degree of inter-observer variation in the reporting of LPI.

Methods: 60 cases of pT3 and pT4 colon carcinomas diagnosed in 2001 were identified from a pathology database. Three specialist gastrointestinal pathologists independently assessed representative H & E slides of the closest tumour proximity to the peritoneal surface according to Shepherd et al. Kappa statistics were performed to assess the degree of inter-observer agreement. **Results:** Inter-observer agreement on LPI grading ranged from $\kappa = 0.60$ (moderate) to $\kappa = 0.83$ (almost perfect).

Conclusions: This study validates the proposed grading system for LPI. Using this grading system there is excellent agreement between specialist gastrointestinal pathologists in the reporting of LPI in patients with pT3 and pT4 colon carcinoma. This grading system can therefore be recommended to assess LPI in these patients.

Dysplasia Grading In Tissue Microarrays From Colorectal Adenomas: How Good Is The Observer Agreement?

© V Kumaraswamy¹, N Maughan¹, N Scott¹, M Dixon¹, P Quirke², H Grabsch²

¹ Dept of Histopathology, Leeds Teaching Hospitals NHS Trust, Leeds, United Kingdom, ² Academic Unit of Pathology, University of Leeds, Leeds, United Kingdom

Immunohistochemical studies (IHC) done on tissue microarrays (TMA) have yielded the same results as studies done on full sections (FS). Furthermore, observer agreement was better when IHC results from TMAs were scored or when prostate cancers were graded on TMAs. We hypothesised (i) that TMAs constructed from colorectal adenomas (ADs) are representative of the full section, and (ii) the inter- and intra-observer agreement in grading dysplasia will improve using 0.6 mm TMA cores as they are more likely to be homogeneous.

TMAs were constructed from 61 flat, 110 tubular and 34 tubulovillous ADs. All cores were graded twice by 3 pathologists as inadequate; normal; mild, moderate or severe dysplasia or invasive cancer. Inadequate cores due to tissue loss or mis-sampling were excluded from the final analysis. Results were analyzed for agreement between observers as well as between FS grade and TMA grade by kappa statistics and Bland-Altman plots.

155 of the 414 cores were classified as inadequate. TMA grade and FS grade disagreed in 47 to 71% of cases (κ : 0.05 to 0.25). The inter-observer agreement on the grade of adenoma ranged from slight (κ : 0.115) to moderate (κ : 0.565). The intra-observer agreement ranged from fair (κ : 0.347) to moderate (κ : 0.580).

Our study showed that observer agreement in grading dysplasia is only slightly better on TMAs than reported for FS ($\kappa=0.22$). Thus, it seems, that morphological parameters alone such as grading are insufficient to determine the representativity of cores. More objective markers are required to assess dysplasia in adenomas reliably and to evaluate representativity of adenoma cores. Future studies will also need to address the question of how many cores are needed from each adenoma to be representative for the FS.

Analysis Of DNA Copy-Number Changes At 8q23-q24 In Colorectal Cancer By MLPA

T.E. Buffart¹, J. Coffa¹, M.A.JA Hermsen¹, © B. Carvalho¹, J.P. Schouten², G. Pals², B. Ylstra³, G.A. Meijer¹

¹ Dept. Pathology, VU University Medical Center, Amsterdam, Netherlands, ² MRC-Holland, Amsterdam, Netherlands, ³ Micro-array Core Facility, VU University Medical Center, Amsterdam, Netherlands

C-myc (8q24.1) and PRL-3 (8q24.3) were found to be amplified in colorectal cancer metastasis. In addition, other oncogenes at 8q23-24 might be involved. The present study aims to analyse DNA copy number changes at 8q23-24 in colorectal cancer at high resolution in correlation to metastatic disease.

DNA from 32 primary colorectal tumours and corresponding liver metastases (when present) was isolated. A chromosome 8 specific MLPA probe mixture was used.

Significant differences in DNA copy number were found in the genes MOS ($p=0.04$), MYC ($p=0.01$), DDEF1 ($p<0.00$), PTK2 ($p=0.02$) and PRL-3 ($p=0.04$) when comparing Astler-Coller B1 and B2 colorectal cancers. Between these and Astler-Coller D primary tumours, significant differences were also seen for several genes (MYC ($p<0.00$), DDEF1 ($p<0.00$), SLA ($p<0.00$), PTK2 ($p<0.00$), PRL-3 ($p<0.00$), and RECQL4 ($p=0.01$)). Liver metastases showed higher levels of amplifications than corresponding primary tumours, although only TPD52 ($p=0.02$) and EIF3S6 ($p=0.01$) differed significantly.

In addition to c-myc and PRL-3, multiple genes on chromosome 8 differed significantly between primary colorectal cancers with and without liver metastases. Our results are consistent with the hypothesis that metastatic potential is already determined early in the genomic profile of the primary tumour.

Cyclin E as an Independent Predictor of Survival in Early Onset Gastric Cancer

© ANA Milne¹, R Carvalho¹, E Meershoek-Kleinberg², FAM Morsink², AR Musler¹, MAJ Weterman¹, GJA Offerhaus¹

¹ Pathology Dept., Academic Medical Centre, Amsterdam, Netherlands, ² Surgical Data Centre, Leiden University Medical Centre, Amsterdam, Netherlands

Amplifications in the cyclin E gene, an important cell cycle regulator, have been described in early onset gastric cancer (<45) and correlate with overexpression of the cyclin E protein. We investigate further the overexpression of cyclin E in several groups of gastric cancers, in order to ascertain its relevance in young patients. Immunohistochemistry was performed on 190 cases: 92 early onset gastric cancers, 28 stump cancers and 70 conventional (>45) gastric cancers using both N-terminal and C-terminal cyclin E antibodies. Cyclin E expression was present in 13% (N-terminal antibody) and 45% (C-terminal antibody) of early onset gastric cancers, whereas stump cancers and conventional cancers showed no marked difference in expression between the two antibodies. This increased staining with the C-terminal antibody in young patients can be attributed to the recognition of low molecular weight isoforms of cyclin E as demonstrated by western blots of gastric cancer cell lines. We intend to confirm further the presence of these cyclin E isoforms using siRNA. Cox regression survival analysis of 44 cases found cyclin E to be an independent positive predictor of survival in early onset gastric cancer only when using the C-terminal antibody. Our findings suggest that low molecular weight isoforms are a novel cause of cyclin E overexpression in early onset gastric cancer and uniquely influence survival.

DNA Double Strand Break Repair And Mismatch Repair in Gastric Cancer – Are ATM And BRCA The Connection?

© M Dattani¹, K Maude², L Barker³, S Gray³, H Sue-Ling², M Dixon³, P Quirke¹, H Grabsch¹

¹ Academic Unit of Pathology, University of Leeds, Leeds, United Kingdom, ² Academic Unit of Surgery, Leeds Teaching Hospitals NHS Trust, Leeds, United Kingdom, ³ Dept of Histopathology, Leeds Teaching Hospitals NHS Trust, Leeds, United Kingdom

Impaired DNA repair may contribute to genomic instability and malignant transformation. It has been suggested that a BRCA1-associated protein complex coordinates both, DNA double-strand break [DSB] repair and mismatch repair [MMR]. However, the expression of BRCA1 and other proteins involved in DSB repair, and their relationship to MMR protein expression has not been investigated in sporadic gastric cancer [GC].

We investigated the expression of DSB repair proteins (ATM, BRCA1, BRCA2) and MMR proteins (MSH2 and MLH1) by immunohistochemistry on tissue microarrays constructed from 163 GC. The percentage of positive tumour cells was assessed and correlated with clinicopathological data and patient survival.

ATM and BRCA1 expression was reduced in all GC compared to normal mucosa, whereas BRCA2 expression was increased. Furthermore, ATM and BRCA1 expression was significantly lower in intestinal-type GC compared to diffuse-type GC. MSH2 expression was lost in 6 GC, MLH1 expression was lost in 11 GC. Loss of MMR protein expression was significantly associated with reduced or loss of expression of ATM, BRCA1 and BRCA2. Low BRCA2 expression (<25% positive tumour cells/case) was associated with poor patient survival and proved to be an independent prognostic marker in multivariate analysis.

This is the first study suggesting that DSB repair proteins may play an important role in GC. Significantly lower expression of ATM and BRCA1 in intestinal-type GC may indicate impaired DSB repair and may explain the higher incidence of genomic instability in this phenotype. The association of MMR and DSB repair protein expression may support the model of a functional interaction between the two pathways and warrants further investigation.

Cytokine mRNA Expression Profiles in Children with Lymphonodular Hyperplasia and Autistic Spectrum Disorders.

© CM Martin¹, L Pilkington², O Sheils³, JJ O'Leary¹

¹ Department of Pathology, Trinity College Dublin and Coombe Women's Hospital, Dublin, Ireland, ² Department of Pathology, Coombe Women's Hospital, Dublin, Ireland, ³ Department of Histopathology, Trinity College Dublin at St James Hospital, Dublin, Ireland

A relationship between gastrointestinal dysfunction and autism has been hypothesised based on the identification of a new variant of inflammatory bowel disease "autistic enterocolitis" in a cohort of children with autistic spectrum disorders. The intestinal pathology includes ileocolonic lymphonodular hyperplasia and a non-specific colitis. In this study we examine the expression profiles of 24 cytokine mRNA's in the intestine of patients with autistic enterocolitis and controls using TaqMan™ Cytokine Card technology. Terminal ileum tissue biopsies from autistic enterocolitis patients (n=7) and the following developmentally normal paediatric controls; Crohn's disease (n=5), ulcerative colitis (n=5) and lymphonodular hyperplasia (not associated with autism) (n=4) were examined. Total RNA was extracted using the Qiagen RNeasy Minikit and the mRNA expression profiles of 24 inflammatory cytokines were examined in each sample. The comparative Ct method of relative quantitation of mRNA expression was performed.

In this study increased mRNA expression of the pro-inflammatory cytokines, TNF- α , IL-6 and IL-1 were demonstrated in the intestine of the autistic enterocolitis cohort when compared with IBD and LNH controls. The results are suggestive of an abnormal innate immune response and intestinal inflammation in the intestine of these children. The data supports an association between gastrointestinal dysfunction and autism.

Subcellular Localisation Of BUB1 Gastric Cancer Is Linked To Tumour Differentiation And Progression, But Not To Survival

© R Dave¹, F Lewis², K Maude³, S Gray², H Sue-Ling³, W Mueller⁴, J Wyatt², M Dixon², P Quirke¹, H Grabsch¹

¹ Academic Unit of Pathology, University of Leeds, Leeds, United Kingdom, ² Dept of Histopathology, Leeds Teaching Hospitals NHS Trust, Leeds, United Kingdom, ³ Academic Unit of Surgery, Leeds General Infirmary, Leeds, United Kingdom, ⁴ Gemeinschaftspraxis Pathologie, Starnberg, Germany

Two types of genetic instability can be distinguished: chromosomal instability (CIN) and microsatellite instability (MSI). CIN can occur due to a defective mitotic spindle checkpoint. BUB1 is a key regulator of this checkpoint. We have shown in a pilot study, that low BUB1 expression is related to intestinal-type gastric cancer (GC). We now studied BUB1 gene dosage and BUB1 expression level in a larger series of GC. Loss of msh2 and mlh1 expression was used as a marker of MSI, aneuploidy as a marker of CIN.

BUB1 expression was analysed on tissue microarrays from 163 GC by immunohistochemistry evaluating the percentage of positively stained cells. BUB1 gene dosage was determined by real-time PCR. Results were correlated with histopathological data, patient survival, ploidy and expression of mismatch repair (MMR) proteins MSH2 and MLH1.

BUB1 positivity was seen in all GC showing exclusively nuclear localisation in 50% of GC. BUB1 expression was significantly lower in MMR negative GC (n=13) and in intestinal-type GC. Additionally, nuclear BUB1 positivity correlated significantly with high pT, high grade and diffuse-type GC. BUB1 expression did not correlate with BUB1 gene dosage, ploidy or patient survival. Our study suggests that the subcellular localisation of BUB1 may determine tumour progression, grade and histological subtype of GC. The association of low BUB1 expression and loss of MMR protein expression may indicate a common regulatory mechanism. The functional significance of our findings, especially the regulation of BUB1 expression, BUB1 nuclear-cytoplasmic shuttling and BUB1 protein degradation needs to be studied in more detail in order to better understand different expression and subcellular localisation in different histological subtypes in GC.

The Frequency of the Cytochrome P450 2C19 Polymorphism is not increased in Barrett's Oesophagus

© DR MORALES, JP COTTON, JF DILLON

Department of Digestive Diseases and Clinical Nutrition, Ninewells Hospital and Medical School, Dundee, United Kingdom

Background: The incidence of Barrett's oesophagus (BO) and oesophageal adenocarcinoma is increasing. Proton Pump Inhibitors (PPI's) are metabolised mainly by the cytochrome P450 (CYP) enzyme 2C19. CYP2C19 is polymorphic in 30% of the Caucasian population. Plasma gastrin levels are significantly higher in patients with the CYP2C19 polymorphism taking PPI's. Gastrin has been shown to be a growth factor for normal and malignant gastrointestinal mucosa and expression of gastrin has been shown to be an important event in the development of gastric adenocarcinoma. The aim of the study is to investigate the frequency of the CYP2C19 polymorphism in BO patients on PPI therapy.

Method: Restriction fragment length polymorphism (RFLP) analysis, of genomic DNA from BO patients and gastroesophageal reflux disease (GORD) controls with PPI exposure (>1 day), was used to look for a G-A substitution in exon 5 of the CYP2C19 gene (CYP2C19*2), accounting for 75-83% of defective alleles in the CYP2C19 gene.

Results: The frequency of CYP2C19*2 was 26.3 and 23.6% in BO (n=137) and GORD (n=148) patients respectively with PPI exposure. This was not significantly different (P>0.5). The frequency of CYP2C19*2 was 42.3 and 35.7% in BO (n=26) and GORD (n=42) patients respectively with no PPI exposure. This was not significantly different from the above groups (P \geq 0.1).

Conclusion: No significant difference in the frequency of CYP2C19*2 was observed to support the hypothesis that hyper-gastrinaemia has a role to play in the increasing incidence of BO.

Beta-catenin Expression In Gastric, Small Bowel And Colorectal Cancers: Association With Clinicopathological Data And Prognosis

© KM Maude¹, CS Verbeke², L Harkin², S Gray², PD Howdle³, MJ McMahon¹, W Mueller⁴, H Grabsch⁵, P Quirke¹
¹ Academic Unit of Surgery, Leeds General Infirmary, Leeds, United Kingdom, ² Dept of Histopathology, Leeds Teaching Hospitals NHS Trust, Leeds, United Kingdom, ³ Academic Unit of Medicine, St James' University Hospital, Leeds, United Kingdom, ⁴ Gemeinschaftspraxis Pathologie, Starnberg, Germany, ⁵ Academic Unit of Pathology, University of Leeds, Leeds, United Kingdom

Beta-catenin [b-cat] is a multifunctional protein with critical roles in both cell-cell adhesion and Wnt-stimulated transcriptional regulation. Studies on the expression of b-cat in gastric [GC] and colorectal [CRC] cancers have provided conflicting results. Its role in small bowel [SBC] cancer is completely unclear. This study compared the expression pattern of b-cat in tumours throughout the gastrointestinal tract including its impact on patient prognosis.

B-cat expression was investigated on tissue microarrays constructed from 342 CRC, 161 SBC and 163 GC by immuno-histochemistry. B-cat expression was classified as membranous, cytoplasmic and/or nuclear. Any pattern other than membranous was regarded as abnormal. Staining results were compared between CRC, SBC and GC and correlated with clinico-pathological data and patient survival within each tumour group.

Nuclear b-cat was found significantly more often in CRC than in SBC or GC, cytoplasmic b-cat more often in SBC than in GC or CRC, and reduced membranous b-cat more often in GC than in CRC or SBC. In SBC, abnormal b-cat correlated with higher tumour grade, but was significantly associated with a better prognosis. In CRC, normal membranous b-cat staining proved to be an independent prognostic marker. There was no association of b-cat expression with any of the investigated parameters in GC.

Our study suggests that different types of abnormal b-cat expression are related to different types of gastrointestinal cancers. This may indicate that downstream effects of abnormal b-cat may also be different between these entities and should be studied and compared. The correlation of normal b-cat expression with better survival in CRC but poorer survival in SBC cannot be explained at the moment, but warrants further investigation.

CD10 Staining In The Normal Testis And Testicular Tumours

© M F Hickling, S R Rasbridge
 Royal Bournemouth Hospital, Bournemouth, United Kingdom

CD10 is a cell surface metalloendopeptidase expressed in normal and lymphoid neoplastic cells as well as endometrial stromal and breast myoepithelial cells but CD10 expression is not reported in the normal testis.

The differentiation of teratomatous and seminomatous testicular tumours is crucial for patient management. The commonest differential diagnosis lies between solid patterns of embryonal carcinoma and seminoma. Although morphological and immunohistochemical features of testicular tumours are documented, correct diagnosis may still be difficult.

We found nuclear CD10 staining only in 7 of 10 cases of malignant teratoma undifferentiated (MTU)/ embryonal carcinoma whilst 8 of 9 cases reported as seminoma showed cytoplasmic CD10 staining with a characteristic paranuclear dot; the remaining seminoma exhibited weak nuclear staining. Of 8 cases reported as mixed embryonal carcinoma/seminoma, the former component showed nuclear staining in 4 and was negative in the rest. Seven of the seminomatous components showed cytoplasmic staining including a paranuclear dot (very focal in 2) and in 1 case also showed nuclear staining. Strong nuclear staining was also noted in the normal rete testis and epididymis but not in other testicular structures.

These findings suggest a role for CD10 in identifying between testicular and metastatic embryonal carcinomas and seminomas.

The invasive suppressor molecule E-cadherin pattern in relation with the proliferating cell nuclear antigen of the associated and non associated Bilharzial bladder carcinoma

© Mona Rashed, Noha Ragab
¹ General Organization For teaching Hospitals and Institutes, Cairo, Egypt, ² Medical Research Institute, Alexandria, Egypt

E-cadherin is a transmembrane glycoprotein that plays a critical role in many aspects of cell adhesion as well as establishment and maintenance of epithelial cell polarity. Loss of the adhesive function of E-cadherin seems to promote invasive and metastatic properties of neoplastic cells. The present study is a retrospective study aiming at evaluating the loss E-cadherin immunohistochemical expression in relation with the proliferating cell nuclear antigen expression of forty primary urinary bladder carcinoma specimens, 37.5% were associated with bilharziasis. Histopathologically 62.5% were transitional cell carcinoma, 32.5% were squamous cell carcinoma and 5% were adenocarcinoma. Loss of E-cadherin expression presented a significant association with high PCNA index ($p=0.002$), high tumor grade ($p=0.0005$), and tumor invasiveness (0.0009); meanwhile no significance association neither to bilharziasis nor to histopathological typing of urinary bladder carcinoma.

Conclusion: Loss of E-cadherin may be of a clinical value in the assessment of prognosis and planning of therapy of patients with urinary bladder carcinoma as it indicate the potentiality for metastasis by its significant association with high proliferating cell nuclear antigen index, high tumor grade and tumor invasiveness.

Key words: E-cadherin, urinary bladder carcinoma & bilharziasis

PROSTATIC CORE BIOPSY AUDIT

© S PATIL, P FURNESS
 University Hospitals of Leicester, Leicester General Hospital, Leicester, United Kingdom

We sought to audit the reporting of needle biopsies of prostate in a teaching hospital over a period of one year (2003). We assumed that prostate biopsies submitted to the Department would be allocated at random to the Consultant pathologists present. We therefore compared the performance of individual pathologists in relation to the diagnosis of prostatic adenocarcinoma and the reporting of various histological features, including Gleason scoring.

The total number of prostatic needle core biopsies for the year 2003 was 657 of which 291 (44.29%) were malignant.

The consultants varied in the proportion of biopsies in which adenocarcinoma was found from 36.6% to 53.7%. This apparent variation is statistically significant at $p<0.05$ (Chi-squared test)

The average Gleason sum score allocated by each consultant varied from 6.49 to 7.25. Though not large, this difference was also statistically significant ($P<0.01$)

There were larger differences between consultants in the rate of diagnosis of prostatic intraepithelial neoplasia (range 5% to 23%), vascular invasion (1% to 7%) and inflammation (5% to 12%).

Rates of diagnosis of perineural invasion were similar (20% to 29%).

These results demonstrate significant variation in several key aspects of the reporting of needle biopsies of prostate between different consultants, including rates of benign/malignant diagnosis. These variations justify further investigation.

A Novel Method of Three-Dimensional (3D) Representation of Prostate Cancer Distribution from Whole Mount Radical Prostatectomy (RP) Specimens using Image Registration

© SS Mehta, JP Bury, JR Goepel, FC Hamdy, DC Barber
Royal Hallamshire Hospital, Sheffield, United Kingdom

Aim

To investigate the distribution of prostate cancer in RP specimens and produce a system of visually displaying tumour distribution in 3D using image registration.

Methods

RP specimens from patients undergoing surgery for cancer were step sectioned in 4mm slices. Both sides of each slice were photographed with a digital camera. 4µm slides were cut from the inferior surface of each slice and disease was identified and marked on each slide. Image registration software was used to register the disease distribution onto the digital pictures of the prostate slices. Each slice was then registered in turn, to each other along with the marked cancer.

Results

Histological slides and internal cancer distribution were successfully registered to digital slice images in all ten chosen cases. Our algorithm allowed for all disease distribution; including, multifocal, crescentic, overlapping and extracapsular disease; producing a visual 3D representation of cancer relative to the prostate capsule.

Conclusion

3D cancer representation using image registration is possible. This 3D visual display may assist the clinician in conveying information regarding tumour distribution. When applied to larger numbers a mean cancer distribution can be predicted; this information may assist the clinician in directing prostate biopsies to maximise the likelihood of cancer detection.

The continued value of central histopathological review of testicular tumours

© C D Sayers, R J Delaney, J M Theaker

Department of Pathology, Southampton University Hospitals,
Southampton, United Kingdom

The central histopathological review of testicular tumours prior to definitive treatment can have an important impact on subsequent patient management. A review in our centre between 1992-1997 highlighted a small number of significant errors in reporting of tumour type, and frequent discrepancies in vascular invasion and tumour elements within nonseminomatous germ cell tumours (NSGCTs). In order to assess the continuing value of central histopathological review we made a retrospective review of testicular tumours between 1998 and 2002.

The centrally reviewed histopathology reports of 291 referred testicular specimens (280 orchidectomies, 11 biopsies) from 15 local hospitals were compared with the referring hospital reports, looking particularly at major diagnosis, vascular invasion and the tumour elements within NSGCTs. Where a diagnosis was altered, any effect on subsequent patient management was noted.

There was a discrepancy in tumour type in 11 cases (4%) compared with 6% in 1992-97. The commonest change was from seminoma to NSGCT (6/11). There was also diagnostic difficulty with spermatocytic seminoma (3/11), an uncommon tumour. Subsequent management was altered in all 11 cases. Discrepancies in vascular invasion were noted in 13 of the 126 NSGCTs (10%) compared with 20% in 1992-7. Differences in NSGCT tumour elements were frequent in both groups.

There continues to be a small number of significant errors discovered at central histopathological review of testicular tumours although the frequency would appear to be decreasing. This study highlights the importance of central review and supports its continued practise in the management of testicular tumours.

Distribution of Caveolin 1 in the Human Glomerulus

L Butchart², C von Ruhland¹, G R Newman¹, M Gumbleton², K P Jones², L Campbell¹, © D F R Griffiths¹

¹ University of Wales College of Medicine, Cardiff, United Kingdom, ² Welsh School of Pharmacy, Cardiff University, Cardiff, United Kingdom

The caveolins are an evolutionary conserved family of proteins that represent the major component of caveolae. Caveolin-1 is known to be involved in many cell functions including signal transduction and proliferative responses to injury.

Increased caveolin expression has been observed in experimental glomerulonephritis and is increased in stressed cultured mesangial cells raising the possibility of its involvement in the pathogenesis of glomerulonephritis. The distribution of caveolin-1 in human glomeruli has not previously been reported. We used immunohistochemical and immunogold techniques on paraffin and resin sections of tissue from renal biopsies (IgA nephropathy: 10 cases; HSP: 2; membranous: 3; SLE: 2; post-infective: 1) and normal renal tissue to study the distribution of this protein in glomeruli.

In both normal and diseased glomeruli Caveolin-1 expression was identified in arteriole smooth muscle and endothelium; the staining stopped abruptly as the arterioles entered the glomeruli; no staining was seen in glomerular endothelium, visceral epithelium or mesangium. In contrast the capsular epithelium of both healthy and diseased glomeruli showed consistent strong membrane staining for caveolin-1.

Caveolin-1 does not appear to be a significant component of the glomerular tuft in health or disease; the functional significance of caveolin-1 in the capsular epithelium remains to be determined.

A Comparison of Proliferation Markers in Penile Lichen Sclerosus and Squamous Cell Carcinoma

© A.L Cooke¹, N Watkin², C.M Corbishley¹

¹ Department of Cellular Pathology, St. Georges Healthcare NHS Trust, London, United Kingdom, ² Department of Urology, St. Georges Healthcare NHS Trust, London, United Kingdom

Lichen sclerosus (LS) and penile squamous cell carcinoma (SCC) frequently co-exist. We compared cell proliferation in LS, SCC and normal penile epithelium to look for evidence of LS as a preneoplastic lesion.

Formalin fixed, paraffin embedded tissue from 30 cases each of penile SCC, penile LS and normal penile tissue were assessed immunohistochemically for expression of Ki67, Proliferating Cell Nuclear Antigen (PCNA) and p27^{KIP1}. No differences in expression patterns of Ki67, PCNA and p27 were observed in the Normal and LS groups. Only one third of cells expressing PCNA in all groups expressed Ki67. Increased Ki67 and PCNA were seen in SCC. No statistically significant difference in the expression of p27 was found. Expression of Ki67 and PCNA differed between the SCC group and the other groups. Staining heterogeneity throughout SCC samples indicated loss of normal cell turnover and abnormal growth patterns. Ki67, PCNA and p27 expression in normal, LS and SCC affected penile tissues shared a similar epithelial distribution.

There were no quantifiable differences in marker expression between normal and LS epithelium indicating no disparity in cell turnover. From this study there is no evidence of LS being a precursor lesion to SCC.

Infertile Males – Who Should Be Screened For Cystic Fibrosis Mutations

© EV Mocanu¹, R Shattock², C Martin², D Barton³, M Rogers³, O Sheils², JJ O'Leary², RF Harrison⁴

¹ HARI Unit Rotunda Hospital and Departments of Histopathology, Trinity College Dublin and Coombe Women's Hospital, Dublin, Ireland, ² Departments of Histopathology, Trinity College Dublin and Coombe Women's Hospital, Dublin, Ireland, ³ National Centre for Medical Genetics, Our Lady's Hospital for Sick Children, Dublin, Ireland, ⁴ HARI Unit Rotunda hospital and Royal College of Surgeons in Ireland, Dublin, Ireland

It is not clear from published literature if subfertile males have a higher carrier rate of CFTR gene mutations compared with their fertile counterparts. Up to recently, men with severe oligozoospermia or azoospermia were infertile. Assisted Reproductive Technology (ART) in the form of IntraCyttoplasmic Sperm Injection (ICSI) has made it possible for these men to become fathers. Blood DNA samples from 116 fertile men and 586 infertile males with different degrees of sperm count abnormalities (abnormal karyotype carriers, CBAVD and Y deleted excluded) requiring ICSI were screened for 31 CF mutations. The screen involved a Polymerase Chain Reaction Oligonucleotide Ligation Assay (PCR OLA) with automated gel electrophoresis and computerised mutation recognition. The incidence of CFTR gene mutations was significantly higher in the infertile group compared with the fertile population ($p=0.005$) mainly due to a high incidence of mutations in the azoospermic group ($p=0.002$). All patients were heterozygous for the mutations identified. This study clearly demonstrates the need for CFTR gene mutations screening in azoospermic men with no other genetic or obstructive causes for their infertility and suggests fundamental changes in the provision of care for infertile couples.

Evidence of expression of a prorenin receptor in renal cell carcinoma

© L.Y. Christie, V. Goojula, M. Aitchison, S. Fleming

¹ University of Dundee, Dundee, United Kingdom, ² Gartnavel general Hospital, Glasgow, United Kingdom

Most of the components of the renin angiotensin system are present in renal cell carcinoma (RCC), however renin is secreted in its inactive prorenin form. The recent discovery of a prorenin receptor capable of non-enzymatic activation of prorenin provides a potential mechanism for renin activation in RCC. Nguyen showed prorenin binding to mesangial cells had a hypertrophic effect and increased the expression of plasminogen activator inhibitor 1. This same group recently cloned a human prorenin receptor. The cloned sequence appears to encode a single transmembrane domain protein with no known homology. Transfected cells exhibit prorenin and renin binding with consequent activation of the prorenin without cleavage. The aim of the current project was to address the question is the recently identified activating receptor for prorenin expressed in human renal cell carcinoma? Samples of snap frozen tissue from cases of RCC (n=9) were obtained and mRNA extracted. A reverse transcriptase PCR reaction using primer pair 5'-GGGGGTGAACTGAGAACA-3' AND 5'-GCATTCTCCAAAGGGTACGA-3' was performed. In 5/9 cases a single band of the predicted size was obtained. The PCR product was sequenced and found to be identical to the published sequence for the prorenin receptor. This provides preliminary evidence that the putative prorenin receptor is expressed in cases of RCC providing a potential mechanism for intratumoural activation of the RAS

Overexpression of LAT1 in Human Prostate Cancer

© Y Terado, A Sakamoto

Department of Pathology, Kyorin University School of Medicine, Tokyo, Japan

We investigated the expression of LAT1 (L-type amino acid transporter 1) in prostate cancer by immunohistochemical study. The LAT1 is a Na(+)-independent neutral amino acid transporter subserving the amino acid transport system L. We examined 115 needle biopsy specimens of human prostate cancer. Diffuse and strong positivity for LAT1 was identified in carcinoma component only. However, partial and weak positivity for LAT1 was found even in benign prostate glands. Overexpression of LAT1 was detected in 25 (21.7%) of 115 specimens. Overexpression of LAT1 was observed in 2 (4.1%) of 49 Gleason score 2-6 cases, 3 (37.5%) of 8 Gleason score 7 cases, and 20 (34.5%) of 58 Gleason score 7-10 cases. There was no difference in overexpression of LAT1 between Gleason score 7 and Gleason score 8-10 cases. There was significant difference in overexpression of LAT1 between Gleason score 2-6 and Gleason score 7-10 cases ($P<0.0001$). In conclusion, overexpression of LAT1 is associated with tumor grade of human prostate cancer. Overexpression of LAT1 might be closely related to the prognosis of prostate cancer patients.

Human ACE Gene Polymorphisms May Be Associated With Progression In Renal Cell Carcinoma

© L A Jamieson¹, S Fleming²

¹ Ninewells Hospital and Medical School, Dundee, United Kingdom, ² University Of Dundee, Dundee, United Kingdom

A role for the activity of the renin - angiotensin pathway in the progression of renal cell carcinoma (RCC) is suggested by two observations. First, in a xenograft model, pharmacological inhibition of angiotensin converting enzyme (ACE) with subsequent reduction in angiotensin 2 (ANG2) inhibits the growth of RCC. Further clinical evidence comes from follow up data of hypertensive patients who developed malignancy. Those treated with ACE inhibitors showed lower tumour mortality than those who did not receive an ACE inhibitor. There is a 287bp insertion/deletion (I/D) polymorphism in intron 16 of the human ACE gene. This has been associated with variance in plasma and tissue concentrations of ACE, the highest concentrations being in the DD genotype. Our hypothesis is that patients who are ACE DD homozygotes and who produce higher levels of ACE should show greater tumour mortality. Forty-eight archive cases of RCC from 1998 and 1999 in Tayside were selected to enable follow up data to be obtained. DNA was extracted from formalin fixed, paraffin embedded sections of normal kidney. The ACE genotype for each case was established using published primers and PCR. Flanking oligonucleotide pairs used to characterize the I/D polymorphism anneal outside the 287bp insertion within intron 16 of the ACE gene. Owing to the preferential amplification of the D allele, mistyping of I/D heterozygotes as DD homozygotes is possible; therefore insertion specific primer pairs were used to verify each DD genotype. Analysis of the 48 cases showed 7 to be ACE II, 10 as ACE DD and 31 were ACE I/D. This distribution itself is not significantly different from controls, but when staging data is analysed 60% of tumours which are DD had progressed to greater than stage pT3 compared to 35% and 28% of the other groups. It is not yet clear whether this in turn reflects greater cancer associated mortality from this group.

HISTOPATHOLOGICAL FINDINGS ASSOCIATED WITH EXTRACORPOREAL SHOCK-WAVE LITHOTRIPSY

© LV Ffolkes, AM Winstanley, MC Parkinson
UCL Hospitals NHS Trust, London, United Kingdom

Extracorporeal shock-wave lithotripsy (ESWL) is a widely accepted, non-invasive method of treating renal stones which has been in clinical use for over 20 years. It reduces the need for open stone surgery and more than four million people have been successfully treated worldwide.

Unsuccessful non-invasive treatment of renal stones can result in chronic pyelonephritis and kidney dysfunction requiring open nephrectomy. A series of six patients are presented who were treated with ESWL and had subsequent nephrectomy, ureterectomy or bladder biopsy. The morphological appearances of kidney, ureter and bladder comprised: mineralised fragments associated with necrosis, circumscribed granulomata, some with central abscess formation, and multinucleate giant cells. In one case, appearances raised the possibility of tuberculosis which was excluded by PCR. In nephrectomy specimens the above features were seen in the hilar connective tissue, papillae and medulla. Fungal infections were excluded by special stains and the distribution of the granulomatous response was not in keeping with that of sarcoid or xanthogranulomatous pyelonephritis. Renal, ureteric and bladder parenchymal changes post ESWL is an additional cause of granulomatous lesions in the urinary tract.

Technical aspects of genotyping single dysplastic tubules from pre-neoplastic lesions of the kidney

© M Padillalamb, L. Christie, A Cassidy, S Fleming
University of Dundee, Dundee, United Kingdom

The WHO committee on pre-neoplasia has recently suggested that there is an intratubular dysplastic phase of tumour development in the kidney. To test this hypothesis we need to be able to genotype single dysplastic tubules to identify the changes characteristic of renal cell carcinoma (RCC) in these early lesions. Intratubular dysplasia can only be recognised in formalin fixed paraffin embedded histological sections which creates challenges for accurate genotyping. We tested whether it was possible to obtain information on microsatellite polymorphism from these lesions. Serial sections (X4 at 6microns) were cut and stained with H&E and taken to laser microdissection. Laser capture was performed separately on dysplastic tubules, normal kidney and RCC using an Arcturus Pixcell II microscope and the captured samples collected into DNA extraction buffer with proteinase K. DNA was amplified using primers with fluorescent dye labelling the 5' end. Primers were selected for microsatellite markers on chromosome 3p25, the site of the most frequently encountered loss in RCC. The PCR product was analysed using the ABI Prism 3100 genetic analyser which detects size differences between the PCR products with resolution at <1bp. We have successfully used this method to demonstrate the principle that genotyping can be performed on such small samples of formalin fixed laser dissected dysplastic tubules.

ARE THERE DIAGNOSTIC PROBLEMS WITH TESTIS TUMOURS?

© LV Ffolkes¹, A Freeman¹, SJ Harland², MC Parkinson¹
¹ UCL Hospitals NHS Trust, London, United Kingdom, ² Institute of Urology, UCL, London, United Kingdom

Review of testicular tumours has increased, mandated by specialist Multidisciplinary Tumour Board (MDTB) discussions of rare neoplasms. To target postgraduate teaching, our practice is reviewed to define: (1) Difficulties perceived by Pathologists submitting cases for diagnostic support and possible impact on patient management; (2) Problems not perceived by the initial reporting Pathologist but apparent on review for MDTB.

Method:

- (1) Letters and responses accompanying the last 104 consecutive testicular tumours submitted by Pathologists were reviewed.
- (2) The initial histopathology reports of the last 49 consecutive testicular germ cell tumours (GCTs) from patients referred to the cancer centre were compared with reports issued at the cancer centre.

Reasons for referral in group 1 were often multiple and included rarity of tumour; problems with subclassification; interpretive difficulties related to suboptimal fixation and immunohistochemistry. Results from group 2 showed that information essential for patient management at the cancer centre was not always provided by the initial centre e.g. Tumour size, cord status, pT stage.

It can be concluded that second opinions on testicular tumours in cancer centres are valuable and emphasis on rare testicular tumours in postgraduate seminars is justified.

Characterization And Prognostication Of Salivary Gland Tumors Using Polycomb Group Gene Expression Patterns

© H Vekony¹, FM Raaphorst², I van der Waal¹, M van Lohuizen³, E Bloemena¹

¹ Dept of Oral and Maxillofacial Surg/Oral Pathol, Academic Centre for Dentistry (ACTA), VUmc, Amsterdam, Netherlands, ² Dept of Pathology, VUmc, Amsterdam, Netherlands, ³ Division of Mol Genetics, Netherlands Cancer Institute, Amsterdam, Netherlands

A better understanding of molecular alterations in salivary gland tumor development and progression could significantly improve classification and prognostication of these tumors. Oncogenesis ultimately results in various genetic alterations that lead to loss of cell identity in tumor cells. Polycomb group (PcG) genes were recently identified to play a central role in this process. These genes are essential for maintenance of gene silencing after cell division, and contribute to regulation of normal cellular development and regulation of the cell cycle. In addition, abnormal PcG expression is believed to result in development of various human epithelial and hematological tumours. In this study, we determined PcG expression by immunohistochemistry in 24 archival formalin-fixed paraffin-embedded tissue samples of adenoid cystic carcinoma of the salivary gland. Immunohistochemical expression of several cell cycle and proliferation markers, (Mib1, p53, p16 and Cyclin D1) and of the PcG proteins BMI1, EZH2 and MEL18 was examined. Staining was scored semi-quantitatively. BMI1 was abundantly expressed in the majority of the tumors, whereas expression of EZH2 and MEL18 showed considerable variation. The tumor suppressor p16 was highly expressed despite the presence of its negative regulator, BMI1.

Papillary Mucinous Adenocarcinoma In the Hyoid Bone

IC Burnell, © AG Douglas-Jones, M Hourihan, M Robinson, A Tomkinson

Departments of Pathology, Radiology and Surgery, University of Wales College of Medicine, Heath Park, Cardiff. CF4 4XW., Cardiff, United Kingdom

An unusual case of an 8cm, midline neck mass is described. A 72 year old man presented with a rapidly growing, midline neck mass and imaging showed destruction of the hyoid bone by a 8cm partially cystic soft tissue mass. Core biopsy showed a papillary mucin secreting adenocarcinoma. Metastatic disease was excluded by imaging and immunohistochemistry revealed positivity for epithelial markers AE1/AE3 and CEA but negativity for thyroglobulin and prostatic markers.

The excised tumour showed a mucin secreting carcinoma containing cysts and with areas of glandular and papillary architecture. Bilateral neck dissection showed nodal metastases (right 5/20, left 10/21). Papillary carcinoma of thyroid arising in thyroglossal duct remnants is well described. The tumour was distinct from the CAT tumour of the base of the tongue. Glandular epithelium has been described in thyroglossal duct remnant and this may have been the origin of the tumour described.

ADENOID CYSTIC CARCINOMA IN DIFFERENTIAL DIAGNOSIS OF HEAD AND NECK TUMORS

© E Chmielik, K Woloszynska, E Stobiecka, B Szczesniak-Klusek, D Lange

Department of Tumour Pathology, Center of Oncology, M. Skłodowska-Curie Memorial Institute, Gliwice, Poland

Adenoid cystic carcinoma (ACC) is an invasive neoplasm composed of basaloid cells with predominant myoepithelial/basal cell differentiation. ACC most frequently presents in the parotid, submandibular gland and palate. ACC has marked propensity for perineural invasion. Cytologic pictures of fine-needle aspiration biopsy (FNAB) smears of distant infiltration of this neoplasm from primary focus are a source of diagnostic problems and ACC are sometimes missed in differential diagnosis.

The aim of this study was to analyze of ACC cytologic findings of FNAB from head and neck tumors (mastoid process, thyroid, cheek) in correlation with histologic findings.

Ultrasound-guided FNAB was performed by pathologist in 3 patients, smears were fixed in 95% ethanol and hematoxylin and eosin stained.

Cytologic architectural structures, size and shape of cells, character of cytoplasm, character and shape of nucleus and nuclear membrane, size of nucleolus, background of smears were analysed. Cytologic findings were compared with histologic findings of excised specimens in all patients. Cytologic differential diagnosis of ACC in particular locations was presented. Characteristic cytologic pictures in correlation with clinical data allowed to diagnose ACC and to differentiate it from other typical neoplasms for a given location.

Apoptosis In Chronic Viral Hepatitis: An Immunohistochemical Study Using Anti-activated Caspase-3 and M30 Antibody

© JL McPartland¹, MA Guzail², CH Kendall¹, JH Pringle²
¹Leicester Royal Infirmary, Leicester, United Kingdom, ²University of Leicester, Leicester, United Kingdom

Background/Aims: Apoptosis is implicated as a major pathogenetic mechanism in chronic hepatitis B and C. Previous studies of the relationship between apoptotic rates and histological necroinflammatory activity have produced conflicting results.

Methods: Hepatocyte apoptosis was assessed in liver tissue from 32 cases of chronic viral hepatitis, 7 cases of hepatocellular carcinoma and 6 cases of steatohepatitis as non-viral disease controls and 8 cases of control liver.

Apoptotic rates were measured using H&E morphological assessment and immunohistochemical staining with antibodies to activated caspase-3 and M30. Histological necroinflammatory activity of viral hepatitis cases was scored using the Knodell scoring system and the cases were divided according to their score into group 1 (mean 2.43±0.48) and group 2 (mean 7.80±0.49).

Results: Apoptotic indices were higher in group 2 than group 1 using H&E (11.53±2.70 vs 0±0, p=0.015), activated caspase-3 (22.01±5.27 vs 1.79±1.79, p=0.03) and M30 (3.80±1.74 vs 0±0, p=0.207) methods.

Conclusions: Apoptotic scores using an antibody to activated caspase-3 are significantly higher in cases of chronic viral hepatitis with greater histological necroinflammatory scores, supporting a central role for apoptosis in disease pathogenesis. This method offers an alternative to routine histological assessment for measuring disease activity.

Early Changes in Fibroblast Populations in the Furan-Induced Rodent Cholangiocarcinoma Model

© KC Hickling, JM Hitchcock, JK Chipman, JG Evans, TG Hammond

The University of Birmingham, Birmingham, United Kingdom

Cholangiofibrosis and intestinal metaplasia (IM) are early features of developing cholangiocarcinoma in both human and rodent. However the mechanism of induction of IM is poorly understood. The contribution of mesenchymal elements to the development of IM has been investigated using the furan/rodent cholangiocarcinoma model.

Furan (30 mg/kg) was administered once daily and animals were sacrificed at various time points during up to 20 days administration. Changes to the liver were followed by histological and immunocytochemical analysis.

Furan induced an initial, general, centrilobular necrosis that resolved by day 3 without evidence of mesenchymal (Ito cell) activation.

A rare focal event was extension of the necrosis to portal tracts. A chronic inflammatory response to this injury ensued, with matrix deposition and rapid proliferation of biliary/oval cell ductules commencing day 7. A heterogeneous fibroblast/fibrocyte population (as identified predominantly by desmin, GFAP, Thy-1, αSMA and Fibulin 2 staining) surrounded areas of IM that developed in these expanding ducts (day 10 to 20).

Mesenchymal cells are known to influence the phenotypic expression of adjacent parenchymal cell populations. The presence of fibroblast/fibrocyte populations, additional to the endogenous Ito cell, may induce atypical intestinal phenotypic expression within maturing biliary populations attempting repair following furan-induced injury.

Angiomyolipoma of the Liver : A Rare Cause of Large Solitary Mass

K Radotic , S Johnson , © A G Douglas-Jones
Department of Pathology, University of Wales College of Medicine, Cardiff, United Kingdom

Two cases of angiomyolipoma of the liver are presented. Both patients were women (age 40, 61) and one tumour was found incidentally, the other patient presenting with upper abdominal pain and anaemia. Ultrasound examination showed well-defined masses in the liver of mixed echogenicity. CT scan showed both masses to be highly vascular. In one case pre-operative diagnosis was suggested in core biopsy. One patient underwent hemihepatectomy and the other resection of segments 5 and 6. Both tumours were large (55 and 120mm) well circumscribed masses with variegated yellow and tan cut surface. Both tumours showed sheets of epithelioid cells whose histogenesis was revealed by immunohistochemistry. The epithelioid cells comprising the masses were SMA and HMB45 positive, but negative for AE1/AE3, CAM 5.2 and AFP with a prominent Factor 8 positive vascular component. These tumours are rare in the liver but should be considered in the differential diagnosis of large solitary masses without cirrhosis or other risk factors for hepatocellular carcinoma and only 6% are associated with tuberose sclerosis in contrast to renal tumours.

Hepatic Steatosis Is A Newly Identified Risk Factor For Hepatocellular Carcinoma In Patients With Hepatitis C Virus Infection

© AR Panigrahi¹, P Southern², C Millson², J Wyatt¹
¹ *Department of Histopathology, St James University Hospital, Leeds, United Kingdom,* ² *Department of Hepatology, St James University Hospital, Leeds, United Kingdom*

Hepatitis C is now the commonest cause of cirrhosis in the western world and has been linked with the rising incidence of hepatocellular carcinoma (HCC). Hepatic steatosis is common in hepatitis C and HCV core protein can induce hepatic steatosis and HCC in transgenic mice¹. A prospective study from Japan showed that steatosis on biopsy is an independent risk factor for future HCC in patients with hepatitis C².

Aim: to determine whether hepatic steatosis is associated with HCC in patients transplanted in the UK for hepatitis C cirrhosis

Method: We reviewed the histology of patients transplanted for hepatitis C cirrhosis between 1998 and 2004. We scored the proportion of cirrhotic nodules and of hepatocytes within nodules showing steatosis, and related this to presence of HCC, age, sex and Child-Pugh score using Chi squared tests.

Results: HCC was present in 43/128 (33.6%) hepatectomy specimens, and was associated with more than minimal steatosis (steatosis scored as >2% hepatocytes and/or >10% nodules) (p=0.005). HCC was also associated with age >48 (p=0.002) but not gender or Child-Pugh score. Steatosis was associated with low Child-Pugh score(p=0.005) but not with age or gender.

Conclusion: Our results support steatosis as a risk factor for HCC in patients with hepatitis C cirrhosis; this could be valuable in identifying patients at increased risk of HCC.

References:

- [1] Moriya K, Yotsuyanagi H, Shintani Y, et al. *J Gen Virol* 1997;78(Pt 7):1527-1531
 [2] Ohata K, Hamasaki K, Toriyama K, et al. *Cancer* 2003;97:3036-3043

Inflammatory Pseudotumour Of The Liver With Complete Resolution After Steroid Therapy

© K P Prasad , A Baird , K R Prasad
Leeds Teaching Hospitals,NHS Trust, LEEDS, United Kingdom

Inflammatory pseudotumour of the liver is a benign condition of undetermined aetiology, characterised by a localised lesion with a myofibroblastic stroma and chronic inflammatory infiltrate without anaplasia.

A 71 year male patient without any antecedent hepatic pathology presented with jaundice and abdominal pain of one month's duration. Laboratory tests showed an elevated bilirubin, alkaline phosphatase, gamma-GT and raised CRP. Tumour markers including AFP and CEA were normal. Radiological investigations performed included ultrasound, CT and MRI scans of the liver. They revealed a 10cm diameter mass at the hilum separating the right and left branches of the portal vein, but not invading them, leading to the diagnosis of an extensive tumour of uncertain nature. A needle core liver biopsy showed effacement of the normal liver architecture by the lesion, which was composed of spindle cells, macrophages, neutrophil polymorphs and polyclonal plasma cells. Special stains confirmed this, with macrophages staining with CD68 and spindle cells with vimentin and SMA. A pancytokeratin and S100 were negative. No acid-fast bacilli, fungi or bacteria were identified.

Treatment with systemic steroids was instituted. Radiological imaging three months post-treatment showed no residual liver mass. This illustrates the value of liver biopsy in diagnosis of liver tumours of uncertain nature even in this era of specialised radiologic imaging.

Do we need a minimum data set for liver biopsies?

© C E Hook , A McGregor
University Hospitals of Leicester NHS Trust, Leicester, United Kingdom

Hepatitis C (HCV) infection is a significant public health issue. Treatment of HCV uses expensive interferons, and ultimately transplantation. Guidelines on decision to treat include the appearance of liver at biopsy, with a numerical score using an approved system to assess damage. To be relevant to clinicians, histopathology reports must contain this information. We have assessed this in a retrospective audit of liver biopsies from HCV infected patients.

Using SnoMed codes, including inflammation, viral infection, HCV, cirrhosis or hepatitis, an archival search of liver biopsies from 1986 to 2004 was performed.

This strategy identified 988 biopsies from 908 patients. All cases of proven HCV and cases with no or equivocal results where clinicians had stated HCV were included, identifying 268 biopsies from 212 patients. The biopsy report for each case was reviewed for scoring and coding.

Initial results have shown that a significant number of biopsies (25%) were not scored for disease severity, and the presentation of scoring varied between pathologists. 66% of cases were not coded appropriately.

In conclusion, we have shown that a significant number of HCV biopsy reports lack information that will affect clinical management of HCV. We believe a minimum data set for reporting of HCV liver biopsies is required.

Oxaliplatin Toxicity In The Liver

© J A Kitchen , A McGregor

Histopathology department, University Hospitals of Leicester NHS Trust, Leicester, United Kingdom

Guidance issued by NICE in March 2002 recommends that oxaliplatin should be considered for use (in combination with 5FU/FA) in pre-operative chemotherapy to downstage potentially resectable colorectal carcinoma metastases in the liver. There is no literature on oxaliplatin hepatotoxicity except for a mention of altered serum liver enzyme and bilirubin chemistry in the manufacturer's datasheet. However, consequent to our own anecdotal observations, we propose that oxaliplatin causes steatosis in the liver. Identifying possible hepatotoxicity is important, as steatosis may complicate the radiological assessment, and therefore also clinical management, of disease progression.

We identified ten patients with post-oxaliplatin chemotherapy liver resections or biopsies, and a cohort of age, sex, and disease-matched patients who had not received oxaliplatin. Histological features of steatohepatitis were graded semiquantitatively.

Steatosis was noted in 80% of the 'oxaliplatin group', including one patient with no fatty changes in a pre-chemotherapy biopsy, but moderate steatosis in a post-oxaliplatin resection specimen. The prevalence of steatosis in liver transplant donors is reported at 13-25% and 30% of cases in our control group showed steatosis.

We conclude that oxaliplatin chemotherapy can cause steatosis in the liver of patients with metastatic colorectal carcinoma, a feature that may complicate subsequent radiological and clinical assessment.

Clinical And Laboratory Presentation Of Chronic Lymphocytic Leukaemia

© L A Sanni , S O'Connor , A Jack

Department of Histopathology, Algernon Firth Building, The General Infirmary at Leeds, Leeds LS1 3EX, Leeds, United Kingdom

Patients with chronic lymphocytic leukaemia (CLL), the most common adult leukaemia in the western world, can either be asymptomatic or present with lymphadenopathy, hepatosplenomegaly, and non-specific symptoms of easy fatigability, weight loss and anorexia. The diagnosis is often made by lymph node (LN) biopsy or an absolute lymphocytosis greater than $5000 \times 10^9/L$. However, the mode of clinical and laboratory presentation is a subject of controversy. We studied 67 patients (44 men and 23 women) with a primary diagnosis of CLL, made on a LN or other solid tissue. The median age of diagnosis was 70y (range 35 – 87y). Many patients had a raised lymphocyte count and LN biopsy was not essential for diagnosis. In 22% of cases (14/65), CLL was diagnosed incidentally during investigation for other malignancies. Almost all cases had a variable degree of marrow involvement (range 5-100%). The immunophenotype of IgM/D+, CD5+, CD79+weak, CD20+weak, CD23+, CD19+, CD22+, FMC7-, CD38- was present in 75% (50/67) of cases. ATM deletion, a poor prognostic marker, was present in 30% (7/23) of cases, when looked for.

Our data suggest that even in patients with lymphadenopathy, diagnosis can be made on peripheral blood and marrow examination without recourse to LN biopsy.

Immunohistochemical study on L-type amino acid transporter 1(LAT1) expression for myelodysplastic syndrome

© I. Saito ¹, K. Taki ¹, A. Sakamoto ²

¹ *Musashino Red Cross Hospital, Tokyo, Japan,* ² *Kyorin University School of Medicine, Tokyo, Japan*

Background: L-type amino acid transporter 1(LAT1) is one of the protein which plays as a transporter of amino acid for cell proliferation. In this study, we examined immunohistochemical expression for LAT1 using human bone marrow tissue with myelodysplastic syndrome.

Materials and Methods: We use 26 case tissue specimens of clinically and histologically confirmed myelodysplastic syndrome (MDS) (FAB classification) (13 refractory anaemia: RA, 7 RA with excess of blasts: RAEB, 6 RAEB in transformation: RAEB-T cases). Immunohistochemical study was done by anti-LAT1 monoclonal antibody. Evaluation was given 3 categories, namely, strongly positive, weakly positive and negative.

Results and Discussion: Positive immunoreactivity was found in the cytoplasm and cell membrane of immature myeloid blasts. As to MDS, 25 cases (96.2%) revealed strongly positive and weakly positive. One case showed negative (4.8%). More than 90% of MDS cases showed immunohistochemical reactivity. Therefore, our data suggest a close relationship between LAT1 and neoplastic lesions of bone marrow. We believe that LAT1 immunoreactivity can be applied for histodiagnosis of MDS as a useful tool.

Study of Plasmacytoid Dendritic Cells in Lymph Nodes Draining Breast Cancer by CD 123 Antibody. An Immunohistochemical and Flow Cytometry Study

© K Cox ¹, N M Aqel ², F Facchetti ⁴, H Singhal ³, M Burke ³, S C Knight ¹

¹ *Antigen Presentation Group, Imperial College, Harrow, United Kingdom,* ² *Department of Cellular Pathology, Northwick Park Hospital, Harrow, United Kingdom,* ³ *Directorate of Surgery, Northwick Park Hospital, Harrow, United Kingdom,* ⁴ *Department of Pathology II, Brescia, Italy*

Plasmacytoid dendritic cells (PDC) constitute a distinct subset of antigen presenting cells. Morphologically similar cells can be found in histological sections of reactive lymph nodes (LN), close to High Endothelial Venules (HEV) in LN paracortex.

We examined PDC in axillary LNs draining breast carcinoma by using an anti-CD123 antibody, both immunohistochemically on paraffin sections and flow cytometry. Paraffin sections from one LN of each patient were immunostained for CD 123. Cell suspensions were made from one fresh LN from each patient and then flow cytometry was employed to identify and isolate PDC. By using four-colour flow cytometry, PDC in axillary LN (n=19) were consistently identified. PDC are positive for HLA-DR & CD123 (high). They are negative for CD3, CD14, CD16, CD19, CD34, CD56 & CD11c. PDC stained strongly for CD123 in sections of LNs and were found in LN paracortex and scattered discretely in lymph node sinus system.

Our findings suggest that: **1.** Flow cytometry can be a useful tool in isolating PDC from LN, which can then be used in various functional studies **2.** PDC have been identified, for first time, in paraffin sections of LNs draining breast carcinoma using anti-CD123 antibody **3.** Identification of PDC in LN paracortex, discretely and close to HEV, confirms previous data on the localization of these cells in reactive LN **4.** The identification of PDC in LN sinuses strongly suggests that at least some PDC migrate to LNs through the afferent lymphatics.

Human Intestinal Astrovirus Infection in an Immunocompromised Child Following Bone Marrow Transplantation

© NJ Sebire, M Malone, G Anderson, N Shah, HB Gaspar, WD Cubitt

Great Ormond Street Hospital, London, United Kingdom

Introduction: Astroviruses are rare causes of diarrhoea and vomiting in infants and the elderly, and may also cause symptoms in immune compromised individuals. Despite its recognition using rt-PCR and immunofluorescence methods in faecal samples, there is almost no data on their histopathological features in humans. We report the first case describing the histopathological, immunohistochemical and ultrastructural features of astrovirus infection in a human immunocompromised patient.

Case Report. A 4 year old boy underwent bone marrow transplantation for complications of intractable enterocolitis of infancy. Approximately 6 months post-transplantation he presented with profuse diarrhoea. Investigation revealed the presence of adenovirus and astrovirus in faecal samples. Gastrointestinal biopsies were carried out to differentiate GVHD from infection as the cause of the diarrhoea. The gastric biopsies were normal. The duodenal and jejunal biopsies did not indicate GVHD, but showed villus blunting and irregularity of surface epithelium with a mild lamina propria mixed inflammatory reaction and no viral inclusions identified. Immunohistochemical staining for adenovirus was negative but staining for astrovirus demonstrated strikingly positive intestinal epithelial cells, predominantly located at the villus tips. Ultrastructurally, intracytoplasmic crystalline viral arrays were identified in surface enterocytes.

Conclusion. Astrovirus infection may be a cause of diarrhoea in immunocompromised patients. Histopathological findings may be subtle and diagnosis requires immunostaining and/or electron microscopy.

Spiral Artery Associated Restricted Growth (SPAARG): Pathophysiology and Fetal Programming Implications Resulting from Low Intervillous Pressure

© NJ Sebire¹, V Jain², DG Talbert²

¹ *Great Ormond Street Hospital, London, United Kingdom.* ² *Imperial College, London, United Kingdom*

Introduction: Failure of adequate trophoblastic conversion of maternal spiral arteries results in high flow resistance and consequent reduction in fetal oxygen supply in intrauterine growth restriction (IUGR). In addition, raised spiral artery resistance reduces placental intervillous pressure affecting maternofetal water transfer. We examine the possible effects of reduced intravillous pressure using a pathophysiological computer model.

Methods. A simulation of an experiment in which compression cuffs were placed around each spiral artery to progressively restrict flow, while observing various fetal and placental variables was carried out.

Results. In normal circumstances, water moved to the fetus in the cotyledonary core villi, and to the mother in the outer villous layers. While the fetus was able to match villous capillary pressure to changes in intervillous pressure, net transplacental water movement was minimal. When spiral artery resistance was increased sufficiently to cause mean intervillous pressure to fall below that which the fetus could match, a net flow to the mother appeared resulting in oligohydramnios and continuing until the resulting fetal blood haemoconcentration produced a sufficient increase in colloid osmotic pressure to restrict further loss.

Conclusion. Severe spiral artery flow restriction results in lowered mean intervillous pressure, net water loss from the fetus and haemoconcentration. Since systems within the developing fetoplacental unit then operate in an abnormal ionic environment, axes such as the renin-angiotensin set-point may be affected. This may be a mechanism linking uteroplacental disease and IUGR to the fetal origins of adult disease.

Alveolar Septal Collapse (ASC) in the Transitional Human Lung: A Possible Common Mechanism in Sudden Unexpected Death in Infancy (SUDI)

© NJ Sebire¹, DG Talbert²

¹ *Great Ormond Street Hospital, Department of Paediatric Pathology, London, United Kingdom,* ² *Institute of Reproductive Science, Imperial College, London, United Kingdom*

Introduction: Sudden unexpected death in infancy (SUDI) is a category used to represent the largest single group of infant deaths. We investigated a possible biomechanical mechanism which may be common in SUDI and may provide an explanation for the association of the known risk factors such as co-sleeping, prematurity, prone sleeping position, overwrapping, overheating and maternal smoking.

Methods: On the basis of previously published data on lung development, surfactant function, connective tissue strength and elasticity, capillary pressures and biomechanical functions, a dynamic computer simulation was constructed to observe the consequences of altering various parameters.

Results: Alveolar septal collapse occurs when the balance between surface tension causing them to collapse, (modified by surfactant function), is greater than support provided by capillaries and connective tissue. The pressures depend on both the surface tension itself and on the curvature of the surface such that collapse is much more likely at low volumes, which may lead to cyanosis and / or apnoea.

Conclusion: The fundamental developmental instability of the lung predisposes to ASC, the risk being modified by other factors. SUDI may represent either intrinsic abnormality in pulmonary development or surfactant function, or, the combination of overheating, non-prone sleeping position and partial airway obstruction may act synergistically to precipitate ASC and death. Risk may be further modified by developmental factors such as prematurity and environmental cigarette smoke. This hypothesis provides a plausible biomechanical explanation linking many of the apparently unrelated epidemiological risk factors for SUDI.

Surface Cautery and Contamination of Postmortem Microbiological Samples: An Audit of Paediatric Autopsies

© NJ Sebire¹, M Malone¹, J Hartley², AD Ramsay¹, RA Risdon¹

¹ *Department of Histopathology, Great Ormond Street Hospital, London, United Kingdom,* ² *Department of Microbiology, Great Ormond Street Hospital, London, United Kingdom*

Introduction: In our centre, paediatric post mortem examinations are carried out according to a comprehensive protocol, which includes collection of microbiology samples from CSF, blood, spleen and lung. Splenic and lung samples are obtained using a sterile blade and forceps, with or without preceding surface cauterisation, according to pathologist preference.

Methods. During a five-month period the microbiology results of all cases of non-forensic paediatric autopsies were reviewed and categorised according to the method used to obtain the specimen.

Results. There were 70 reports reviewed. In all cases adequate microbiological samples were obtained from multiple sites as per standard protocol, including CSF, blood and tissue. In 21 cases surface spleen and lung cauterisation and splenic swab was used (the practice of one pathologist), and in 49 cases sterile instruments were used without prior surface cauterisation of spleen or lung. In seven cases the cause of death was sepsis, with pathogenic organisms isolated from multiple sites regardless of the technique used. The majority of spleen and lung samples demonstrated growth of contaminants or commensals such as coliforms, enterococci or upper respiratory tract commensals. Splenic samples showed no growth in 10/21 (48%) following cauterisation and swab versus 12/49 (24%) with 'sterile' tissue biopsy only. ($z=1.9$, $P=0.05$), whereas lung samples were sterile in 3/21 (14%) and 5/49 (10%) with and without cauterisation, respectively. ($z=0.5$, $P=0.6$). There was no relation between contamination and death to autopsy interval. ($P=0.59$)

Conclusion. Microbiological sampling can provide essential information regarding cause of death in paediatric autopsies. Contamination is reduced using swabs versus tissue biopsy but surface cauterisation per se does not further reduce contamination risk.

The Association Between Early Gestational Age and Placental Infarction in Pregnancies Complicated by Severe Pre-Eclampsia

© NJ Sebire¹, RD Goldin², L Regan²

¹ Great Ormond Street Hospital, London, United Kingdom, ² St Mary's Hospital, London, United Kingdom

Introduction: Pre-eclampsia (PET) is a serious complication of pregnancy, which is associated with uteroplacental disease and reduced uteroplacental perfusion. One of the histological features in placentas from pregnancies complicated by PET is infarction, since this represents focal severe uteroplacental ischaemia. This study examines the relationship between gestation at induced delivery and the prevalence of histological placental infarction.

Methods: Search of a placental pathology database was carried out to identify cases in which there was induced or operative delivery on the basis of severe PET, and the clinical and pathological findings reviewed.

Results: There were 37 cases identified, (representing 4.9% of all placentas submitted). The gestational age at delivery was median 32 (range 23-39) weeks. In 16 cases (43%) non-peripheral significant infarcts were identified on histological examination. These included 13 of 20 (65%) cases requiring delivery before 34 weeks' compared to 3 of 17 (17%) requiring delivery \geq 34 weeks ($z=2.9$, two-sided $P<0.01$).

Conclusion: Histological infarction is a common feature of placentas from pregnancies complicated by severe PET. The prevalence of infarction is, however, significantly greater in cases requiring delivery at earlier gestations, even though the clinical indications for delivery were similar at all gestational ages.

Recent Experience of Diagnostic Utility of Routine and Clinically Indicated Endomyocardial Biopsies in Paediatric Heart Transplantation Recipients

© NJ Sebire¹, C MacCaulay², M Malone¹, AD Ramsay¹, P Rees², R Radley-Smith², M Burch¹

¹ Department of Paediatric Pathology, Great Ormond Street Hospital, London, United Kingdom, ² Department of Cardiology, Great Ormond Street Hospital, London, United Kingdom

Introduction: Routine endomyocardial biopsy post heart transplantation in children continues to be controversial. Despite this, it is generally accepted practice, although different centres follow different regimes. Some pediatricians feel that advances in immune suppression may have obviated the need for screening for rejection, as it is now much less common.

Methods: We retrospectively analyzed the results of endomyocardial biopsies in the last 50 transplants in our institution. We have examined the utility of biopsies performed routinely and also those undertaken when there was a clinical indication or when they were part of post-rejection surveillance.

Results: Of 123 biopsies, two biopsies did not yield adequate tissue for full analysis. There was a 10% detection of asymptomatic rejection in routine biopsies from the early stages post transplantation (6/60 biopsies). There was also a 67% detection rate of rejection for biopsies performed when it was clinically suspected (10/15 biopsies). A further two biopsies in this symptomatic group showed recurrence of Giant Cell Myocarditis, which was treated with increased immunosuppression. The results of follow up biopsies post-rejection episode were somewhat skewed by one patient who had recurrent episodes of rejection and when this patient was excluded, 11% (3/27) showed further rejection.

Conclusion: Although these results are from a small number of patients, they confirm the usefulness of endomyocardial biopsy in symptomatic and asymptomatic patients and justify continuation of the existing management policy at present.

Placental Chorionic Vein Thrombosis and Twin-to-Twin Transfusion Syndrome: Pathophysiology and Effects Using a Computer Simulation

© NJ Sebire¹, DG Talbert²

¹ Department of Paediatric Pathology, Great Ormond Street Hospital, London, United Kingdom, ² Institute of Reproductive Science, Imperial College, London, United Kingdom

Introduction: Following the report of placental pathological and clinical findings associated with sudden onset Twin-Twin-Transfusion Syndrome associated with thrombosis of a placental vein, an investigation of possible mechanisms was undertaken using computer modelling techniques.

Methods: The placental code of a computer model of TTTS was modified to allow occlusion of placental chorionic vein paths while allowing fetal hemodynamic and water diffusion phenomena to be observed, for various configurations.

Results: Presence of bi-directional artery-vein-anastomoses (AVAs), with no artery-artery-anastomosis (AAAs) is associated with a small inter-fetal pressure differential with asymptomatic but marked placento-placental circulation (PPC) of blood between fetuses. Thrombosis of a placental vein draining the major AVAs from one twin, a marked pressure differential developed and water filtration produced haemodilution in the donor and haemoconcentration in the recipient. The PPC was reduced and divergence of fetal blood Haematocrit developed. The haemoconcentration increases the recipient blood viscosity with abnormal flow in visceral small vessels and possible anoxic damage despite the increased Haemoglobin concentration.

Conclusion: Differential hematocrit values (dHct), expressed as a ratio, may be clinically useful as a marker of the underlying placental vascular pattern. Values near unity indicate either no connections or significant PPC. The higher the ratio, the greater the probability of pressure asymmetries. This study highlights the importance of detailed pathological examination of the placenta in complicated pregnancies in relation to improved understanding of the underlying pathophysiological events.

Histopathology of Open Lung Biopsies in Infants Treated with Extracorporeal Membrane Oxygenation (ECMO)

© NJ Sebire, M Malone, AD Ramsay

Department of Paediatric Pathology, Great Ormond Street Hospital, London, United Kingdom

Introduction: Extracorporeal membrane oxygenation (ECMO) is an established treatment option for severe paediatric lung disease, and diagnosis of the underlying condition may direct management, based on examination of an open lung biopsy. Interpretation may be difficult complicated because ECMO can prolong survival and allow progression of underlying lung disease in addition to ECMO-related complications such as haemorrhage and sepsis.

Methods: This study examines the histopathological features in a retrospective series of pediatric patients on ECMO in whom open lung biopsy was carried out.

Results: 22 cases were identified during a seven-year period (1996-2002 inclusive) in patients 3 days to 6 years old (median 3 weeks). 12 were biopsied at <1 month of age, 4 at 6-10 weeks' and 6 at three months to six years'. Biopsy provided adequate diagnostic material in all but one case (96%) and a definite diagnosis in 12 cases overall (55%). In those biopsied before 6 weeks of age, definite diagnosis was made in 11/12 (92%). Additional management information was provided in a further nine (45%). Changes thought to be the direct result of ECMO treatment, such as extensive intra-alveolar haemorrhage, were present in only five cases on open biopsy (23%).

Conclusion: Open lung biopsy allows histopathological diagnosis on patients receiving ECMO. Direct ECMO-related complications rarely complicate histopathological interpretation.

Congenital Cellular Mesoblastic Nephroma: Low Sensitivity for Detection of the ETV6-NTRK3 Fusion Transcript in Archival Paraffin-Embedded Material

© NJ Sebire¹, S Gibson¹, J Anderson², M Malone¹, AD Ramsay¹

¹ Department of Paediatric Pathology, Great Ormond Street Hospital, London, United Kingdom, ² Department of Molecular Oncology, Great Ormond Street Hospital, London, United Kingdom

Introduction: Congenital mesoblastic nephroma (CMN) is a common renal tumour of infancy in which the cellular variant has been reported to be associated with ETV6-NTRK3 fusion transcript also described in infantile fibrosarcoma (IFS). Recently, this fusion transcript has been detected from formalin fixed paraffin-embedded archival samples of both CMN and IFS with varying success. The aim of this study is to examine the use of RT-PCR for detection of the ETV6-NTRK3 fusion transcript in archival cases of formalin-fixed, paraffin-embedded CMN, cellular, mixed and classic types.

Methods: Cases of CMN in whom paraffin blocks were available were anonymised, H&E sections examined by two pathologists and classified as classic, cellular or mixed type. In each case, sections from a representative block were cut, RNA extracted and RT-PCR carried out according to a standard protocol to detect the ETV6-NTRK3 fusion transcript.

Results: In all 13 cases of CMN, adequate detection of β -actin housekeeper gene product was obtained confirming RNA viability of fragments up to 200bp in size. Only two cases demonstrated presence of the ETV6-NTRK3 fusion transcript including one of the four cases of CMN (25%), one of the four cases of mixed CMN (25%) but none of the five cases of classical CMN.

Conclusion: In paraffin embedded archival material, the ETV6-NTRK3 fusion transcript is detectable in a minority of cases of cellular and mixed type CMN using rt-PCR. The finding of a positive result provides diagnostic confirmation but, as with many molecular techniques, a negative result does not exclude the diagnosis, particularly if fresh tissue is not available.

Immunohistochemical Findings in Embryonal 'Small Round Cell' Tumours with Molecular Diagnostic Confirmation

© NJ Sebire, S Gibson, D Rampling, S Williams, M Malone, AD Ramsay

Department of Paediatric Pathology, Great Ormond Street Hospital, London, United Kingdom

Introduction: Diagnosis of pediatric tumors relies heavily on immunohistochemical staining of small tissue biopsies since many entities share a 'small blue cell' phenotype. Since introduction of molecular genetic analysis for detection of gene fusion products we have noted that tumors with proven molecular diagnoses can exhibit unusual patterns of immunohistochemical staining.

Methods: A panel of immunohistochemical stains was performed on sections from paediatric tumors with a 'small blue cell' phenotype in which molecular diagnostic confirmation was available. (S100, CD56, NB84, CD99 (MIC2), Bcl-2, CD117, CD34, Desmin, MNF116 and WT1).

Results: In 370 sections from 37 cases, all PNETs, with and without the presence of t(11;22), demonstrated uniform membranous staining with CD99 (MIC2) and focal staining with CD56, NB84, MNF116 and WT1. All rhabdomyosarcomas, both alveolar and embryonal, demonstrated uniform Desmin, CD56 and cytoplasmic WT1 immunostaining. DSRCTs showed positive cytokeratin staining, with half having 'dot-like' cytoplasmic desmin and WT1 positivity; some showed focal positivity for NB84, CD99 and Bcl-2. 'Undifferentiated' sarcomas showed the widest range of staining with no marker staining all cases. Neuroblastomas exhibited uniform strong staining for CD56 and NB84 and marked cytoplasmic Bcl-2 positivity. Blastematos Wilms tumors showed uniform strong membranous staining for CD56, uniform cytoplasmic staining for Bcl-2 and nuclear expression of WT1.

Conclusion: Embryonal pediatric malignancies can demonstrate apparently non-specific expression patterns for several antigens, which may reflect developmental immaturity rather than specific differentiation pathways.

An Audit of the Clinical Usefulness of Examining Bone Marrow Trephine Biopsies at Multiple Levels with CD56 Immunohistochemistry for Staging of Neuroblastic Tumours

© NJ Sebire, D Rampling, S Williams, M Malone, AD Ramsay
Department of Paediatric Pathology, Great Ormond Street Hospital, London, United Kingdom

Introduction: Detection of metastatic disease is important for staging and treatment modification in cases of paediatric neuroblastic tumour. In one case, neuroblastic tumour was not present on the initial trephine sections but a small focus became apparent in a subsequent level using immunohistochemistry. Following this case, our protocol has been to perform examination of trephine specimens for this indication at several levels with CD56 immunohistochemistry on each level.

Methods: A retrospective review of all cases of bone marrow trephine biopsies examined for the indication of neuroblastic tumour was carried out over a 17 month period.

Results: There were 56 specimens examined for determination of involvement by neuroblastic tumour during the study period. In 12 cases (21%), neuroblastic tumour was present and in 44 cases (79%) no neuroblastic tumour was present. There were no cases in which examination at multiple levels or use of routine immunohistochemistry aided either diagnosis in this series. If the index case is included, levels and immunostaining provide additional diagnostic information in a maximum of only 1.7% (95% CI 0%-9%) of such cases. The cost of levels and immunostaining (based on WELCAN units) is >200% greater than routine processing and staining, meaning it would cost at least £24,000 to possibly detect one extra case of marrow involvement. We therefore believe this is not a cost-effective protocol.

Conclusion: The routine use of multiple levels and CD56 immunohistochemistry in bone marrow trephine biopsies for assessment of involvement by neuroblastic tumour is not cost-effective and only specifically indicated use of these techniques is recommended.

Surgical Pathology of the Paediatric Larynx: A 15 Year Survey in a Specialist Children's Hospital

B Vadgama, A D Ramsay, M Malone, © N J Sebire

Great Ormond Street Hospital for Children, London, United Kingdom

Examination of laryngeal specimens constitutes a significant proportion of the general adult surgical workload, and many cases involve epithelial neoplasia. In children the clinical problems and pathological lesions involving the larynx are quite different. We have examined the spectrum of laryngeal pathology seen in a tertiary referral specialist paediatric pathology unit.

A total of 256 laryngeal and epiglottic specimens from 212 patients were retrieved from the pathology archives for the 15 year period 1998 to 2003. 31 patients (14.6%) had more than one biopsy and the patients' age at the time of biopsy ranged from one day to 17 years old (median 2.8 years). The male to female ratio was 1.3:1. Laryngeal specimens constituted less than 1.5% of the departmental workload.

The most frequent clinical indications were laryngomalacia (18), congenital lesions (15), cysts (14) and hoarse voice (8). The majority of specimens (254 cases) were biopsies and the vocal cord was the most common site. There was a total laryngectomy for fibrotic stenosis secondary to caustic soda ingestion, and a partial laryngectomy for paraganglioma. The commonest diagnoses were papilloma (48); intubation granuloma (39); cyst (20); chronic inflammation (22); acute inflammation (10 - 3 with necrosis and 1 with fungal hyphae); and 8 each of vocal cord polyps and haemangiomas. Less common conditions included rhabdomyosarcoma (3), granular cell tumour (2), severe dysplasia (1), and lipid proteinosis (1). No abnormality was seen in 20 cases.

We concluded that laryngeal pathology is relatively infrequent in the paediatric age group, but that a variety of conditions can occur at this site and that these can arise from both the epithelial and the stromal components of the larynx.

Cardiac abnormalities in a paediatric autopsy population

© R J Delaney¹, I E Moore
 Department of Pathology, Southampton University Hospitals,
 Southampton, United Kingdom

Congenital heart abnormalities are one of the most common forms of congenital malformations and heart abnormalities are encountered in a significant proportion of sudden infant deaths. In order to determine the pattern of cardiac abnormalities in our paediatric autopsies we made a retrospective review of paediatric autopsies in 1993/4 and 2001/2 with a particular objective of observing any change in type and presentation. The paediatric autopsy records were reviewed and any cardiac abnormality classified according to type and mode of presentation.

In 1993/4 98/552 paediatric autopsies showed cardiac abnormalities compared with 88/518 autopsies in 2001/2. In both groups the majority are congenital abnormalities detected following a termination of pregnancy. The significant difference between the groups is that in 1993/4 42 cases (43%) were incidental findings following termination for other reasons, compared with 21 (24%) in 2001/2 ($p < 0.01$). This can be explained by alterations in scanning technology and local training/protocols.

The commonest abnormalities are septal defects (56% vs 56%). A significant proportion is sudden cardiac deaths with no previously identified abnormality (10.2% vs 6.8%). These included acute cardiac events and undiagnosed major cardiac congenital abnormalities. Underlying chromosomal abnormalities are common although the proportion of Trisomy 21 decreased in 2001/2 (19% vs 4.5%, $p < 0.01$).

The antenatal diagnosis of a cardiac abnormality allows parents to make informed decisions about future pregnancies. Post mortem heart examination requires expertise and appropriate training, which may be significantly altered by the introduction of a new Human Tissue Bill.

Fetal DNA In The Maternal Plasma, In Early Pregnancy. Its Use As A Marker Of Abnormal Pregnancy.

© A Crowley¹, O Sheils², C Martin², P Fitzpatrick³, C O'Herlihy¹, J O'Leary², B Byrne⁴

¹ University College Dublin, Department Of Obstetrics and Gynaecology, Dublin, Ireland, ² Trinity College Dublin, department of Pathology, Dublin, Ireland, ³ University College Dublin department of Epidemiology, Dublin, Ireland, ⁴ Royal College of Surgeons in Ireland, department of Obstetrics and Gynaecology, Dublin, Ireland

Fetal trafficking refers to the transfer of cells and free fetal DNA into the maternal circulation in pregnancy. Increased trafficking has been detected in pre-eclampsia (PET) and intrauterine growth restriction (IUGR), which are associated with significant risk of maternal and perinatal morbidity and mortality. The aim of this study was to quantify free fetal DNA in early pregnancy in the plasma of women whose pregnancies were subsequently complicated by IUGR or PET compared to normal pregnant controls.

1993 women were recruited at their booking visit (<20 weeks), a 5ml peripheral blood sample taken and plasma separated. The SRY gene specific to the Y chromosome was used as a fetal marker. DNA was extracted and real time quantitative PCR applied for the SRY and β -actin housekeeping gene. Data was expressed as genome equivalents (gq)/ml. Data from abnormal pregnancies were compared separately with controls using the χ^2 test, Wilcoxon rank sum test and logistic regression.

All women in the study delivered a male fetus. 36 subsequently developed IUGR and 16 PET. 72 with uncomplicated pregnancy were identified as controls. There was no difference between age or gestation at sampling between study groups. Parity was significantly higher in controls than PET patients. Significantly more women in our IUGR group smoked compared to our control group ($p = 0.004$). The SRY gene was detected in 86% of IUGR, 94% of PET and 78% of control samples. Median gq/ml of SRY were not increased in women with IUGR (28gq/ml) or PET (30.5gq/ml) compared to controls (27.5gq/ml). β -actin was significantly increased in the IUGR group compared to control ($p = 0.045$). The significant differences remained after adjustment for age, parity, cigarette and alcohol consumption. In conclusion fetal DNA in the maternal plasma in early pregnancy does not appear useful as a predictor for IUGR or PET.

High Resolution Microarray CGH And MLPA Analysis For The Cytogenetic Evaluation Of Two Pediatric Cases: Ring Chromosome 19 And Partial Duplication 2q.

© MAJA Hermsen¹, M Tijssen², I Hernando Acero³, GA Meijer⁴, B Ylstra², J Fernández Toral³

¹ Otorinolaryngology, Instituto Universitario de Oncología del Principado de Asturias, University of Oviedo, Oviedo, Spain, ² Microarray Facility, VU University Medical Center, Amsterdam, Netherlands, ³ Dept. Genetics, Hospital Universitario Central de Asturias, Oviedo, Spain, ⁴ Dept. Pathology, VU University Medical Center, Amsterdam, Netherlands

A detailed analysis of the congenital chromosomal changes in two pediatric patients was performed using high resolution genetic analysis techniques, microarray comparative genomic hybridization (array CGH) and multiplex ligation-dependent probe amplification (MLPA). Case 1 was a girl of 25 months, with hypomelanosis of Ito but no other developmental abnormality. She carried a ring chromosome 19 which we found not to have resulted in loss of subtelomeric sequences, ruling out the possibility that a small telomeric loss was causally related to this patient's phenotype. We suggest that her skin abnormalities are the result of genetic mosaicism. Case 2 was a 9 year old girl with facial anomalies and mild growth and mental retardation carrying an addition on chromosome 2p. We found that the addition was duplicated 2q35-qter and had not resulted in loss of 2pter. Together with literature data, we hypothesize that pediatric patients with 'pure' trisomy 2q including bands 2q35-2q37.1 may have a moderate clinical phenotype as opposed to patients with duplications proximal to 2q33 or duplications 2q3 with accompanying distal deletion. These data illustrate the additional value of new, high resolution genetic analysis techniques for a more precise characterization of the phenotype/genotype relationship in childhood chromosomal disorders.

A Case Of Arrhythmogenic Right Ventricular Dysplasia In An Eight Year Old

© CA Robinson¹, IE Moore

Southampton University Hospitals NHS Trust, Southampton, United Kingdom

Arrhythmogenic Right Ventricular Dysplasia (ARVD) is a disorder characterized by progressive segmental or diffuse fibro-fatty replacement of the right ventricular myocardium. It has been estimated to affect one in 5,000 people and accounts for 1-20% of cases of sudden cardiac death. ARVD is familial in at least 30% of cases, most commonly with an autosomal pattern of inheritance. However it is uncertain whether ARVD is a purely genetically determined congenital malformation or a healed form of myocarditis. Major clinical manifestations of ARVD include heart failure and arrhythmias, which can lead to sudden death. Although ARVD has been described in children, it is significantly more common in adolescents and young adults, with the average age of patients diagnosed being 30 years. We report a case of ARVD presenting in a previously well 8 year old boy as a sudden cardiac death, and review the literature examining the incidence, pathogenesis, diagnosis, clinical features and pathology seen in this condition when it occurs in childhood.

Spectrum Of Tonsillar Pathology In A Paediatric Referral Centre: Correlation Of Histopathological Findings With Clinical Asymmetry

B Vadgama, © N J Sebire, M Malone, A D Ramsay
Great Ormond Street Hospital, London, United Kingdom

Tonsils are commonly encountered surgical specimens in general histopathology departments. Tonsillectomy is advocated less frequently now and clinical indications are more restrictive. In adults, a unilaterally enlarged tonsil is an indication for surgery. Physiological hypertrophy is maximal between the ages of 2 and 5, making clinical assessment difficult in a child. We examined the spectrum of tonsillar and adenoidal histopathology in a specialist paediatric unit and assessed the correlation with the clinical details provided.

We searched the histopathology computer database (1990–2003) for all archived reports coded as tonsils and/or adenoids. Over 13.3 years, 120 surgical episodes were identified involving 119 patients. 111 were locally resected (age range 1–17 years). The most common clinical details given were: tonsillar asymmetry (17), obstructive sleep apnoea (12), tonsillar hypertrophy (12), recurrent tonsillitis (11) and lymphadenopathy (7). 15 patients had known haematological disorders including 10 with previously diagnosed lymphomas. Bilateral tonsils alone (55) were by far the most common type of specimen, followed by unilateral tonsils (16) and combined bilateral tonsils with adenoids (13). 9 were referred slides sent for second opinion. Non-specific follicular hyperplasia was seen in 74 cases and chronic tonsillitis confirmed in 8 cases. Other diagnoses included: lymphangioma (4), storage disease (3) and viral adenopathy (2). 7 malignant diagnoses comprised lymphomas (5), rhabdomyosarcoma and alveolar soft part sarcoma. In 17 cases of clinical asymmetry, 1 showed lymphoma, 4 acute or chronic tonsillitis and 12 follicular hyperplasia.

This study highlights the poor correlation of childhood tonsillar asymmetry with unfavourable histopathological findings.

Malaria in Kenya: Elective Report from Clinico-Pathological Experiences in the Delivery Room and Paediatric Ward.

© S. Kassam¹, S. Nesbitt², E. Sequeira³, S. Sayed⁴, C. Gontier⁴, A. Wasunna⁵, J. Odondi⁶, T. Mboya Okeyo⁷, N. Oster⁸, P. Soothill⁹, C. Sergi¹⁰

¹ Dept. Paed. Pathology, Bristol, United Kingdom, ² Dept. of Paediatrics, Gertrude's Garden Children's Hosp., Nairobi, Kenya, ³ Dept. of Obs. & Gyn., Aga Khan Hosp., Nairobi, Kenya, ⁴ Dept. of Pathology, Aga Khan Hosp., Nairobi, Kenya, ⁵ Dept. of Paediatrics & Child Health, Univ. of Nairobi, Nairobi, Kenya, ⁶ Trust HQ, Nyanza Provincial Hosp., Kisumu, Kenya, ⁷ Dept. DSRS, Ministry of Health, Nairobi, Kenya, ⁸ Dept. of Parasitology, Inst. of Hygiene, Univ. of Heidelberg, Heidelberg, Germany, ⁹ Dept. of Obs. & Gyn., Univ. of Bristol, Bristol, United Kingdom, ¹⁰ Inst. of Pathology, Univ. of Innsbruck, Innsbruck, Austria

Aims: Malaria represents the fifth most important cause of illness among the world's poorest population. It has been estimated that an average of 300 million clinical cases of malaria occur every year at any one time, 90% of this burden being in Africa. The first author (SNK) conducted an elective research rotation in a malaria-endemic region in the West of Kenya. The aim was to study materno-fetal complications of malaria infection during pregnancy.

Methods: Ninety malaria-infected and non-infected pregnancies were studied using statistical and clinical methods. Ethical approval was obtained from the Ministry of Health, Kenya and regional Hospitals. Patients provided written, informed consent.

Results: 43% of patients under the age of 20 years had fever in the last four weeks of pregnancy. 24% of low birth-weight babies (<2500g) were born to mothers under 20 years of age, as compared to (7%) in the older age groups. The age-distribution for fever in the last four weeks of pregnancy peaked between 20–22 years.

Conclusions: Previous studies have found a number of risk factors associated with malaria infection during pregnancy. Of the variables analysed in this study, preliminary data has confirmed two materno-fetal complications of placental malaria, namely pre-term labour and low birth weight infants.

Identification of Two Types of Ductal Types Malformations in Meckel Syndrome By Computer-based Image-Analysis System

© S. Adam², Ph. Kahl², H.F. Otto², C. Sergi¹

¹ University of Innsbruck, Innsbruck, Austria, ² University of Heidelberg, Heidelberg, Germany

Aims: The ductal plate malformation in Meckel syndrome might occur through two histologic types: the first one (I) with cystic dilatation of the primitive biliary structures and little intraportal fibrosis and the second one (II) with pronounced intraportal fibrosis and no or little dilatation of the primitive biliary structures. To support this hypothesis, we studied the liver in fetuses with Meckel syndrome (14 type I, 7 type II).

Methods: Anti-pan-cytokeratins (AE 1+3) Mo-Abs and the avidin-biotin-peroxidase technique (Vectastain Elite ABC kit, Vector, Burlingame, CA) were used. A computer-based image-analysis system was used consisting of the following components: a light microscope (Zeiss, Jena, Germany), CCD greyscale video camera (Sony CCD-IRIS, Sony Corp., Cologne, Germany), BNC cable hook-up, an Intel-based personal computer equipped with video frame grabber card, a Windows 3.11 operating system, Bioscan Optimas version 5.2 software (Bioscan, Edmonds, WA) running in interlaced mode, a 20" colour monitor (GDM, 2063 MS, Stimmiller, München, Germany), and a drawing pad (Wacom™ digitizer II) equipped with an induction mouse.

Results: The amount of connective tissue obtained by subtracting the surface values of the portal vein, portal artery and biliary structures to the portal tract surface was greater in type II than type I (ratio connective tissue area / portal tract area: 0.54 [type I] vs. 0.88 [type II]). The ratio between the area of all biliary structures and the area of portal tracts was lower in type II than type I lesions (0.37 [I] vs. 0.07 [II]).

Conclusions: Two types of ductal plate malformation may probably be identified in Meckel syndrome.

Agnathia-Otocephaly Complex: Presentation of Four Cases

© C. Schiffer¹, G. Tariverdian¹, M. Schiesser², C. Sergi³

¹ Gen. Pol., Inst. Human Genetics, Univ. Heidelberg, Heidelberg, Germany, ² Dept. Obs. & Gyn., Univ. Heidelberg, Heidelberg, Germany, ³ Inst. of Pathology, Univ. Innsbruck, Innsbruck, Austria

Aims: Agnathia-Otocephaly Complex (AOC) is a lethal malformation complex characterized by absence of the mandible, microstomia, aglossia, and positioning of the ears toward the midline. We report four sporadic cases of AOC with different associated features of embryonic maldevelopment.

Methods: Ultrasound and morphological data were examined in detail. In one case the maxillo-facial structures were cut serially and studied collectively and individually in a multiplanar fashion.

Results: The study of these cases supports the concept that an altered embryologic development might have taken place at Carnegie stages 10 (embryonic days 22 or 23) and 11 (embryonic days 23–26).

Conclusions: The differentiation of somites into sclero-, myo-, and dermatomes is under the influence of inductive signals from surrounding tissues. The association of agnathia and otocephaly may likely be interpreted as the result of different causal events acting simultaneously on a coordinated temporal and spatial embryologic unit, including the prosencephalon and first branchial arch. Twisted gastrulation mice show a striking similarity to the human phenotype.

Intraocular Ectopic Ependymoma - The Significance of Electron Microscopy in Its Diagnosis

© L Hegyi¹, J Moss¹, D Peston¹, M Theodorou², J Olver², F Roncaroli³

¹ Department of Histopathology, Charing Cross Hospital, Hammersmith Hospitals NHS Trust, London, United Kingdom, ² Department of Ophthalmology, Charing Cross Hospital, Hammersmith Hospitals NHS Trust, London, United Kingdom, ³ Department of Neuropathology, Faculty of Medicine, Imperial College, London, United Kingdom

We investigated a tumour arising in the eye of a 33 years old man. The patient was presented in October 2003 with painful phthisical right eye, which was enucleated. Following routine formalin fixation and tissue processing, paraffin embedded sections of the eye were examined. Immunohistochemistry was performed. Selected areas of the tumour were subjected to electron microscopy (EM).

We found that the tumour occupied about one third of the eye involving the posterior retina and choroid. It was composed of cellular areas with elongated fusiform cells, which focally formed perivascular rosette like structures and cystic spaces filled with eosinophilic material. Metaplastic bone was also present. Some neoplastic cells contained intracytoplasmic lumens. The tumour cells expressed S-100, GFAP and EMA. Particularly, EMA highlighted cytoplasmic lumens. The reactions for smooth muscle-actin, NSE and collagen IV were negative. EM showed few desmosome-like and intermediate junctions, and lumens, which contained numerous microvilli. Occasional cilia, ciliary basal bodies and ciliary basal rootlets were seen. Stacks of short profile of granular endoplasmic reticulum were conspicuous. These EM features were characteristic of ependymoma.

To our knowledge, we present the first case of intraocular ectopic ependymoma. We suggest that this tumour might have arisen from retinal Müller cells.

The Expression of Calbindin 1 and 2 Proteins in Human Tissues and Common Tumours Outside the Central Nervous System

© SS Cross¹, FC Hamdy², I Rehman²

¹ Academic Unit of Pathology, Division of Genomic Medicine, School of Medicine & Biomedical Sciences, University of Sheffield, Sheffield, United Kingdom, ² Academic Urology Unit, Division of Clinical Sciences, School of Medicine & Biomedical Sciences, University of Sheffield, Sheffield, United Kingdom

The calbindins are members of the EF-hand type calcium binding protein family which includes some proteins that have abnormal patterns of expression in human cancer. Calbindin 1 has shown to be expressed in the mammalian brain but there do not appear to be any published studies describing its distribution in human tissues, or common tumours, outside the central nervous system. We have performed an immunohistochemical survey of calbindin expression on a custom made tissue array containing 291 tissue cores representing 28 human tissue types and 21 different tumour types. All the cores showed negative staining for calbindin 1 apart from 2 cores of renal cortex where there was strong positive cytoplasmic staining in specific areas of the tubules which on H&E morphology appear to be proximal convoluted tubules. Calbindin 2 showed weak cytoplasmic staining in the renal tubules, 3/50 breast cancers and 1/4 colorectal cancers but in no other tissues. From this survey it appears that outside the central nervous system calbindin 1 is only expressed in renal tubules. This specificity suggests that urinary analysis of calbindin 1 could be a specific test for renal tubular damage. This survey only included one case of renal cell carcinoma, it would be informative to look at many more cases of this tumour type to determine whether calbindin 1 is a marker of the specific tubular origin of some of these cancers.

The Role Of Lymphatics In Tumour Growth In Bone

© JR Edwards¹, DG Jackson², NA Athanasou¹

¹ Nuffield Department of Orthopaedic Surgery, University of Oxford, Oxford, United Kingdom, ² MRC Human Immunology Unit, Weatherall Institute of Molecular Medicine, University of Oxford, Oxford, United Kingdom

Lymphangiogenesis occurs in some human cancers e.g. head and neck and may play a role in promoting lymph node metastasis. Lymph node metastasis rarely occurs in bone sarcomas and histological evidence of lymphatics in bone has not been reported. In order to determine whether primary benign and malignant tumours of bone induce lymphangiogenesis and whether carcinomas metastasise to bone via lymphatics, we immunostained benign and malignant primary and secondary tumours of bone with the lymphatic endothelial cell marker LYVE-1. The intraosseous component of primary benign and malignant tumours of bone contained no LYVE-1+ lymphatic vessels. However, some bone tumours (e.g. osteosarcoma, giant cell tumour of bone) which had spread into surrounding soft tissue contained LYVE-1+ lymphatics in the periosteum and occasionally between sub-periosteal reactive bone trabeculae. Lymphatic vessels were also not identified in the intraosseous component of secondary carcinomas that had metastasised to bone. We conclude that intraosseous lymphangiogenesis does not occur to any great extent in primary bone tumours and that there is no evidence of lymphatic spread of cancers metastasising to bone. Lymphatic vessels were seen in periosteal/sub-periosteal reactive bone of tumours showing extraosseous extension where they may represent a response to tumour growth.

Rapid Up-regulation of Cyclo-oxygenase 2 (COX-2) by 5-Fluoruracil (5-FU) in Human Solid Tumours

F Di Nicolantonio¹, S Mercer¹, LA Knight¹, FG Gabriel¹, PA Whitehouse¹, S Sharma¹, A Fernando¹, P Bhandari², SS Somers¹, SK Toh¹, © IA Cree¹

¹ Translational Oncology Research Centre, Queen Alexandra Hospital, Portsmouth, United Kingdom, ² Solent Centre for Digestive Diseases, Queen Alexandra Hospital, Portsmouth, United Kingdom

Inhibition of COX-2 has been associated with reduced growth of malignant cells. Current therapy of gastro-intestinal carcinomas involves the use of 5-FU-based chemotherapy, and we therefore studied the effect of this agent on the expression of COX-2 in 20 oesophago-gastric carcinomas before and after ECF chemotherapy by quantitative RT-PCR. We included up to four housekeeping genes that did not show significant changes following exposure of cells to cytotoxic agents to ensure accurate comparison of results from different samples. Relative expression increased 5-fold ($p < 0.02$), with some variation between patients with paired data. To determine whether these effects might occur rapidly after the start of chemotherapy, we exposed tumour-derived cells from 7 oesophageal, 10 colorectal, and 13 breast carcinomas to drugs in short-term cell culture. COX-2 expression was increased by 6-day exposure to 5-FU in tumour-derived cells exposed to drugs in vitro. After exposure to 5-FU for six days, cells from 13 breast cancers all up-regulated COX-2 mRNA with a median 24-fold increase. In 9/10 colorectal tumour samples the *ex-vivo* treatment with 5-FU produced a greater than 2-fold increase of COX-2 mRNA levels. In contrast, after irinotecan treatment, we observed a 2.7 down-regulation of COX-2 in all 7 colorectal samples analysed ($p < 0.016$). This provides a molecular rationale for clinical trials of combination chemotherapy with drugs causing COX-2 inhibition.

The Quantity and Quality of DNA in Formaldehyde Versus BoonFix® Paraffin Blocks

© M.E. Boon¹, H. Korporaal¹, G.C. Kramer¹, C. van Haaften¹, L.P. Kok²

¹Leiden Cytology and Pathology Laboratory, Leiden, Netherlands, ²Neuro Imaging Center, Biomedical Engineering, University of Groningen, Groningen, Netherlands

Paraffin-embedded tissues are in principle a source of DNA. Very little fundamental data exist as to the magnitude of the problem of fixation-induced reduction of extractability and amplifiability. The aim of our study was to establish the effects of fixation on the quality and quantity of DNA extracted from paraffin-embedded tissue samples. The results of formaldehyde were compared to those of the commercially available formaldehyde-free coagulant fixative BoonFix® (Finetec, Japan).

The tissue was divided into samples of standard size, fixed, and processed to paraffin blocks. DNA samples were prepared from 4 micron paraffin sections. All results of PCR reactions for the β globin target gene were normalised to % of values achieved with fresh unfixed tissue at 24 hours suspension in physiological saline at 4°C. The results, stratified by length of time in the fixative, are summarised in the Table.

Fixation time (%)	Formaldehyde		BoonFix®			
	DNA extraction (%)	DNA fragmentation	DNA amplification (%)	DNA extraction (%)	DNA fragmentation	DNA amplification
12 hrs	71		+/-			64
	91		-			87
24 hrs	43		+			48
	x		+/-			84
48 hrs	35		++			26
	93		+/-			81

Both by quantity and quality, β globin DNA in paraffin blocks is better preserved when the tissue is fixed in BoonFix®. DNA extractability is less influenced by fixation time of the tissue (BoonFix® being superior) than DNA amplifiability.

Improvement of the Detection of Integrated HPV by In situ Hybridisation

© AHN Hopman¹, MA Kamps¹, F Smedts², E-JM Speel¹, FCS Ramaekers¹, CS Herrington³

¹University of Maastricht, Maastricht, Netherlands, ²Foundation of Collaborating Hospitals of Eastern Groningen, Winschoten, Netherlands, ³University of St Andrews, St Andrews, United Kingdom

Estimates of the prevalence of HPV integration in CIN II/III range from 5 to 100% using different PCR based and in situ hybridisation (ISH) approaches. It has been suggested that HPV integration can be identified using ISH and scoring of punctate signals but sensitive fluorescence ISH (FISH) methods allow the detection of single copies of HPV complicating the distinction between integrated and single episomal copies. We therefore used two different pre-treatment protocols for FISH: a mild protocol that retains episomal copies more efficiently; and a harsh protocol that extensively removes proteins, episomal virus, and RNA but not chromosomal DNA. Omission of HPV DNA denaturation and inclusion of a RNase pre-treatment step were also investigated. Comparison of the FISH patterns and fluorescence intensity obtained with both protocols in a series of CIN II/III lesions and invasive cervical carcinomas showed that HPV RNA is frequently detected in addition to episomal/integrated HPV DNA using the mild protocol. HPV RNA contributed significantly to the overall HPV signal, resulting in a granular/diffuse pattern in the majority of CIN III lesions. It was therefore difficult to distinguish integrated HPV and RNA transcripts from episomal/integrated HPV. However, the harsh protocol unmasked integrated virus more efficiently: the punctate pattern was more consistent and was present in cells throughout the thickness of the squamous epithelium. As the mild protocol often gives inconclusive patterns, the harsh protocol appears to be a better method for the detection of integrated virus. Furthermore, using this protocol, integration in CIN III lesions correlates with the presence of invasive carcinoma.

Reduction of the Quantity and Quality of DNA in Archived Formaldehyde-Fixed Paraffin Blocks

© C. van Haaften, H. Korporaal, G.C. Kramer, M.E. Boon
Leiden Cytology and Pathology Laboratory, Leiden, Netherlands

Paraffin-embedded tissues are stored in pathology archives. Little research is carried out concerning the problem of loss of extractability and amplifiability of DNA in archived formaldehyde-fixed paraffin blocks. The aim of our study was to assess the quality and quantity of DNA in such blocks stored for one year in the pathology research archive.

The tissue was divided into samples of standard size, fixed, and processed to paraffin blocks. DNA samples were prepared from 4 micron paraffin sections. All PCR results for the β globin target gene were normalised to % of values achieved with fresh unfixed tissue at 24 hours suspension in physiological saline at 4°C. The results, stratified by length of time in the fixative, are summarised in the Table.

Fixation time (%)	Blocks cut after 24 hrs		Blocks stored for 1 year			
	DNA extraction (%)	DNA fragmentation	DNA amplification (%)	DNA extraction (%)	DNA fragmentation	DNA amplification
12 hrs		71		+/-		64
		65		++		23
24 hrs		43		+		48
		35		+++		15
48 hrs		35		++		26
		26		+++		7

Both the quantity and the quality of β globin gene DNA in paraffin blocks is further reduced after 1 year storage. Amplifiability particularly can become very low, which might be crucial when the tissue contains a low quantity of any target DNA. It should be remarked that the degradation of DNA is dependent on the cross-linking effect of formaldehyde.

Localisation Of The Putative Mediator of Host Defence, SPLUNC1, in Human Tissues

© L. Bingle¹, W.A. Wallace², S.S. Cross¹, A.S. High³, D.A. Devine³, C.D. Bingle¹

¹University of Sheffield, Sheffield, United Kingdom, ²University of Edinburgh, Edinburgh, United Kingdom, ³University of Leeds, Leeds, United Kingdom

This study describes, for the first time, the precise cellular location of SPLUNC1 a member of a novel family of proteins (PLUNC). SPLUNC1 is one of the most highly expressed genes of the upper airways, the protein is found in sputum and nasal secretions suggesting a role in host defence. A number of tissue microarrays alongside sections from all levels of the respiratory tract have been studied. In the upper airways, mucous cells of submucosal glands stained strongly with some staining in goblet cells of the ducts and surface staining of ciliated epithelium. The intensity of staining varied across different samples and was limited in peripheral lung. Strong staining was seen in nasal glands being weaker in epithelial cells. Mucous cells in minor salivary glands of the tongue, oral mucosa and surrounding the tonsils stained intensely and weaker in some mucous cells of major glands. Serous cells were always negative. SPLUNC1 was also expressed in the secretory epithelium of all fallopian tube samples studied, 42% of endocervix samples, 42% of colorectal adenocarcinomas and 6% of breast tumours. These studies suggest that SPLUNC1 may be an active component of epithelial defences of the lung, nose, mouth and female reproductive tract.

The Expression of S100A6 Protein in Human Tissues and Common Tumours Outside the Central Nervous System

© SS Cross¹, FC Hamdy², I Rehman²

¹ Academic Unit of Pathology, School of Medicine & Biomedical Sciences, University of Sheffield, Sheffield, United Kingdom, ² Academic Urology Unit, School of Medicine & Biomedical Sciences, Sheffield, United Kingdom

S100A6 is a member of the EF-hand type calcium binding protein family which includes some proteins that have abnormal patterns of expression in human cancer. The expression of S100A6 has not been systematically described in human tissues and common cancers. We have performed an immunohistochemical survey of S100A6 expression on a custom made tissue array containing 291 tissue cores representing 28 human tissue types and 21 different tumour types. S100A6 was expressed in both the nucleus and cytoplasm in cells where it was present. It was expressed in many epithelia including ciliated columnar epithelium, glandular epithelium lining the gut, ducts in the salivary glands, the endocervix, epithelia in the kidney, biliary epithelium, but it was not expressed in the squamous epithelium of the skin nor the endometrial epithelium. It was also expressed in melanocytes, nerve sheath cells, Leydig cells in the testis, and endothelial cells (especially within tumours). In neoplasia it was expressed in colorectal, ovarian, breast, bladder transitional cell and some squamous cell cancers but was entirely absent in cutaneous basal cell carcinomas. This widespread expression suggests that it does not have a role as a marker in diagnostic histopathology but the mechanism of its overexpression in cancers whose background epithelia do not express it (e.g. squamous epithelium) may be interesting.

S100A9 Protein is Overexpressed in Human Breast and Squamous Cell Cancers

© SS Cross¹, FC Hamdy², I Rehman²

¹ Academic Unit of Pathology, School of Medicine & Biomedical Sciences, University of Sheffield, Sheffield, United Kingdom, ² Academic Urology Unit, School of Medicine & Biomedical Sciences, University of Sheffield, Sheffield, United Kingdom

S100A9 (calgranulin B) is a member of the EF-hand type calcium binding protein family which includes some proteins that have abnormal patterns of expression in human cancer. S100A9 commonly forms a heterodimer with S100A8 and is expressed in neutrophils and macrophages, its expression in other tissues has not been systematically investigated. We have performed an immunohistochemical survey of S100A9 expression on a custom made tissue array containing 291 tissue cores representing 28 human tissue types and 21 different tumour types. There was expression of S100A9 in all squamous epithelium, all squamous cell carcinomas (both *in situ* and invasive) and 28% of 40 breast cancers. The expression in breast cancers is unexpected and has not been described before. Further investigation is required to see if this expression relates to prognosis and whether it is due to epigenetic factors (such as methylation) or genetic derangement of the q21 region of chromosome 1, the site of the majority of S100 genes.

S100A8 Protein is Expressed in Neutrophils, Macrophages, Some Breast Cancers and Some Squamous Cell Cancers

© SS Cross¹, FC Hamdy², I Rehman²

¹ Academic Unit of Pathology, School of Medicine & Biomedical Sciences, University of Sheffield, Sheffield, United Kingdom, ² Academic Urology Unit, School of Medicine & Biomedical Sciences, University of Sheffield, Sheffield, United Kingdom

S100A8 (calgranulin A) is a member of the EF-hand type calcium binding protein family which includes some proteins that have abnormal patterns of expression in human cancer. S100A8 commonly forms a heterodimer with S100A9 and is expressed in neutrophils and macrophages, its expression in other tissues has not been systematically investigated. We have performed an immunohistochemical survey of S100A8 expression on a custom made tissue array containing 291 tissue cores representing 28 human tissue types and 21 different tumour types. There was expression of S100A9 in 2 cases of cutaneous squamous carcinoma *in situ*, 1 invasive squamous cell carcinoma of the uterine cervix and 12% of 41 breast cancers. The expression in breast cancers is unexpected and has not been described before. Further investigation is required to see if this expression relates to prognosis and whether it is due to epigenetic factors (such as methylation) or genetic derangement of the q21 region of chromosome 1, the site of the majority of S100 genes.

Microsatellite Genotyping to Compare Loss of Heterozygosity in Choriocarcinomas and Placental Site Trophoblastic Tumours

B Burke¹, J Moss², © NJ Sebire², MD Hodges¹, RA Fisher¹

¹ Imperial College London, London, United Kingdom, ² Charing Cross Hospital, London, United Kingdom

Our objectives were to analyse a series of choriocarcinomas and placental site trophoblastic tumours (PSTTs) in order to refine the regions of chromosomal loss previously described in choriocarcinomas and investigate these regions in PSTTs. The PixCell II LCM system was used to capture tumour and maternal tissue from H&E stained sections of formalin-fixed, paraffin-embedded blocks. DNA was then extracted and fluorescent microsatellite genotyping performed to assess the quality of the DNA and confirm the gestational origin of the tumour. Tumour tissue was successfully microdissected and adequate DNA for analysis prepared in ten tumours that were shown to have arisen in a complete hydatidiform mole and twenty-five tumours originating in non-molar pregnancies. A panel of microsatellite markers were then used to investigate loss of heterozygosity (LOH) for the chromosomal regions 7p12-q11.23¹ and 8p21-p22² in these tumours. No homozygous deletions were identified in post-mole tumours for either region. In tumours that developed in non-molar pregnancies LOH for 7p12-q11.23 was rare in both choriocarcinomas and PSTTs. LOH for 8p21-p22 was found in a subset of choriocarcinomas, but not in PSTTs. In conclusion this study does not support the previous observation that LOH for chromosome 7 may be important in the development of trophoblastic tumours.

Matsuda et al; 1997, *Oncogene* 15: 2773-81.

Ahmed et al; 2000, *Cancer Genet Cytogenet* 116: 10-15

Ubiquitination and NF κ B Pathway Play a Key Role during Follicular Thyroid Tumorigenesis

S Arif¹, A Blanes², © SJ Diaz-Cano³

¹ Barts and The London NHS Trust, London, United Kingdom, ² University of Malaga School of Medicine, Malaga, Spain, ³ King's College Hospital, London, United Kingdom

No study correlates the gene expression profile of follicular thyroid carcinomas (FTC) with the tumour phenotype and PPAR γ status.

We selected 9 hyperplastic nodules, 22 adenomas, 14 minimally-invasive FTC, 24 widely-invasive FTC, and 13 anaplastic carcinomas (AFIP criteria). Histological evaluation included anisokaryosis, chromatin, nucleolus, pleomorphism, N/C ratio, necrosis, stromal changes, and tumor interstitial lymphocytes (TIL). Variables were studied regarding the histological diagnosis and considered significant if $P < 0.05$. Total RNA was extracted from 22 normal thyroid specimens and 59 FTC and was reverse transcribed into cDNA which was used to synthesize cRNA. Labeled cRNA was hybridized to the human GeneChip set. Cross-validated microarray gene expression was performed using and expression factor ≥ 2 and significance ≤ 0.01 , and correlated with PPAR γ expression.

TIL were absent in 68/73 (93%) neoplasms, regardless of histologic subtype. Minimally invasive FTC were distinguished from adenomas by conspicuous nucleolus, increased nuclear/cytoplasmic ratio and coexistence of apoptosis and myxoid changes in adenomas. The most specific variables of high-grade carcinoma were the presence of coagulative necrosis, hyperchromatic nuclei, and nuclear pleomorphism. Cross-validated microarray gene expression showed up-regulation of malate dehydrogenase 1 and down-regulation of ubiquitin C and sequestosome 1 in FTC. PPAR γ over-expression in FTC correlated positively with p38MAPK expression and negatively with F-Box complex ubiquitination pathway (CDC34, SKP1/2), RAS family GTPase in the endocytotic machinery (RAB7) and NF κ B pathway (I κ B α , TNF α and IL6).

Down-regulation of ubiquitination of cellular proteins is a crucial feature during the transformation of follicular thyroid cells. PPAR γ signaling pathway in FTC plays a key role in this down-regulation and contributes to the tumor phenotype through p38 MAPK (\uparrow proliferation) and NF κ B pathways (\downarrow inflammation/apoptosis).

Laser Capture Microdissection of Frozen and Paraffin-Embedded Adult Mouse Lung for RT-PCR Analysis of GAPDH and Bmp-4

© D Faratian¹, D Rannie², F Rae², S McBride², D J Harrison²
¹ Royal Infirmary of Edinburgh, Edinburgh, United Kingdom, ² University of Edinburgh Division of Pathology, Edinburgh, United Kingdom

Bone morphogenetic protein-4 (Bmp-4), a member of the transforming growth factor-beta superfamily, has been extensively studied in the context of developmental pathways including embryonic lung morphogenesis. Inactivating mutations in Bmp-4 cause embryonic lethality, while targeted overexpression in lungs gives rise to an emphysematous phenotype. In addition to its role in branching morphogenesis, Bmp-4 has been implicated in lung injury repair and in the negative regulation of growth in lung adenocarcinoma cells. Bmp-4 has been studied in a few adult tissues, and in tumours, but has not been described in adult bronchiolar epithelium. In this study, we successfully detected expression of Bmp-4 by reverse transcription-polymerase chain reaction (RT-PCR) in laser capture microdissected (LCM) adult mouse lung bronchioles, furthering our understanding of developmental gene expression in health and disease.

In order to test the applicability of LCM to RT-PCR on paraffin embedded tissue, we also analysed expression of GAPDH, a housekeeping gene, in mouse bronchioles dissected from formalin- and methacarn-fixed tissue sections. We successfully amplified mRNA-derived products, suggesting that LCM combined with gene expression analysis is possible on tiny samples derived from archival material.

Expression of the Gli1 transcription factor in normal breast tissue and benign breast lesions.

© JP Bury, YL Stephenson, SS Cross

University of Sheffield, Sheffield, United Kingdom

The hedgehog signalling pathway has been implicated in a variety of developmental and morphogenetic processes, including the formation of skin adnexal structures such as sebaceous glands and hair follicles. The pathway's role in mammary gland development has received much attention. Most studies have focussed on upstream components of the pathway. These have yielded inconclusive results and not defined a clear role for the pathway in the adult breast. Modulation of the activity of members the Gli family of transcription factors serves as the ultimate downstream effector mechanism of hedgehog signalling. We used immunohistochemistry to study the expression and localisation of the Gli1 protein in sections of non-malignant breast tissue. We stained 19 sections of formalin-fixed paraffin-embedded archival breast tissue, from 12 patients, using a polyclonal antibody specific for Gli1 (Ab7523, Abcam, UK). Widespread nuclear staining was observed in epithelial and myoepithelial cells throughout all specimens, both in ducts and terminal duct lobular units. Staining was markedly less prominent in fibroblasts, adipocytes and other non-epithelial elements. Cytoplasmic staining was variably observed, interestingly often in association with mild phenotypic changes such as columnar cell hyperplasia. The expression and nuclear localisation of Gli1 in epithelial elements throughout the breast tissue studied here suggests that active hedgehog signalling may be widespread throughout the adult mammary gland. The cytoplasmic localisation of Gli1 in some phenotypically altered epithelial elements observed here may indicate a role for disturbed hedgehog signalling in the development of some benign proliferative conditions in the breast.

Gli1 Appears To Be Constitutively Expressed In The Luminal Epithelial Cells Of The Prostate But Not In The Basal Cell Layer Or The Mesenchyme

AM Spencer², JP Bury¹, K Feeley², A-R Azzouzi³, FC Hamdy³, © SS Cross¹

¹ Academic Unit of Pathology, School of Medicine & Biomedical Sciences, University of Sheffield, Sheffield, United Kingdom, ² Department of Histopathology, Sheffield Teaching Hospitals NHS Trust, Sheffield, United Kingdom, ³ Academic Urology Unit, School of Medicine & Biomedical Sciences, University of Sheffield, Sheffield, United Kingdom

Gli1 (glioma-associated oncogene homolog 1) is one of the human homologues of the Drosophila Cubitus Interruptus gene. It is a zinc finger transcriptional regulator which is activated by Sonic Hedgehog (SHH) protein binding to the Patched protein and removing its inhibition of Smoothened. Gli1 has been shown to be expressed in the mesenchyme of the murine prostate during the epithelial budding phase of development. SHH has been shown to be involved in the development of the murine prostate and inhibition of SHH, in the presence of testosterone, produces an epithelial hyperplasia with a morphology similar to cribriform prostatic intraepithelial neoplasia (PIN). We performed immunohistochemistry for Gli1 on 22 cases of benign prostatic hyperplasia and 45 samples of morphologically normal prostatic epithelium from radical prostatectomy specimens in tissue microarray format, with triplicate samples of each specimen. In all cases there was strong staining of both the nucleus and cytoplasm of the luminal epithelium in benign prostatic glands but the basal cell layer was not stained, nor was the mesenchyme. This is the first description of Gli1 expression in adult human prostate. The significance of the Gli1 expression in the luminal epithelium requires further investigation. It is possible that constitutive expression is due to continued presence of SHH and this may prevent the PIN-like hyperplasia seen when SHH is inhibited in the mouse. The expression of the Hedgehog and Gli proteins needs to be investigated in prostatic neoplasia.

TSLC1 Is A Tumor Suppressor And Marker For Invasion In Cervical Neoplasia

© RDM Steenbergen¹, D Kramer¹, BJM Braakhuis¹, PL Stern⁴, RHM Verheijen¹, CJLM Meijer¹, PJF Snijders¹
¹ VU Medical Center, Amsterdam, Netherlands, ² VU Medical Center, Amsterdam, Netherlands, ³ VU Medical Center, Amsterdam, Netherlands, ⁴ Paterson Institute, Manchester, United Kingdom, ⁵ VU Medical Center, Amsterdam, Netherlands, ⁶ VU Medical Center, Amsterdam, Netherlands, ⁷ VU Medical Center, Amsterdam, Netherlands

Cervical carcinogenesis is initiated by a high-risk HPV (hr-HPV) infection and the progression through premalignant lesions (CIN) to invasive cancer is driven by additional genetic alterations. Here we studied the role of the tumor suppressor gene TSLC1 (tumor suppressor in lung cancer 1). TSLC1 was found to be silenced in 91% (10/11) of cervical cancer cell lines. Promoter hypermethylation appeared the major mode of TSLC1 silencing. A mechanistic involvement of TSLC1 downregulation was supported by TSLC1's ability to suppress both anchorage independent growth and tumor growth of cervical cancer cells (SiHa). Furthermore, TSLC1 promoter hypermethylation was detected in 58% (30/52) of cervical carcinomas and 35% (7/20) of high-grade CIN lesions, but not in low-grade CIN lesions (n=12) and normal cervix (n=9). Interestingly, TSLC1 promoter hypermethylation could be detected in archival cervical smears of women with cervical cancer taken up to 7 years before cancer diagnosis.

In conclusion, these data show that TSLC1 silencing is an important and highly frequent event in the transition of hr-HPV containing high-grade CIN lesions to invasive cervical cancer. Hence, testing for TSLC1 silencing in cervical smears may provide a powerful tool to identify women having CIN lesions with invasive potential.

Expression Pattern Of DNA Double Strand Break Repair Proteins BRCA1, BRCA2, ATM And RAD51 In Normal Human Tissues

© L Barker¹, M Dattani², D Duncan², S Gray¹, P Quirke², H Grabsch²
¹ Dept of Histopathology, Leeds General Infirmary, Leeds, United Kingdom, ² Academic Unit of Pathology, University of Leeds, Leeds, United Kingdom

All cells are under constant genotoxic stress and have developed DNA repair mechanisms to maintain the integrity of the genome. One of the most detrimental forms of DNA damage is the double-strand break [DSB]. The expression of BRCA1, BRCA2, ATM and RAD51, proteins that play a crucial role in DSB repair, has not been characterised comprehensively in normal human tissues.

We studied BRCA1, BRCA2, ATM and RAD51 by immunohistochemistry on tissue microarrays constructed from 36 different types of normal human tissue. These tissues originated from the gastrointestinal, urinary, and male and female genital tracts, lymphoid system, muscle, nervous system, endocrine organs, skin, breast, placenta, and salivary gland. The distribution of the positively stained cells within the tissue as well as the subcellular localisation of the protein was noted.

BRCA1 and RAD51 were expressed in all tissues. BRCA2 expression was observed in all tissues except prostate. ATM expression was observed in all tissues except liver. Within each tissue, all proteins were expressed in nearly all mesenchymal and epithelial cells with no particular pattern. Subcellular localisation of BRCA1 and ATM was predominantly nuclear, that of BRCA2 and RAD51 predominantly cytoplasmic.

The widespread expression of DSB repair proteins in human tissues is consistent with their vital function in protecting the cell from the consequences of DNA damage. The lack of expression of some of the proteins in liver and prostate is unexpected and warrants further investigation. Our study provides the necessary baseline data with which to compare the expression pattern of these proteins in different diseases.

Cyclooxygenase-2 inhibition decreases colon cancer cell motility through modulating epidermal growth factor receptor transactivation

© N A Banu¹, A Buda¹, S Chell², D Qualtrough², D Elder³, M Moorghen¹, C Paraskeva², M Pignatelli¹
¹ Division of Histopathology, School of Medical Sciences and Bristol Royal Infirmary, Bristol, United Kingdom, ² Department of Pathology & Microbiology, University of Bristol, Bristol, United Kingdom, ³ Department of Biochemistry, School of Medical Sciences, University of Bristol, Bristol, United Kingdom

Overexpression of cyclooxygenase (COX)-2 and increased prostaglandin (PG) levels promote tumour progression in colorectal cancer. PGs have been shown to increase motility through transactivation of the epidermal growth factor receptor (EGFR) *in vitro*.

We investigated the effect of the selective COX-2 inhibitor NS-398 on the migration of colorectal cancer cells and examined whether this effect was associated with changes in EGFR activation. The effect of NS-398 treatment on migration of HT29, HCA7, HCT116 cell lines was studied using a trans-well filter assay. Expression of COX-2 and PGE₂ receptors was assessed by Western blot and RT-PCR respectively. PGE₂ concentrations after NS-398 treatment were estimated by ELISA. EGFR phosphorylation levels were analysed by immunoblotting. Treatment with 5 and 10 µM of NS-398 (24 hours) reduced PGE₂ levels and decreased cell migration in the COX-2 positive cell lines (HT29, HCA7). PGE₂ addition abolished the effect of NS-398 and restored cell motility. COX-2 protein levels were unaltered following NS-398 treatment. NS-398 reduced EGFR phosphorylation and AG1478 treatment reduced PGE₂-stimulated motility of COX-2 positive cells demonstrating that PGE₂ acts via EGFR signalling pathway.

Our results showed that functional inhibition of COX-2 by NS-398 reduces migration of colorectal cancer cells. This effect is associated with a perturbation of the EGFR signalling pathway activated by PGE₂.

High Resolution Analysis Of DNA Copy Number Changes In Malignancies With Chromosome 20q Gains

J. Coffa¹, M.A.JA Hermsen¹, B. Carvalho¹, J.P. Schouten², © G.A. Meijer¹
¹ Department of Pathology, VU University medical center, Amsterdam, Netherlands, ² MRC Holland, Amsterdam, Netherlands

DNA copy number changes at chromosome 20 frequently occur in solid cancers, with a 800kb region at 20q13.2 as the locus for a putative oncogene. In addition, also areas outside 20q13 frequently show gains. Therefore, we tested the presence of DNA copy number changes for multiple genes in a series of malignancies, using multiplex ligation-dependent probe amplification (MLPA). DNA of 43 colorectal cancers, 15 gastric adenocarcinomas, 5 Barrett carcinomas, 6 breast carcinomas, 2 oesophageal squamous cell carcinomas, 1 retinoblastoma and 5 different colon cellines was analysed with a dedicated oligonucleotide probe set for MLPA, containing 28 genes on chromosome 20 and 13 reference genes spread over the genome was designed.

All tumours showed abnormalities on 20q, including gains (ratio>1,3) for more than 80% of all probes in 50% of the cases. Discrete amplifications (ratio >2,5) were found at 20q11 and 20q13.2, and sometimes at 20q13.3.

High resolution copy number analysis of different malignancies with gain of chromosome 20q revealed that approximately 50% of the cases in addition to gain of 20q also have amplification of smaller regions that seem to concentrate around 20q11, 20q13.2 and 20q13.3.

Co-expression of Id2 and HIF-1 α in breast carcinoma

© JP Bury, SS Cross, S Balasubramanian, MW Reed, CE Lewis
University of Sheffield, Sheffield, United Kingdom

Id2 is a member of the basic-Helix-Loop-Helix family of transcription factors and is thought to play a role in regulating the balance between cell proliferation and differentiation. Upregulation of Id2 in response to hypoxia in macrophages has been observed. We sought to establish whether a similar relationship between Id2 expression and hypoxia might operate in breast tumours. A tissue microarray was prepared containing 1mm cores from 200 separate breast tumours. One section from this array was immunostained using a polyclonal antibody against Id2 (sc-489, Santa Cruz, California). Id2 staining was scored as present or absent. A second section was immunostained using a monoclonal antibody to Hypoxia Inducible Factor, HIF-1 α (ab463, Abcam, UK). Nuclear HIF-1 α assessed was using a semi-quantitative scoring system based on the proportion of positively staining nuclei (<10%, 10-50%, 50-90%, >90%). 11 tissue cores were lost after Id staining (12%), 40 after HIF staining (20%); scores for both Id2 and HIF-1 α were thus available for correlation in 160 cases. 19 of 34 tumours (56%) with high levels of nuclear HIF-1 α staining (>90% of nuclei positive) expressed Id2, whereas only 42 of 126 tumours (33%) with lower levels of nuclear HIF-1 α staining were positive for Id2 ($p=0.036$, Mann-Whitney U test). This finding is paradoxical, given that in breast tissue Id2 expression is thought to promote a differentiated, non-aggressive phenotype, whilst hypoxia is associated with the reverse. Nevertheless these data support the hypothesis that hypoxia may induce Id2 expression in breast carcinoma. It is notable that a possible HIF-1 α binding site (GCGTG) is present within the Id2 promoter, and the mechanism of the association between Id2 and HIF-1 α expression warrants further investigation.

Hypoxia Induces Mitoxantrone Resistance not Mediated by MDR Transporters.

© AE Greijer, MC de Jong, GL Scheffer, PJ van Diest, E van der Wall

¹ VUMC, Amsterdam, Netherlands, ² VUMC, Amsterdam, Netherlands, ³ VUMC, Amsterdam, Netherlands, ⁴ UMC, Utrecht, Netherlands, ⁵ UMC, Utrecht, Netherlands

Hypoxic tumors are more resistant to chemo and radiotherapy. Hypoxia-induced resistance to doxorubicin and mitoxantrone was analyzed. Survival of MCF-7 cells cultured in presence doxorubicin was not changed under hypoxia. However, MCF-7 cells were more resistant to mitoxantrone under hypoxia. The IC50 value shifted from 0.09 μ M (+/- 0.01) to 0.54 μ M (+/- 0.06) under hypoxia. Hypoxia-induced resistance to mitoxantrone was also observed in non-small lung cancer cells, SW1573. Leukemia cells, HL60, were tested, but did not survive hypoxia. Decreased sensitivity to mitoxantrone may be caused by a lower intracellular drug concentration under hypoxia. The microenvironment becomes more acid due to anaerobic glycolysis hampering uptake of mitoxantrone and doxorubicin. Influx of mitoxantrone appeared to be 5.3 lower and influx of daunorubicin, a doxorubicin homologue, was 3.2 decreased. Drug efflux due to multidrug resistance transporters under hypoxia was analyzed in the presence and absence of specific inhibitors of MDR transporter. In these assays functionality of MDR transporters, MDR1, and BCRP showed no induction by hypoxia. In addition, protein levels of MDR transporters were not changed. The difference in hypoxia-induced resistance to mitoxantrone and doxorubicin may be explained by the difference in ability of the drug to generate reactive oxygen species under hypoxia

Identification of Hypoxia Responsive Genes Regulated by the Hypoxia Inducible Factor 1 (HIF-1)

© AE Greijer, P van der Groep, D Kemming, A Shvarts, GL Semenza, PJ van Diest, E van der Wall

¹ VUMC, Amsterdam, Netherlands, ² UMC, Utrecht, Netherlands, ³ Westfälische Wilhelms-Universität Münster, Münster, Germany, ⁴ UMC, Utrecht, Netherlands, ⁵ The Johns Hopkins University School of Medicine, Baltimore, United States, ⁶ UMC, Utrecht, Netherlands, ⁷ UMC, Utrecht, Netherlands

The hypoxia inducible factor 1 (HIF-1) plays a critical role in cellular response to hypoxia. For elucidation of biological pathways induced by hypoxia this study analyzed RNA profiles of murine fibroblasts under normoxia and hypoxia using micro array (Affymetrix). Gene regulation by hypoxia is further distinguished between regulation mediated by HIF-1 and HIF-1-independent regulation using fibroblasts derived from HIF-1 α knockout mouse. Results showed upregulation of all glycolytic enzymes in a HIF-1 dependent manner as described before, thereby confirming the reliability of our data. An increase in expression of glucose transporter (GLUT1) was seen. More enzymes involved in metabolic pathways were upregulated by hypoxia, like adenylate kinase 4, galactokinase. However, new hypoxia-regulated genes were identified. Increased expression of genes encoding proteins involved in angiogenesis, apoptosis, and invasion was observed. Genes found to be downregulated by hypoxia were involved in cytoskeleton, cell growth, and DNA repair. Eight new hypoxia regulated genes of which the function is yet unknown, showed to be upregulated and 20 genes appeared to be downregulated. Regulation of most upregulated genes appeared to be mediated by HIF-1. Micro array data of 20 genes have been confirmed by quantitative real-time RT-PCR. Identification of pathways regulated by HIF-1 will contribute to the understanding of biological consequences of hypoxia.

The MRC CR08 (FOCUS) Trial - Assessment Of Multiple Markers For Associations With Response Rate (RR) And Failure-Free Survival (FFS) In Advanced Colorectal Cancer (CRC)

JW Adlard ¹, SD Richman ¹, P Royston ³, JM Allan ², A Meade ³, MKB Parmar ³, P Selby ¹, © P Quirke ², MT Seymour ¹

¹ Cancer Research UK, Leeds, United Kingdom, ² University of Leeds, Leeds, United Kingdom, ³ MRC Clinical Trials Unit, London, United Kingdom

We have assessed pathological markers predictive of prognosis, or treatment response, in advanced CRC patients treated in a large randomised trial of 5-fluorouracil (FU) alone or with oxaliplatin or irinotecan.

Preserved material from 846 patients was collected for analysis. Normal and tumour DNA were extracted and tissue microarrays made for immunohistochemistry. The following factors were assessed for their effect on FFS and RR to first-line therapy: age; performance status; primary site; liver metastases; ALP; grade; mucoid status; immunohistochemistry for hMLH1, hMSH2, P53, SMAD4, dUTPase, DPD, thymidine phosphorylase, thymidylate synthase (TS); DNA polymorphisms in TS, hMLH1, MTHFR.

We found statistically significant differences in RR for mucoid status and TS and dUTPase immunohistochemistry. DNA polymorphisms showed no significant association with outcomes. Marker status associations with FFS and RR were similar for patients treated with FU alone or FU+oxaliplatin/irinotecan. Logistic regression was used to generate an algorithm separating patients into groups with RRs ranging from 15% to 50% for treatment with FU alone, and from 25% to 70% with combination chemotherapy.

In conclusion, significant associations with RR were identified for several markers, allowing development of a predictive algorithm. Associations with FFS were also identified. Ongoing work is aiming to confirm these findings and identify markers specific for oxaliplatin or irinotecan benefit.

Wnt Expression In Colonic Subepithelial Myofibroblasts

© S Bamba¹, WR Otto¹, M Brittan¹, SL Preston¹, S Ahmed², PJ Pollard¹, NA Wright¹

¹ Cancer Research UK, London, United Kingdom, ² Barts and The London Hospital, London, United Kingdom

BACKGROUND: Colonic subepithelial myofibroblasts (SEMFs) are present immediately beneath the epithelial cells, and speculation is rife that these maintain the stem cell niche. In this study we show that SEMFs are the source of Wnt signalling in the colon.

METHOD: Colonic SEMFs and colonic crypts were isolated from C57/BL and IL-10 knockout mice (which develop colitis spontaneously) using EDTA, and mRNA expression of Wnt and its receptor Frizzled (Fzd) was studied using RT-PCR. To evaluate the regulation of Wnt mRNA, EGF was used to stimulate SEMFs.

RESULTS: RT-PCR studies revealed (i) 10 out of 19 Wnt mRNAs were expressed in SEMFs from C57/BL mice and IL-10 knockout mice; (ii) Wnt mRNA expression was observed mainly in colonic SEMFs, on the other hand the expression of Fzd mRNA was observed in both colonic SEMFs and crypt epithelium. (iii) IL-10 knockout mice-derived SEMFs tended to express more Wnt mRNA than C57/BL-derived SEMFs. (iv) EGF specifically upregulated Wnt2 mRNA expression.

CONCLUSION: The source of Wnt signalling in the colon is predominantly from the colonic SEMFs, consistent with a role for these cells in the maintenance of the stem cell niche. Fzd mRNA expression in SEMFs suggests that Wnt proteins secreted from SEMFs can act not only in a paracrine manner but also in an autocrine manner. IL-10 knockout mice-derived SEMFs displayed different Wnt mRNA expression patterns from C57/BL-derived mice, implying immature characteristics of SEMFs in inflammation.

Molecular interactions between E-cadherin and α 2b1 integrins in epithelial cells.

© N Ockendon, A Buda, M Pignatelli

Department of Pathology and Microbiology, University of Bristol, Bristol, United Kingdom

E-cadherin is a transmembrane glycoprotein, which mediates epithelial cell-cell adhesion. Its adhesive function requires association with β -catenin and α -catenin linking to the actin cytoskeleton. Integrins are transmembrane glycoproteins that bind extracellular matrix (ECM). Both integrins and E-cadherin are localised at the cell-cell junctions.

The aim of this study was to investigate the sub-cellular distribution of E-cadherin-catenin complex and β_1 integrin in oesophageal and colonic cancer derived cell lines and their physical and/or functional interactions.

Two colonic carcinoma cell lines (HT29 and LS174T) and two oesophageal carcinoma cell lines (KYSE30 and OE33) were employed. Protein expression was assessed by Western blotting (WB). Sub-cellular distribution was illustrated by immuno-fluorescence followed by confocal microscopy (IF). Molecular interaction was investigated by sequential co-immunoprecipitation (IP) and WB. Cytoskeletal protein association was detected by extraction of Triton X-100 soluble vs. insoluble cellular fractions.

Indirect IF showed E-cadherin and β_1 integrin co-localising with F-actin at cell peripheries in HT29, KYSE30, and OE33 cells. KYSE30 and OE33 also showed cytoplasmic localisation. Co-immunoprecipitation experiments identified a truncated form of β_1 integrin associated with E-cadherin. Extraction of Triton X-100 soluble vs. insoluble sub-cellular fractions.

In conclusion, E-cadherin and integrins are both localised at the cell-cell junctions but only E-cadherin appears to be associated with the actin cytoskeleton. Further functional studies will need to elucidate the biological significance of this novel association.

Expression of osteoprotegerin (OPG) and TRAIL in oesophageal carcinoma and non-neoplastic gastric and oesophageal mucosa

© A Spencer, SS Cross, I Holen, R Ackroyd, CJ Stoddard, JP Bury

University of Sheffield, Sheffield, United Kingdom

Osteoprotegerin (OPG) is a member of the Tumour Necrosis Factor (TNF) superfamily, and acts a soluble decoy receptor for the Receptor Activator of Nuclear Factor- κ B Ligand (RANKL) and TNF-related apoptosis-inducing ligand (TRAIL). OPG inhibits the differentiation of osteoclast precursors, and has been widely studied within the context of bone metastasis, particularly in breast and prostate cancers. OPG expression has also been demonstrated in gastric carcinomas, and has been shown to correlate with poor survival. We studied the expression of OPG and TRAIL in oesophageal carcinomas and surrounding normal gastric and oesophageal mucosa. We mounted 1mm cores from carcinomas and from background oesophageal and gastric mucosa in a tissue microarray and performed immunohistochemistry for OPG and TRAIL. OPG was expressed in 11 of the 20 tumours studied (55%). TRAIL was expressed in 12 of 19 tumours studied (63%; cores from one tumour were not retained on the array). No consistent pattern of co-expression or inverse expression of OPG and TRAIL was discernible within tumour tissue. Neither OPG nor TRAIL was detected in normal oesophageal mucosa. We observed OPG staining in normal background gastric mucosa, which was markedly more prominent in oxyntic cells. TRAIL staining was also positive in background gastric mucosa, and interestingly was markedly less prominent in oxyntic cells. At least one previous study has demonstrated OPG in gastric carcinomas whilst failing to do so in normal gastric epithelium, using an antibody to the N-terminal region of the protein. This study used an antibody to the C-terminal region of the protein, raising the possibility that OPG in gastric mucosa exists in an altered form to that found in gastric carcinomas.

A PROTECTIVE ROLE FOR THE P50-SUBUNIT OF NF κ B IN THE AGING LIVER

© NS Mungalsingh, F Oakley, DA Mann, J Mann, H Millward-Sadler

¹ Liver Group, University of Southampton, Level D, South Academic Block, Southampton General Hospital, Tremona Road SO16 6YD, Southampton, United Kingdom, ² Department of Pathology, Level D, South Block, Southampton General Hospital, Tremona Road SO16 6YD, Southampton, United Kingdom

NF κ B (p50:p65 dimer) regulates the expression of multiple inflammatory genes. Targeted disruption of NF κ B components has revealed critical roles. For example, knockout of p50 results in susceptibility to infection. There are reports of tissue-specific changes in NF κ B activity as humans and animals age, however to date there is no clear evidence that NF κ B plays a definitive role in age-related diseases.

Hypothesis – the p50 subunit of NF κ B protective against inflammation in aged mouse livers.

Aims – To examine aged livers of wild type (WT) and p50-knockout mice for histological evidence of inflammation.

Methods – W.T. and p50-knockout mice were aged for 1 year in SPF conditions. Livers were removed and processed for haematoxylin and eosin and neutrophil staining. Slides were randomised and analysed double-blinded with a consultant histopathologist. The livers of the p50-knockouts were also compared with those of 12 week old W.T. mice.

Results – 12 week old mouse livers showed no inflammatory change from normal. Livers of 5 of the 6 aged W.T. mice displayed no significant inflammatory change. 4 out of the 5 p50-knockouts displayed significant inflammatory changes (2 severe, 2 mild).

Conclusion – Loss of the p50 subunit of NF κ B is likely to be associated with age-related inflammation of the liver.

In-Situ Hybridization Identification of the Y-Chromosome as a Tool to Characterize a Graft Versus Host (GvH) Model in the Rat

© GM Elliott, E Holness, KC Hickling, RV Bundick, PJ Kerry
AstraZeneca R&D Charnwood, Loughborough, United Kingdom

The GvH model of injecting DA rat lymphocytes into the footpad of DA/Lewis F1 rats is used to investigate efficacy of immunomodulating xenobiotics, often using popliteal lymph node weight as the experimental endpoint. The relative contribution of donor/host cells is poorly understood and the Y-chromosome is one way of investigating the contribution of (male) donor cells to (female) recipient lymph node expansion. Techniques to demonstrate Y-chromosomes in the mouse are available but problematical in rat.

In situ hybridization on formalin-fixed sections of lymph node from male and female control rats and from female rats 7 days post-injection with male donor cells was carried out to identify Y-chromosomes using a Cy3 labelled probe (Cambio CA-1631).

Cells containing Y-chromosomes were evenly distributed throughout control male lymph nodes and were absent in female nodes. Male donor cells (lymphocytes and blastoid) were found evenly distributed or in clusters throughout female recipient lymph nodes. Alleles of another chromosome (Chromosome 12) were present in cells from all nodes but were clearly distinguishable from Y-chromosomes. This method shows promise in aiding mechanistic understanding of the mode of action of novel immunomodulating agents. Additional work is required to investigate the time course and phenotype of donor cell participation.

Software Development for Processing and Analysis of Histopathologic Images

PM Pavlopoulos², © N Kavantzis¹, P Korkolopoulou¹, S Bouzoukas², E Patsouris¹

¹ *Department of Pathology School of Medicine National and Kapodistrian University of Athens, Athens, Greece,* ² *Urologic Clinic 1st Social Security Hospital of Athens, Athens, Greece*

Aim: Development of an easy to use and adaptable image processing and analysis PC software program for Windows operating system.

Material and Methods: The application was developed in Visual Basic 6.0 (SP5) (Microsoft Corp.) environment. For user friendliness the program was designed with multiple document interface and Windows XP compatibility. **Results:** The application can open and edit the most common file types (*.bmp, *.jpg, *.gif). It has basic functions such as reversal or posterization of the images and it can apply mathematical operations as well as brightness, contrast and color balance adjustments. Object segmentation can be performed in 8-bit black and white as well as in 24-bit color images with the use of thresholding adjustable in multiple ways. The application can apply several algorithms for edge detection, such as Roberts Cross, Sobel and Canny edge detectors. The basic operators of the Mathematical Morphology "dilation", "erosion", "opening", "closing" and "hit-and-miss transform" can be performed in binary images. Finally the program permits manual or automatic object counting and measurement of distances, angles or areas.

Conclusion: As it has been observed in thorough testing, this application constitutes a stable, fast, reliable and easy to use tool for image processing and analysis. Moreover, its open architecture permits the continuing upgrading and improving with the addition of newer algorithms customized according to the clinical or researching demands of the user.

TmaDB: A Tissue Microarray Database

© A Sharma-Oates¹, P Quirke¹, D R Westhead²

¹ *Academic Unit of Pathology, University of Leeds, Leeds, United Kingdom,* ² *School of Biochemistry and Microbiology, University of Leeds, Leeds, United Kingdom*

A single tissue microarray (TMA) experiment can generate a vast quantity of data, as a consequence a systematic approach is required for the storage and analysis of such data.

To facilitate such analyses a relational database (known as TmaDB) has been developed to archive numerous aspects of TMA data including experimental design, experimental protocol, results from the various immunocytological and histochemical staining experiments including the scanned images for each of the TMA cores. Other aspects of the data stored in the database include pathology reports associated with each specimen on the TMA slide, location of the various TMAs and the individual specimen blocks (from which cores were taken) in the laboratory and their current status i.e. if they can be sectioned into further slides or if they are exhausted. The database that has been designed incorporates most of the published common data elements for TMA experiments. TmaDB is therefore compatible with the TMA data exchange specification developed by the Association of Pathology Informatics community.

Furthermore, TMA experiments from several types of cancer can be stored in a single database. TmaDB will provide a comprehensive repository for TMA data such that a large number of results from the numerous immunostaining experiments can be compared for each of the TMA cores in a simple way by tiling each of the images with a description of the result. This will allow a systematic, large-scale comparison of tumour samples to facilitate the identification of gene products of clinical importance such as therapeutic or prognostic markers. Finally, the ultimate goal of this work to establish a standard for reporting TMA data that is equivalent to MIAME for microarray data.

Microarrays for dummies

© B Ylstra, P van den ijssel

VU University Medical Center, Amsterdam, Netherlands

Modern day technique has enabled tens of thousands of genes to be printed on a single microscope slide: high-density microarrays. The development of these arrays has boosted genomics research, exploiting the huge amount of data made available by the human genome project, as all known genes could now be included. Complete RNA expression profiles can be acquired, which can be clustered and related to disease status. From these clusters a molecular profile or 'signature' of the disease can be extracted. Thus, research can take full advantage of developments in microarray technique to find diagnostic and prognostic profiles for various diseases. A major challenge is to implement these signatures as diagnostic or prognostic tools in the clinic.

Despite the availability of a number of commercial platforms, many institutes have raised core facilities providing them with homemade microarrays to minimize cost and maximize flexibility. Since all these facilities use their own combination of probes, slides, printing and scanning equipment, hybridization conditions and sample preparation, this gives rise to a huge variability in quality. Because regulatory federal and state agencies will allow only excellent quality microarrays to be used for diagnostics, many of today's platforms will not pass.

Many statistical 'tricks' are being applied to correct for artifacts in the result of microarray experiments. In this seminar we will introduce the basics of the technique and implementation. We will pinpoint essential steps to raise the quality of microarrays produced in core facilities to the perfection required for diagnostics or prognostics.

Microarray Based Comparative Genomic Hybridization For Genomic Profiling In Pathology

© GA Meijer

VU University Medical Centre, Amsterdam, Netherlands

Histological grading and typing for classifying tumor samples into clinically meaningful categories is one of main tasks in diagnostic pathology. For a long time this was mainly based on H&E stainings, later supplemented with immunohistochemistry and recently extended with genomic profiling at the DNA, mRNA or protein level. DNA based profiling is attractive because DNA is easy to handle in a routine pathology setting, it can be isolated from archival material, and data interpretation is rather straight forward. The state of the art tool for obtaining DNA based genome wide tumour profiles is microarray based comparative genomic hybridization, a technique that especially the last year has become more widely available.

Applications in pathology include identification of new oncogenes and tumor suppressor genes, discovery of new tumour classes and correlation to clinical outcome, including response to therapy. Such studies will provide classification rules that can be used to assign individual samples into the appropriate diagnostic category. Other applications include genomic comparison of multiple tumours within one patient as well as assessment of chromosomal aberrations in perinatal pathology and clinical genetics.

New developments include full genome covering arrays, oligonucleotide based platforms and PCR based approaches like multiplex ligation-dependent probe amplification

Evidence based dataset reporting for melanoma.

© AT Evans

Ninewells Hospital and Medical School, Dundee, United Kingdom

Dataset reporting is now well established for common malignancies such as breast and colorectal carcinoma but it has been slow to become established for cutaneous melanoma. In 2001 SIGN (The Scottish Intercollegiate Guidelines Network) formed a working party to examine the care pathway for patient's with melanoma in Scotland. Recognising that the pathology report is central to deciding treatment and follow-up the aim of the pathology subgroup was to foster a high standard of pathology reporting at a national level and also to ensure that the clinician was provided with prognostically valid information.

A broad spectrum of histopathological variables was studied using established SIGN methodology. The quality of the evidence base was scored and a grade of recommendation derived for each variable. After examination of the available published evidence the variables considered essential for inclusion in the surgical report were as follows; Breslow thickness, Clark level (for lesions <1mm), ulceration, growth phase characteristics, regression, lymphovascular space invasion, microscopic satellites and surgical clearance (measured in mm). The impact on dataset reporting by recent changes in melanoma staging (recommended by the AJCC) will be discussed and some thought will be given to how dataset reporting might evolve in the future.

It is planned that the members of the Scottish Melanoma Group will adopt dataset reporting and it is anticipated introduction on a national basis in Scotland will be from January 2005.

Tumour–Stroma Interactions In Melanoma

© LCLT van Kempen, J Rijntjes, GNP van Muijen, DJ Ruiters
University Medical Centre, Dept. of Pathology, Nijmegen, Netherlands

Solid tumors are complex mixtures of neoplastic and non-neoplastic cells, matrix proteins and soluble polypeptide growth factors. Neoplastic progression of solid tumours is often characterized by an increased architectural disorder at the invasive front, which results from a simultaneous increase in matrix synthesis (e.g. type I collagen) by stromal cells and degradation by proteolytic enzymes (e.g. matrix metalloproteinases). Type I collagen remodelling attenuates apoptotic stimuli emerging from intact collagen, alters the bioavailability of collagen-binding polypeptide growth factors, is a prerequisite for angiogenesis, and enables expansive and invasive growth. However, with the exception of desmoplastic melanoma, invasive human cutaneous melanoma appears devoid of a strong stromal reaction. Type I collagen mRNA in situ hybridization revealed increased synthesis by stromal cells juxtaposed to non-invasive melanoma cell nests. In contrast, synthesis was not observed in stromal cells adjacent to the invasive tumour component. This part of the tumor also displayed pericellular proteolysis of the extracellular matrix as a result of proteinase synthesis by tumour and stromal cells. In combination with altered type I collagen synthesis by stromal cells, this further modulates the tumour microenvironment. Fibroblasts are the predominant source of type I collagen in skin. *In vitro*, only metastatic human melanoma cell lines inhibit type I collagen synthesis by primary dermal fibroblast. These data indicate that type I collagen synthesis in melanoma may be a host defence mechanism towards the neoplasm but that melanoma cell-mediated inhibition of type I collagen synthesis enables the transition from micro-invasive to deeply invasive melanomas with metastatic capacities.

p16 and Cell Senescence: a Barrier to Melanoma Initiation?

© DC Bennett¹, VC Gray-Schopfer¹, SC Cheong¹, A MacKenzie Ross¹, H Chong¹, J Chow¹, T Moss², D Wynford-Thomas³

¹ St George's Hospital Medical School, London, United Kingdom, ² St George's Hospital, London, United Kingdom, ³ University of Wales College of Medicine, Cardiff, United Kingdom

The best-known gene for melanoma susceptibility is CDKN2A, mutated in around 15-60% of melanoma families, in different populations. This locus encodes two proteins; the one usually mutated in melanoma families is p16. p16 is not expressed in most normal cells, but is an effector of cell senescence - the irreversible arrest of division after a finite number of mitoses, seen in normal somatic cells and proposed to be a barrier to cancer. Cell senescence was delayed in melanocytes cultured from two patients lacking normal p16; the cells divided many more times than normal melanocytes. Gene transfer studies indicated that human melanocytes require both a deficiency in the p16/RB1 pathway and activation of telomerase, to overcome senescence and become immortal (divide indefinitely). We developed a genetic model in which a naevus is a clone of melanocytes that proliferates following a first mutation, then undergoes p16-dependent senescence. Cell immortalization would be required for melanoma development. We have tested this model by immunostaining naevi, dysplastic naevi and melanomas for p16 and other markers of senescence. The data so far support the model: naevi express cell-senescence markers that are absent from normal melanocytes and are largely lost during melanoma progression.

N or M? How to handle diagnostic uncertainties

© WJ Mooi

Vrije University Medical Center, Amsterdam, Netherlands

The differential diagnosis of cutaneous melanocytic lesions largely concerns the distinction between naevus and melanoma. A plethora of histological variants of naevus and melanoma have been characterized, each with a unique set of distinguishing features. Vexingly, these various features do not add up to a generally applicable set of criteria to distinguish between all naevi and all melanomas. For instance, presence of a few deep mitotic figures would be an argument for malignancy in the distinction between Spitz naevus and 'Spitzoid' melanoma, but is diagnostically meaningless if the lesion is a blue naevus variant. Accordingly, one has to decide whether a given lesion is in the 'Spitz' or in the 'blue' category before one can decide whether deep mitotic activity is diagnostically relevant. This is not always straightforward and is at times impossible.

Melanocytic naevi exhibiting unexpected combinations of histological features are less rare than textbooks would suggest. This significant problem illustrates that further work is needed in this field. From a practical viewpoint, I feel that it is preferable to admit diagnostic uncertainty to the clinician than to produce an unequivocal diagnosis that is in fact no more than one's best guess. Clinical treatment planning is generally quite feasible on the basis of a preferred rather than an unequivocal histological diagnosis.

Clinical aspects of salivary gland tumours

© I van der Waal

Vrije University Medical Centre, Amsterdam, Netherlands

Salivary gland tumours consist predominantly of epithelial tumours. The estimated annual incidence is 2:100,000 population, which includes benign and malignant types. There is no gender preference. Salivary gland tumours may occur at all ages. The etiopathogenesis is largely unknown.

The majority of salivary gland tumours is located in the parotid glands; involvement of the submandibular glands and the intraoral accessory glands is, indeed, rather rare, while the sublingual gland is rarely affected at all. There is an increasing malignancy percentage for tumours arising in the parotid gland (20%), the submandibular gland (25%), the intraoral accessory gland (50%), while tumours in the sublingual glands are almost always malignant.

Salivary gland tumours are usually slow growing. Absence of pain and an intact facial nerve in tumours of the parotid gland do not rule out malignancy. The main clinical differential diagnosis of tumours of the major salivary glands relates to lymph node pathology. In the preoperative diagnostic work up fine needle aspiration cytology is commonly used in tumours of the parotid and the submandibular gland, while in intraoral tumours usually preference is given to an incisional biopsy. Additional imaging may provide valuable information, particularly in deep lobe tumours of the parotid gland.

For histopathologic typing the World Health Organization Histopathological Classification is most commonly used. Treatment of salivary gland tumours primarily consists of surgical removal. Postoperative irradiation is only administered in selected cases. Prognosis mainly depends on stage and histological type.

The New WHO Classification of Salivary Gland Tumours

© JW Eveson

Bristol University, Bristol, United Kingdom

The new WHO classification of salivary gland tumours is based on a consensus conference held in Lyon in July 2003. The major changes include: classifying cribriform adenocarcinoma of the tongue as a variant of polymorphous low-grade adenocarcinoma.

including clear cell carcinoma (NOS) as an entity. Hyalinising clear cell carcinoma is included within the spectrum of this tumour.

renaming low-grade salivary duct carcinoma as a low-grade cribriform cystadenocarcinoma and including it as a variant of cystadenocarcinoma.

rationalising the terminology of carcinomas in pleomorphic adenoma. This includes dropping the term malignant mixed tumour and dividing the previous subtypes into carcinoma ex PA (non-invasive, minimally invasive and invasive), carcinosarcoma and metastasizing pleomorphic adenoma. undifferentiated carcinomas are divided into small cell, large cell and lymphoepithelial carcinomas.

sialoblastoma is included in the malignant group.

there are only minor alterations in the adenomas in the sebaceous adenoma/lymphadenoma group.

in the soft tissue group there is only a brief overview in the text referring the readers to other chapters where entities are covered in more depth as appropriate.

apart from extra-nodal marginal zone B-cell lymphoma of salivary glands the haematolymphoid tumours are only briefly mentioned

Fine needle aspiration of salivary gland lesions

© E Bloemena

Dept of Maxillofacial Surgery/Oral Pathology ACTA VU University medical centre, Amsterdam, Netherlands

Fine needle aspiration cytology (FNAC) is a relatively simple, safe, fast, and inexpensive method for investigation of circumscribed lesions. Palpable lesions can be reached by manual palpation, other lesions can be biopsied under ultrasound guidance. FNAC of salivary gland lesions has already been applied for many years. The most important goal of FNAC of lesions in the regions of the salivary glands is to differentiate between primary processes of the salivary gland itself or processes outside the gland, e.g. lymph nodes. Moreover, within the pathology of the salivary gland, FNAC is useful for discrimination between inflammatory processes and neoplasms. According to literature, specificity of FNAC of salivary gland masses reaches 86-100% with a sensitivity of 70-98% (reviewed in CJR Stewart *et al.*, *Diagn Cytopathol* 2000, 22:139).

Cytological criteria for inflammatory processes and the most prevalent salivary gland tumours have been established. Examples of the most common tumours will be demonstrated and diagnostic problems will be discussed.

IMMUNOHISTOCHEMISTRY (IHC) ON BONE MARROW BIOPSIES

How often and what?

© P van der Valk

dept. of pathology VUMC, Amsterdam, Netherlands

Possibilities for IHC to aid in identifying cell types has improved markedly with the advent of new cell markers that work in decalcified and embedded material and this is an update on the progress.

Cell typing. Difficult areas in bone marrow histology are: distinction between some cell types, assigning lineage to blasts, or identifying cells distributed diffusely through the bone marrow (plasma cells, hairy cells). For this, a small panel of antibodies is useful, including glycophorin A, CD61, CD138 and kappa/lambda light chains, myeloperoxidase (MPO), CD45

Typing (acute) Leukemia. The most important distinction is between lymphoblastic and myeloid leukemias. Subdividing myeloid leukemias remains a difficult area. Distinction between acute lymphoblastic leukaemia (ALL) and acute myeloid leukaemia (AML) is now almost always possible.

Subtyping lymphoma. Subtyping lymphoma in bone marrow biopsies is no different from analysis in other organs, for instance the lymph node. All antibodies used there, for T- and B-cells and their subsets, work in trephines, though some can be difficult.

Additional entities. For histiocytic, metastatic and infectious disorders (Parvo) IHC can also be very useful.

Given the inherent difficulties in bone marrow pathology **routine** use of IHC cannot be too strongly recommended.

Cancer as an Epigenetic Disease: Alterations in DNA Methylation and Chromatin

© M Esteller

Cancer Epigenetics Laboratory, Spanish National Cancer Centre, Madrid, Spain

We are in an era where the potential exists for deriving comprehensive profiles of DNA alterations characterizing each form of human disease, specially cancer. DNA methylation is the main epigenetic modification in humans. Tumor cells show aberrant methylation of several CpG islands, but global demethylation versus the counterpart normal cells. Our results show that CpG island promoter hypermethylation has a tumor-type specific pattern. Epigenetic silencing affects all cellular pathways: from DNA repair (hMLH1, MGMT, BRCA1) to cell cycle (p16^{INK4a}, p14^{ARF}, p15^{INK4b}, p73). Promoter hypermethylation of particular genes have important consequences for the biology of that particular tumor. This is for example the case of the DNA repair gene MGMT which methylation-mediated silencing leads to transition mutations, but, at the same time, "marks" chemosensitivity. Those genes inactivated by epigenetic mechanisms are not only silenced and hypermethylated in sporadic cases, but also hypermethylation can be observed in hereditary tumors as a "second hit". It is also widely accepted that methyl-CpG binding proteins (MBDs) couple DNA methylation to gene silencing through the recruitment of histone deacetylase and chromatin remodelling activities that modify chromatin structure. Chromatin Immunoprecipitation (ChIP) assays demonstrate how the vast majority of tumor suppressor genes with CpG island promoter hypermethylation-associated inactivation also present histone hypoacetylation and histone methylation. Overall, our data demonstrates that human tumors suffer a profound, but specific, disturbance in their DNA methylation and chromatin patterns. Further research is required to understand the epigenetics of cancer.

Secondary Myelodysplasia

© K Henry

Imperial College, Charing Cross Hospital, London, United Kingdom

Secondary myelodysplasia, meaning abnormalities in maturation of the 3 bone marrow (BM) myeloid lineages and in no way implying a myelodysplastic syndrome, can result from a number of unrelated conditions. BM trephine biopsy is important in its diagnosis as it allows more precise assessment of stromal changes, overall cellularity and megakaryocyte (Mgk) morphology. Well recognised causes of dyshaematopoiesis are: nutritional deficiencies (B12, pyridoxine and iron); the anaemias of chronic diseases; certain therapies (t-myelodysplasia) and drugs; kidney, liver and thyroid diseases with cytopaenias or altered metabolism; alcoholism; non-haematological malignancies; infections, mainly viral and most notably HIV infection.

A less well recognised cause of marrow dysplasia is the effect of lymphomatous infiltrates on haematopoiesis before therapy. Of the lymphomas, hairy cell leukaemia (HCL) is the best documented. Myelodysplasia on presentation of the disease is also seen in other low grade B cell malignancies such as multiple myeloma, lympho-plasmacytic lymphoma and B CLL/SLL, in Hodgkin lymphoma and T cell lymphoma. The myelodysplasia can effect one or more lineages.

The mechanisms as to how the dysplasia occurs are not completely understood. In HIV infection, various proposals suggested have included immune mechanisms and damage to BM stem cells, macrophages and MgK by direct infection of by the virus. In lymphoma-related myelodysplasia, cytokine production by lymphoma cells and /or altered function of stromal and stem cells is proposed.

The causes and features of 2nd myelodysplasia are illustrated and the mechanisms for their development discussed.